

Two decades of recurrent granuloma, due to foreign body in the scalp, mimicking bone tumor

Adel Khelifa¹, Muneer Mufadhhal Al-Zekri²

¹Neurosurgeon, Departement of Surgery, EPH Achour Ziane, Ouled Djellal, Algeria, ²Surgeon, Departement of Surgery, Ibn Sina Specialist Hospital, Sanaa, Yemen

Foreign bodies (FBs) in the scalp are a common incident following head trauma, especially in traffic accidents, and are detected in the early post-traumatic period. The persistence of these FBs may cause pain and paresthesia.

We report a case of 41 years old man, whose victim it's been 20 years of physical aggression, in which the victim was hit by a brick occasioning a frontal wound stitched at the time without sufficient exploration. Months later, the patient presented several episodes of a frontal scalp nodular lesion with pus leakage (Fig. 1). The lesions were only treated with local antibacterial agents. Four years before the patient consults at our level, he consulted a dermatologist who performed a removal of the skin lesion. Months later, the lesion reappeared. At our level the clinical examination suspected a bone lesion, so CT was performed. Brain imaging was strongly evoking bone tumors or osteitis (Fig. 2). The patient was operated on under general anesthesia. First, a carcinogenic removal of the scalp lesion was performed; then, when reaching the bone, hard red friable bodies well separated from proportionally healthy bone were found. Those findings raise suspicion of the presence of FBs nested in the bone from the first head trauma. Hence, a carcinologic removal of the affected bone was postponed, and simple curettage was performed (Fig. 3). The post-operative course was without complications. The histological study confirmed per-operative findings: Multiple stony FBs associated with inflammatory reaction especially lymphocytes around vessels and the FBs.

Retained FBs after head trauma are common and the diagnosis is made in the emergency room which could be challenging and time-consuming. Wood glass and metal are the most objects retained after a traumatism; rocks are less communally encountered [1]. Most times FBs are found by visual inspection or palpation; otherwise, the diagnosis is made by imaging; generally by plane radiography; in some times, CT is needed to look for small undetected FBs. Unfortunately in one-quarter of cases, radiographs miss the diagnosis. Radiological sensitivity

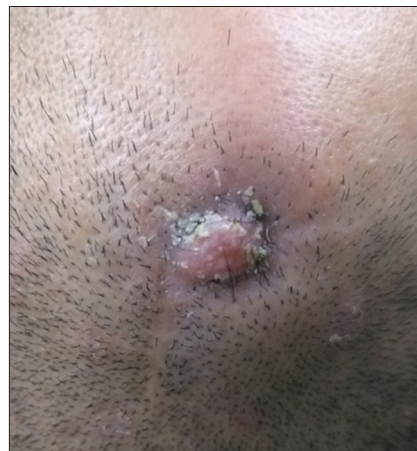


Figure 1: Aspect of the scalp lesion at admission

for FBs is around 98.6% for metal 75.5% for glass, and only 7.4% for wood [1]. Missed FBs are among the top three causes of litigation [1]. Retained FBs could cause toxic and allergic reactions, inflammation, or infection. The presence of FBs launches an infinite inflammatory process that will not subside until the FB is solubilized or at least contained and isolated in a fibrous capsule; leading to a break in local reaction. A minor trauma could rupture the capsule, and so set off the inflammatory process again [2]. Infections or chronic pain and dysesthesia are the most clinical presentations. Those signs are usually located on the site of a cutaneous defect or subcutaneous mass, misdiagnosed as skin neoplasm. Since we encountered in our experience many serious affections with the only presentation of subcutaneous mass [3] we think that removing such lesions without reliable imaging is risky. Another particularity of our case is the bone involvement; in fact, the rock filled the bone defect in such a shape that evokes strongly a bone tumor. Without extemporaneous histopathological examination, we think that conserving the integrity of macroscopic healthy tissue and postponing carcinological removal is judicious since per-operative evidence is in favor of non-malignant lesions.

Correspondence to: Khelifa Adel, Departement of Surgery, EPH Achour Ziane, Ouled Djellal, Algeria. E-mail: drkhelifaadel@gmail.com

© 2023 Creative Commons Attribution-NonCommercial 4.0 International License (CC BY-NC-ND 4.0).

Access this article online	
Received - 06 December 2022	Quick Response code 
Initial Review - 10 December 2022	
Accepted - 02 January 2023	
DOI: 10.32677/yjm.v2i1.3758	

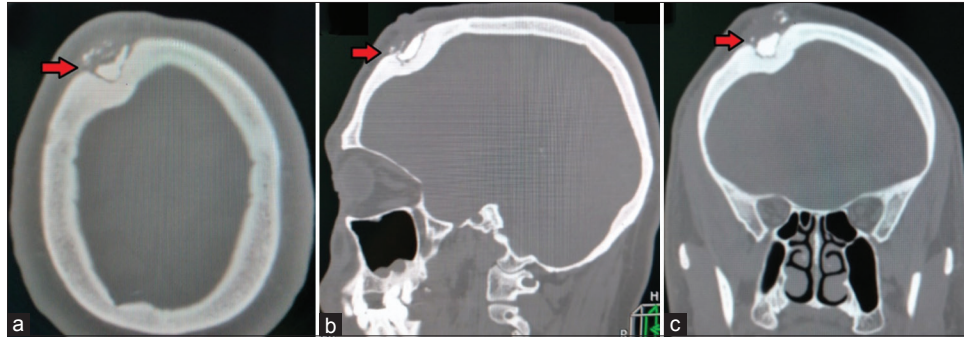


Figure 2: Pre-operative brain CT in the bone window; (a) axial slide, (b) sagittal, and (c) coronal. The arrow points to the location of the foreign body nested in a bone defect

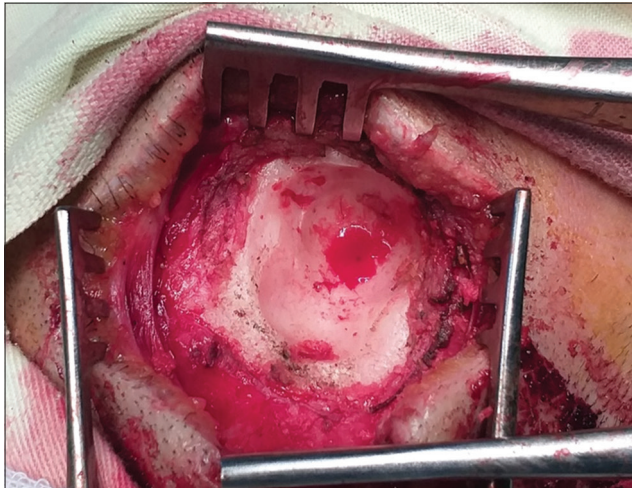


Figure 3: Per-operative photo showing the final aspect of lesion site with removal of cutaneous granuloma and conserving bone integrity (inner table +++)

To sum up, the persistence of foreign scalp bodies could be the cause of infinite medical consultations and so enormous physical and psychological suffering for the patient. Evoking the presence of FBs is paramount in every case of open-head trauma. Finally, scalp lesions are never removed without imaging proof of non-invasion of the bone.

CONSENT FOR PUBLICATION

Written informed consent was obtained from the patient for publication of this case report and all accompanying images. The patient understands that while every effort is made to maintain the confidentiality of their identity, names, and initials, anonymity cannot be guaranteed.

AUTHORS' CONTRIBUTIONS

All authors contributed to the completion of this work. The final manuscript was read and approved by all authors.

REFERENCES

1. Levine MR, Gorman SM, Young CF, *et al.* Clinical characteristics and management of wound foreign bodies in the ED. *Am J Emerg Med* 2008;26:918-22.
2. Lammers RL. Soft tissue foreign bodies. *Ann Emerg Med* 1988;17:1336-47.
3. Khelifa A, Assoumane I, Bachir S, *et al.* Skull metastasis of hepatocellular carcinoma in normal liver: Case report. *Rom Neurosurg* 2019;33:478-81.

Funding: None; Conflicts of Interest: None Stated.

How to cite this article: Khelifa A, Al-Zekri MM. Two decades of recurrent granuloma, due to foreign body in the scalp, mimicking bone tumor. *Yemen J Med.* 2023;2(1):60-61.