

## CASE REPORT

# Salvaging of Hopeless Tooth by an Interdisciplinary Approach

<sup>1</sup>Priyanka Chopra, <sup>2</sup>Anjali Gupta, <sup>3</sup>Ram Tiwari

## ABSTRACT

Hemisection means removal of one root with accompanying crown portion of decayed mandibular molar. Hemisection saves the tooth instead of extraction. This article is about 15 years old boy with deep furcation involvement of mandibular molar treated by hemisection procedure.

**Keywords:** Furcation, Hemisection, Mandibular molar.

**How to cite this article:** Chopra P, Gupta A, Tiwari R. Salvaging of Hopeless Tooth by an Interdisciplinary Approach. *J Orofac Res* 2015;5(4):155-159.

**Source of support:** Nil

**Conflict of interest:** None

## INTRODUCTION

Hemisection is defined as the removal of half a tooth by sectioning the tooth and removing the diseased root and its coronal portion. The term "hemisection" is frequently used with reference to the lower molars<sup>1</sup> and is indicated where one of the roots of a molar is unsalvageable due to caries, periodontitis, or iatrogenic mishaps.<sup>2</sup> The procedure represents a form of conservative dentistry that aims to retain as much of the original tooth structure as possible.<sup>3</sup> The results are predictable, and success rates are high if certain basic considerations are taken into account like making an area self-cleansable by removing the tip of the root carefully and preventing root fracture by restoring with an adequate extra-coronal restoration.<sup>4</sup> Endodontic, periodontal, and prosthodontic assessment for appropriate selection of cases is crucial. From a periodontal perspective, this procedure is indicated if there

is severe bone loss or dehiscence limited to one root or involvement of a class III furcation that could produce a stable root after hemisection. This procedure is also appropriate if the patient is unable to perform appropriate oral hygiene in the area. From a restorative standpoint, treatment by hemisection is indicated for failure of an abutment within a fixed prosthesis, provided a portion of the tooth can be retained to act as the abutment for the prosthesis. Untreatable endodontic failure, due to circumstances, such as perforations and broken instruments, is another indication for hemisection. Other indications include vertical root fracture confined to a single root of a multirouted tooth or any severe destructive process that is confined to a single root, including caries, external root resorption, and trauma.<sup>5</sup> Contraindications include inoperable remaining roots for the necessary root canal treatment, fusion or proximity of the roots that may prevent their separation, deep furcation, and the presence of a strong abutment tooth adjacent to the proposed hemisection, which could act as an abutment to a prosthesis.<sup>6</sup>

## CASE REPORT

A 15-year-old male patient reported to the department of conservative and endodontics, with the chief complaint of decayed teeth in the lower right and left back region. On further enquiry, the patient did not give any significant medical and dental history. Extraoral examination revealed no abnormality. On intraoral examination, it was found that the patient had fair oral hygiene (Fig. 1). Class II deep cavitated carious lesions were found with 36. Intraoral periapical radiograph showed severe distal caries with 36 along with grade II furcation involvement and periapical radiolucency of size 2 × 2 cm associated with both the roots (Fig. 2). Periodontal support of 36 was found to be good. Interproximal bone loss was seen between 36 and 37. Periodontal prognosis with 36 was good and pulp vitality test was negative. Thus, the case was diagnosed as a periapical pathology with lower left mandibular 1st molar (36). Treatment options included extraction of 36 followed by placement of implant and fixed partial denture or removable partial denture placement or hemisection of the distal root of 36 followed by prosthetic replacement. The patient did not

<sup>1</sup>Private Practitioner, <sup>2,3</sup>Senior Lecturer

<sup>1</sup>Chopra Dental Care, Mahasamund, Chhattisgarh, India

<sup>2</sup>Department of Conservative Dentistry and Endodontics Rungta College of Dental Sciences and Research, Bhilai Chhattisgarh, India

<sup>3</sup>Department of Public Health Dentistry, Rungta College of Dental Sciences and Research, Bhilai, Chhattisgarh, India

**Corresponding Author:** Anjali Gupta, Senior Lecturer Department of Conservative Dentistry and Endodontics, Rungta College of Dental Sciences and Research, Bhilai, Chhattisgarh India, Phone: +918109422554, e-mail: rohitagrawalphd@gmail.com

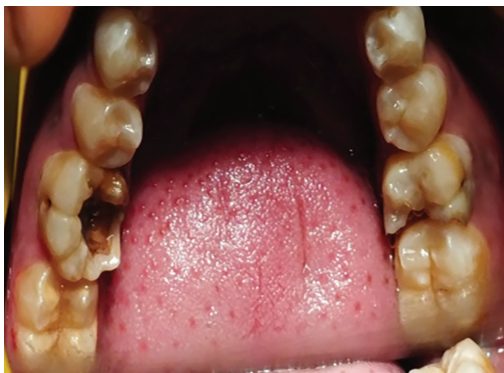

Fig. 1: Preoperative photograph showing distal caries with 36

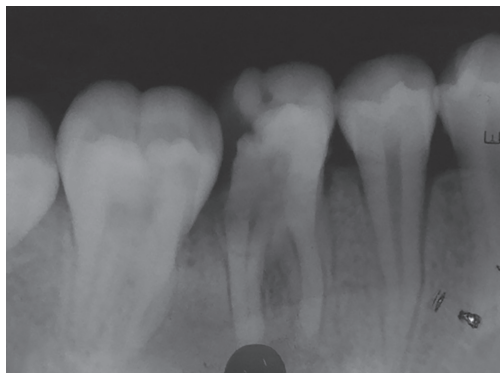


Fig. 2: Preoperative radiograph showing distal caries with 36

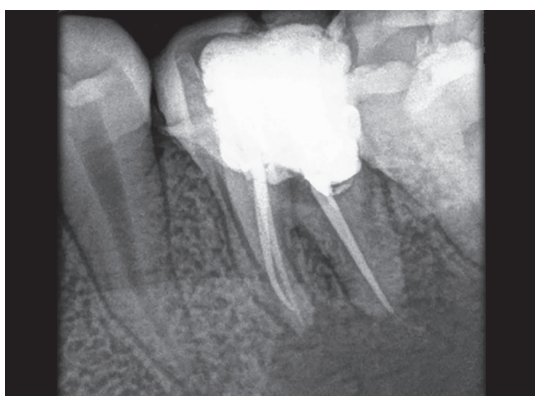


Fig. 3: Radiograph showing obturation with 36

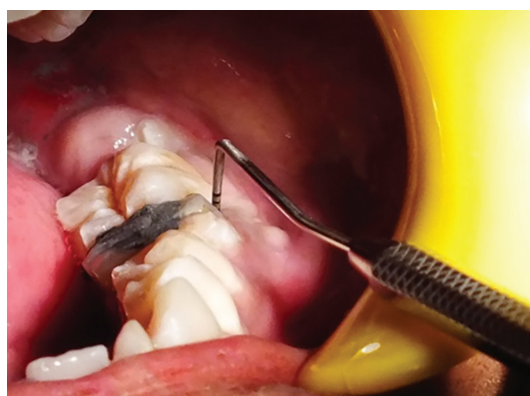

Fig. 4: Pocket in relation to distobuccal region of 36

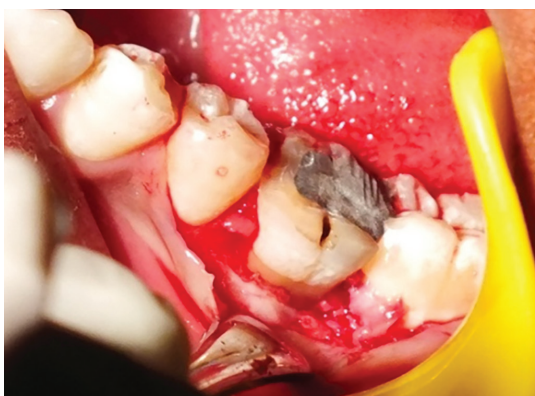

Fig. 5: Flap reflection with 36

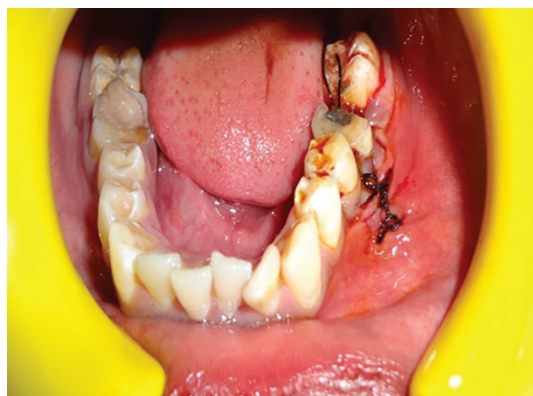

Fig. 6: Hemisection done with 36

wish to get tooth extracted, so a conservative treatment option was opted after taking an informed consent from the patient. The treatment procedure was carried along the following case.

**ENDODONTIC PHASE**

Endodontic phase involved root canal treatment of 36 in a conventional manner (Fig. 3). After 15 days of obturation, hemisection was carried out (Figs 4 to 7).

**PERIODONTIC PHASE**

After appropriate local anesthesia and under all aseptic condition, a crevicular incision was made extending from the 1st premolar to the 2nd molar region with a 12# blade

(Swann Morton). A full-thickness mucoperiosteal flap was elevated to provide adequate access for visualization and instrumentation and to ensure minimize surgical trauma (Fig. 5). A long shank tapered fissure carbide bur (SS White) was used to make vertical cut faciolingually toward the bifurcation area. The furcation area was too deep, and the distal coronal part was grossly decayed, which lead to the fracture of the crown with 36, which made it too difficult to remove the radicular part, so slight bone guttering was performed with bur. But due to the presence of the large periapical radiolucency with 36, the radicular part got dislodged and seated horizontally 2 cm below. After a tedious effort, the distal root was removed. Proper care was ensured not to traumatize the

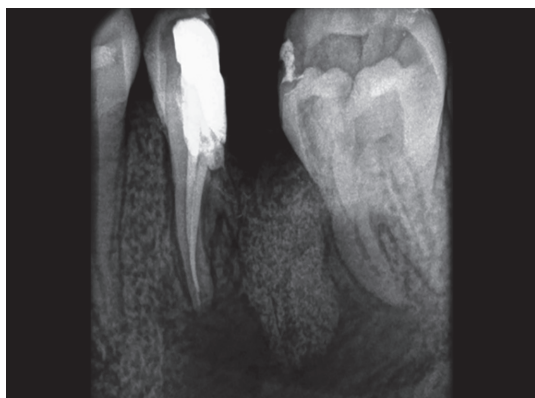

Fig. 7: Postoperative radiograph

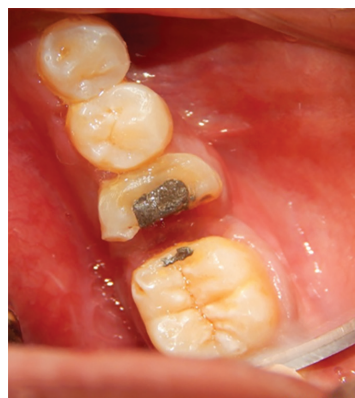

Fig. 8: Healing after 4 weeks

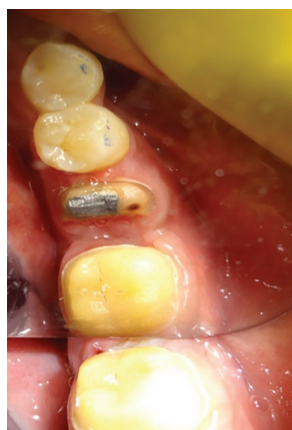

Fig. 9: Tooth preparation with 36

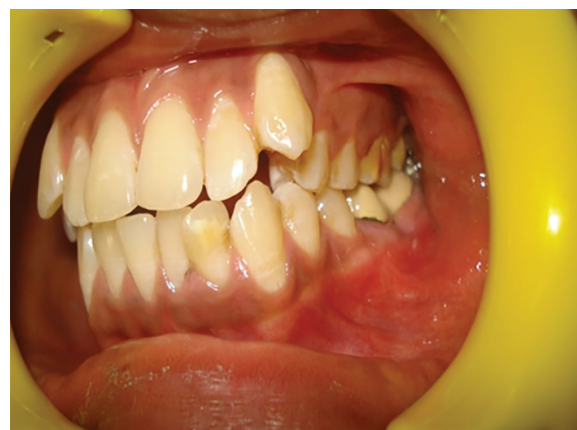

Fig. 10: Fixed prosthesis cementation with 36 and 37

adjacent tooth while removing the distal root. Debridement and irrigation of the socket along with thorough root planning of the mesial root was performed. Odontoplasty was performed to remove the developmental ridges, and the distal aspect of the mesial root was contoured in such a way as to facilitate the oral hygiene measures. Socket preservation was done by grafting the extraction site with "Perioglass" (GC America Inc). The buccal and lingual flaps were approximated to cover the graft. Sutures were given, COE pack surgical dressing was placed, and then the patient was dismissed with postoperative instructions along with antibiotics, analgesics, and chlorhexidine mouthwash (Figs 6 and 7). The surgical site was then allowed to heal with special consideration such that no occlusal stress was imposed on the mesial root of 36 for 4 weeks (Fig. 8). The patient was called again after 3 months. Radiograph revealed good bone regeneration, which indicated good uptake of the graft. Restoration of hemisected tooth was then planned with a fixed partial denture in relation to 36 and 37.

### PROSTHODONTIC PHASE (RESTORATION OF HEMISECTED TOOTH)

Diagnostic impressions were made with additional silicone impression material (Coltene), and diagnostic casts

were obtained. Face bow record was transferred to a semi-adjustable articulator, and maxillary cast was mounted. Mandibular diagnostic cast was mounted using interocclusal record, to check for any occlusal prematurities and interferences, and the necessary occlusal corrections were carried out. Tooth preparation was done in relation to mesial root of 36 and 37 to receive a metal ceramic restoration (Fig. 9). The margin on mesial surface of 37 was placed approximately 3 to 4 mm above the gingival margin as the tooth was mesially tilted or else excessive tooth structure would have been lost in order to create a favorable path of insertion. This will also help in the maintenance of gingiva by making it self-cleansable. The final impression was made using the putty-reline technique and a master cast was obtained. The mandibular master cast was mounted using interocclusal record. Wax pattern was fabricated, sprued, and invested. The casting procedure was carried out using standard techniques. A metal framework was tried in the patient's mouth followed by ceramic build-up and bisque try-in. The final prosthesis was cemented using glass ionomer cement (Fig. 10). Post-cementation instructions regarding periodontal maintenance were given. Recall was done periodically to assure the healing and success of the restoration.

## DISCUSSION

Hemisection is the total removal of the crown portion along with the selected root. Buhler stated that hemisection should be considered before every molar extraction, because this procedure can provide a good absolute biological cost savings with good long-term success. The terms "root amputation" and "hemisection" are collectively known as "root resection." According to Newell, the advantage of amputation, hemisection, or bisection is the retention of some or the entire tooth. However, the disadvantage is that the remaining root or roots must undergo endodontic therapy and the crown must undergo restorative management.<sup>7-9</sup>

Newell examined 70 root resected molars in 62 patients for the quality of the resections. Twenty-one (30%) of the resections were considered faulty when subgingival, residual roots, furcal lips, and/or ledges were present. Failures were more frequent in maxillary molars (33.3%) than in mandibular molars (22.7%).<sup>10</sup>

However, the failure to perform endodontic care first is not a contraindication for root resectioning, if it can be determined that a successful root canal filling is practical and possible. It has been shown that vital root resections are possible, especially in the maxilla, with symptoms not being manifested until several weeks after the placement of a sedative dressing of choice. Provisions also must be made to stabilize the remaining portion of the molar, unless it already serves as a bridge abutment. On the contrary, if a hemisection is performed, the remaining root may be used as an abutment for a small bridge; alternatively, it may remain as a single crown or be used as a telescopic crown.<sup>7</sup>

Park et al have suggested that molars that have questionable prognosis can be maintained without detectable bone loss for a long-term period by hemisection but the patient should maintain a good oral hygiene.

Shin-Young Park performed root resection therapy on 691 molars in 579 patients. The associated factors were examined from 342 of 402 molars that had been followed up for >1 year. They concluded root resection to treat periodontal problems had a better prognosis than for non-periodontal problems. To achieve a good result, it was important that the remaining roots had >50% bone support. This guideline may help to improve the predictability of root resection therapy.<sup>10</sup>

Erpenstein reported the results of root resection of 34 molars examined clinically and radiographically over 4 to 7 years. During the follow-up period, three treated molars were extracted: Two of them due to symptomatic apical periodontitis and one due to periodontal pocketing and excessive mobility. The treated teeth were successfully used as abutments for small bridges. There was no

statistically significant difference in probing the depth between root resected and other surfaces at final examination, and a significant reduction in probing depth was observed and maintained as a result of treatment.<sup>7</sup>

Hemisection has been used successfully to retain teeth with furcation involvement.<sup>7</sup> Like any other clinical procedure, the success or failure of a hemisection procedure depends on good case selection and diagnosis as much as it depends on effectively carrying out the procedure.<sup>11</sup> Hemisection is a useful and effective alternative procedure to save those multi-rooted teeth that have been indicated for extraction. Conservation of what is present is far better than meticulous removal of the structure. Before selecting a tooth for hemisection, the patient's oral hygiene status, caries index, and medical status should always be considered. Also, root divergence, root form, remaining root attachment, and accessibility of root furcation for easy separation should be assessed.<sup>12</sup>

Hemisection is mostly carried out in mandibular molar because of more easily filled distal root. But the distal root was resected in this case due to the site of the decay. As per our search of the literature, the data on distal root resection is very limited.<sup>5</sup>

Saad et al have concluded that hemisection of a mandibular molar may be a suitable treatment option when the decay is restricted to one root and the other root is healthy and the remaining portion of tooth can very well act as an abutment.<sup>13</sup>

However, as every coin has two faces, so there are a few disadvantages associated with hemisection. Like other surgical procedures, it can cause pain and anxiety, root surfaces that are reshaped at the site of hemisection are more susceptible to caries, often a favorable result may be negated by decay after treatment, and failure of endodontic therapy due to any reason will cause failure of the procedure. In addition, when the tooth has lost a part of its root support, it will require a restoration to permit it to function independently or to serve as an abutment for a splint or bridge. Unfortunately, a restoration can contribute to periodontal destruction, if the margins are defective or if nonocclusal surfaces do not have physiologic form. Also, an improperly shaped occlusal contact area may convert acceptable forces into destructive forces and predispose the tooth to trauma from occlusion and ultimate failure of hemisection.<sup>7</sup>

## CONCLUSION

Hemisection to retain a compromised tooth, in the restoration armory of the restorative dentist, offers a predictable treatment option with a favorable prognosis. The key, with any restorative treatment, is to best weigh

all the pros and cons before deciding which procedure is a suitable one to be undertaken. With recent advancements in endodontics, periodontics, and restorative dentistry, hemisection has received acceptance as a conservative and reliable dental treatment, and teeth so treated have endured the demands of function. With systematic plaque control, periodontal bone loss of hemisectioned teeth can be kept to a minimum. From the periodontal standpoint, it is advantageous to avoid removable partial dentures and all metal crowns when hemisectioned teeth can be used as abutments for short-span bridges with optimal articulation. This article presents valuable information on a novel treatment modality that would indeed help the authors in their pertinent treatment planning and will ensure in a better treatment outcome.

## REFERENCES

1. Shillingburg HT, Hobo S, Whitsett LD, Jacobi R, Brackett SE. Preparation for periodontally weakened teeth. In: Fundamentals of fixed prosthodontics. 3rd ed. Chicago: Quintessence; 1997. p. 211-223.
2. Shafiq MK, Mirza AJ, Asaad S. Hemisection: An option to treat apically fractured and dislodged part of a mesial root of a molar. *J Pak Dent Assoc* 2011 Jul;20(3):183-186.
3. Kost WJ, Stakiw JE. Root amputation and hemisection. *J Can Dent Assoc* 1991 Jan;57(1):42-45.
4. Kurtzman GM, Silverstein LH, Shatz PC. Hemisection as an alternative treatment for vertically fractured mandibular molars. *Compend Contin Educ Dent* 2006 Feb;27(2):126-129.
5. Saad MN, Moreno J, Crawford C. Hemisection as an alternative treatment for decayed multirooted terminal abutment: a case report. *J Can Dent Assoc* 2009 Jun;75(5):387-390.
6. Weine FS. Endodontic therapy. 5th ed. St Louis (MO): Mosby; 1996.
7. Bhutada G. Hemisection as a treatment option: a case report and review. *Indian J Dent Res Rev* 2011 Oct-2012 Mar;87-90.
8. Shetty PP, Meshramkar RD, Lekha K, Patil KN, Nadiger RK, Lokwani BG. Hemisection – A window of hope for a perishing tooth. *Int J Clin Dent Sci* 2011;2(4):4-7.
9. Joshipura V. Hemisection – A relevant, practical and successful treatment option. *J Int Oral Health* 2011;3(6):43-48.
10. Shah S, Modi B, Desai K, Duseja S. Hemisection – A conservative approach for a periodontally compromised tooth: a case report. *J Adv Oral Res* 2012 May-Aug;3(2):31-35.
11. Chhabra V, Chhabra A. Hemisection: Saviour of a furcation. *Indian J Dent Sci* 2011 Mar;3(1):6-8.
12. Jain A, Bahuguna R, Agarwal V. Hemisection as an alternative treatment for resorbed multirooted tooth: a case report. *Asian J Oral Health Allied Sci* 2011;1(1):44-46.
13. Akki S, Mahoorkar S. Tooth hemisection and restoration an alternative to extraction: a case report. *Int J Dent Clin* 2011 Jul-Sep;3(3):67-68.

