

## REVIEW ARTICLE

# Esthetic Design

<sup>1</sup>Mukta Nigam, <sup>2</sup>Sanjeev Tyagi, <sup>3</sup>Manali Tiwari, <sup>4</sup>Medha Bhushan, <sup>5</sup>Abhishek Choudhary, <sup>6</sup>Madhuri Gupta

## ABSTRACT

An attractive face is of utmost priority to people. Attractiveness is based on symmetry and various proportions of the face. This helps us to design the smile beautifully and add a lot to facial esthetics. It is a multidisciplinary approach that includes orthodontics, cosmetic dentistry, and plastic surgery. It is very important to carefully analyze and plan the treatment according to the patient's demand, which will lead us to a beautiful smile.

**Keywords:** Dental composition, Digital smile design, Proportion, Smile.

**How to cite this article:** Nigam M, Tyagi S, Tiwari M, Bhushan M, Choudhary A, Gupta M. Esthetic Design. J Orofac Res 2015;5(4):130-133.

**Source of support:** Nil

**Conflict of interest:** None

## INTRODUCTION

Nonverbal communications are possible with various facial expressions. The most attractive of all our facial features is the smile, as it is an expression of the person as a whole. The beauty of a person's face is enhanced and maintained by a pleasant smile and reflects the qualities of that person's character. Creating a pleasing teeth arrangement in harmony with the gingiva, lips, and face of the patient is important.<sup>1</sup>

## ANATOMY OF SMILE

The upper and lower lips create the display zone of the smile. Within this framework, the components of the smile are the teeth and the gingival scaffold. The soft tissue determinants of the display zone are lip thickness, intercommisural width, interlabial gap, smile index (width/height), and gingival architecture.<sup>2,3</sup> The curve formed by the incisal edges of the maxillary anterior teeth is called the "smile arc." The vertical aspects of the smile anatomy are based on the degree of the maxillary anterior

tooth display (Morley ratio), upper lip drape, and the percentage of gingival display.<sup>4</sup>

## SMILE COMPONENTS

A smile is something that bridges a large gap between any two individuals. Goldstein<sup>14</sup> described certain parameters of a beautiful smile, which are described below.

There are two facial features that do play a major role in the smile design.

1. The interpupillary line
2. Lips

In classical terms, there are two dimensions for ideal face: Vertical and horizontal.

- Horizontal
  - The width of the face should be the width of five "eyes."
  - The distance between the eyebrow and the chin should be equal to the width of the face.
- Vertical
  - The facial height is divided into three equal parts from the forehead to the eyebrow line, from the eyebrow line to the base of the nose, and from the base of the nose to the base of the chin.
  - The full face is divided into two parts, eyes being the midline.
  - The lower part of the face from the base of the nose to the chin is divided into two parts: The upper lip forms one-third of it and the lower lip and the chin two-thirds.<sup>5</sup>

## Dental Composition

The vital elements of smile designing include the following:

- Tooth components
  - Dental midline
  - Incisal lengths
  - Tooth dimensions
  - Zenith points
  - Axial inclinations
  - Interdental contact area (ICA) and interdental contact point (ICP)
  - Incisal embrasure
  - Sex, personality, and age
  - Symmetry and balance
- Soft tissue components
  - Gingival health
  - Gingival levels and harmony

<sup>1,3-6</sup>Postgraduate Student, <sup>2</sup>Professor and Head

<sup>1-4</sup>Department of Conservative Dentistry and Endodontics  
People's Dental Academy, Bhopal, Madhya Pradesh, India

<sup>5</sup>Department of Orthodontics and Facial Orthopaedics  
People's Dental Academy, Bhopal, Madhya Pradesh, India

<sup>6</sup>Department of Oral Medicine and Radiology, People's Dental  
Academy Bhopal, Madhya Pradesh, India

**Corresponding Author:** Mukta Nigam, Postgraduate Student  
Department of Conservative Dentistry and Endodontics  
People's Dental Academy, Bhopal, Madhya Pradesh, India  
Phone: +919893474974, e-mail: mukta8@gmail.com

- Interdental embrasure
- Smile line.

### Zenith Points

Zenith points are the most apical position of the cervical tooth margin where the gingiva is most scalloped. It is located slightly distal to the vertical line drawn down the center of the tooth. The lateral is an exception as its zenith point may be carefully located. Establishing the proper location of zenith points is a critical step in alteration of mesial and distal dimensions.<sup>6,7</sup>

## PROPORTIONS

### Golden Proportion

In dentistry, the term “golden proportion” is a mathematical theorem concerning the proportions of the dentition. It is considered as the only mathematical tool for determining proportion in the arrangement of the maxillary teeth from the frontal view.<sup>8</sup> Pythagoras described it as:

According to this rule, if the width of each anterior tooth is approximately 60% of the size of its adjacent anterior tooth then it is considered esthetically pleasing. It follows logically that if the width of the lateral incisor is 1, the central should be 1.618 times wider and the canine 0.618 times narrower. Snow proposed that the golden proportion width of each tooth should be as follows: Canine 10%, lateral 15%, central 25%, central 25%, lateral 15%, and canine 10% of the total distance across the anterior segment, in order to achieve an esthetically pleasing smile.<sup>9</sup>

### RECURRING ESTHETIC DENTAL PROPORTION

Ward suggested the recurring esthetic dental (RED) proportion. He based his suggestion on the result of his study in which he described RED proportion as the proportion of the successive width of the teeth remaining constant, when progressively distal from the midline.<sup>10</sup>

### SINGLE TOOTH PROPORTION

The central incisor, as a tooth alone, should have a width height proportion within itself. The most pleasing width-to-length ratio for maxillary central incisors is approximately 75 to 80% in a pleasant smile. However, it has been reported that it can vary between 66 and 80%. Put another way, a relation of 10:8 in length width is reasonable for the maxillary central incisors. An 85% width-to-height ratio will give a square appearance, whereas a 65% width-to-height ratio will make the teeth appear longer. Therefore, the elements discussed above should not be accepted as an absolute rule.<sup>11</sup>

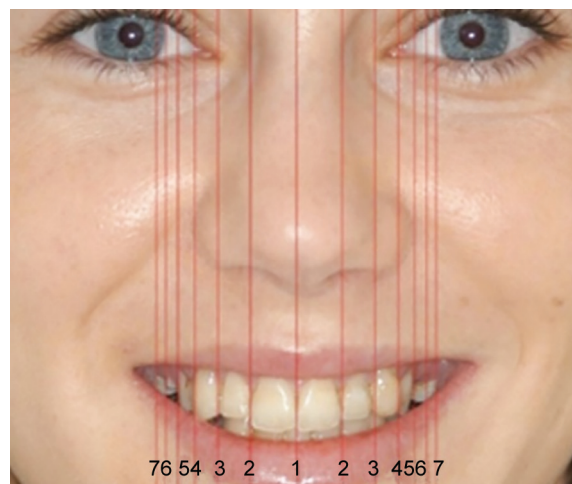


Fig. 1: M proportion

### M PROPORTION

The patient's photograph is taken and computer-generated lines are superimposed on it; these lines can be altered by sliding the lines “en masse.” These lines will retain their modified golden proportion as they slide; these new proportions are called “M” proportions. By positioning the first line (no. 1) on the midline and moving the end line (no. 7) to the buccal cusp of the first molar, line no. 2 will have to be at the distal of the central (Fig. 1).

The new mathematical formula determines a variable ratio in the function of Phi called the “M” proportions (“M” stands for Methot, the inventor). It can be seen that the modified ratio for this patient is 1.367 as opposed to the golden rule of 1.618. Subjects were analyzed using the “Guided Positioning Software” program, which uses this “M” proportions rule.<sup>12</sup>

### Classification of Smile

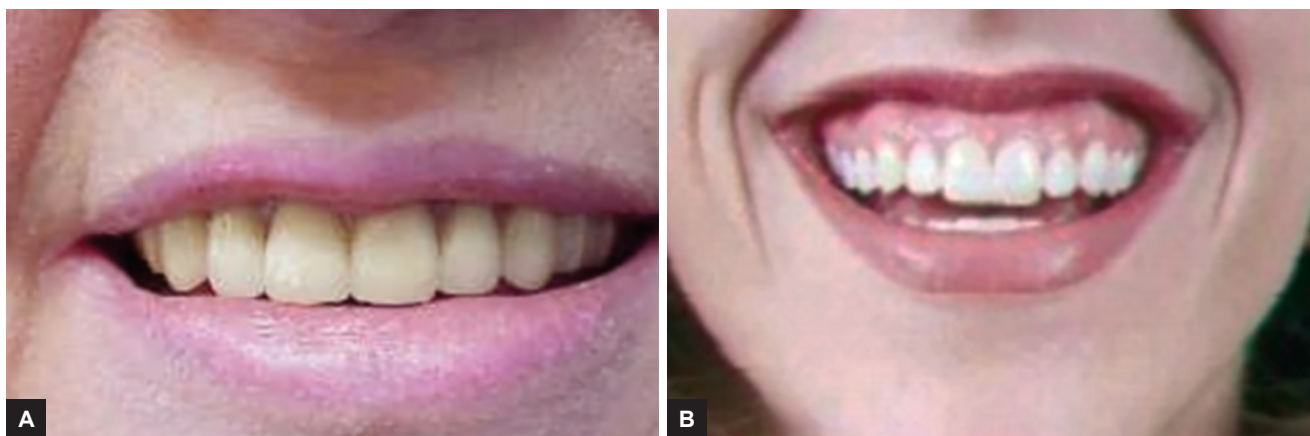There are two types of smiles: The social smile and the enjoyment smile (Figs 2A and B). Each type involves a different anatomic presentation of the display zone.

The social smile, or the smile typically used as a greeting, is a voluntary, unstrained, static facial expression.<sup>13</sup>

#### *Perceptual Aspects: The Art of Illusion*

The art of creating illusions consists of changing perception, to cause an object to appear different from what it actually is.

- Teeth can be made to appear smaller, larger, wider, narrower, shorter, longer, younger, or older.
- If a tooth is subjected to light, it exhibits two dimensions: The height and the width.
- True natural light is multidirectional on striking the surface, and reveals texture and shadows; this adds the dimension depth.



**Figs 2A and B:** Anterior tooth display in social and enjoyment smiles; note the difference in gingival show

**Principle of Illumination**

- Unidirectional artificial light throws no shadows and displays only length and width.
- Multidirectional natural light throws shadows, resulting in a feeling of depth.

**Principle of Line**

- Creation of horizontal lines causes an illusion of a wider tooth.
- Creation of vertical lines causes illusion of a longer tooth.

**Law of the Face**

- Face of the tooth is bound by transitional line angles.
- Two teeth with dissimilar widths exhibit difference in the position of these line angles, making the apparent faces unequal.<sup>14,15</sup>

**RECENT ADVANCES**

The Digital Smile Design (DSD) is a multiuse conceptual tool that can strengthen diagnostic vision, improve communication, and enhance predictability throughout the treatment. The DSD allows for careful analysis of the patient’s facial and dental characteristics along with any critical factors that may have been overlooked during clinical, photographic, or diagnostic cast-based evaluation procedures. The drawing of reference lines and shapes over extra- and intraoral digital photographs in a predetermined sequence can widen diagnostic visualization and help the restorative team evaluate the limitations and risk factors of a given case, including asymmetries, disharmonies, and violations of esthetic principles. A DSD sketch can be performed in presentation software. This improved visualization makes it easier to select the ideal restorative technique. The DSD protocol is characterized by effective communication between the interdisciplinary dental team, including the dental technician (Table 1).<sup>16,17</sup>

**Table 1:** Various clinical problems and their restorative procedures

<i>Clinical situations</i>	<i>Restoration problem</i>	<i>Achieved by illusion</i>
Crowding of teeth	Less space to align teeth	Creating a restoration that looks wider than the space it occupies. Additionally, slight overlapping of the teeth may be required.
Narrow pontic space	Less mesiodistal width	Creating a restoration that looks wider than the space it occupies.
Elongated clinical crowns after periodontal surgery	Proportion between the length and the width of the teeth is improper	Creating a restoration that looks wider and shorter, improving perceptive proportions.
Diastema	Closure of spaces will alter proportions and make the restoration look wide	Creating a restoration that looks narrower than the space it occupies.
Large pontic space	More width available to replace tooth/teeth	Creating a restoration that looks narrower than the space it occupies. Additionally, small spaces may be left in between the teeth.
Disproportionate teeth	To control tooth proportions	Recontouring the teeth or creating restorations to bring about a better perceptive proportion by widening, lengthening, shortening, or narrowing individual teeth.
Long pontics	Long and unesthetic appearance	Creating restorations that make the teeth look shorter than the space they occupy. Additionally, artificial gingival creation can be done.
Short maxillary incisor that cannot be lengthened by surgery	Short and unesthetic incisor	Creating an appearance of a longer tooth.

## CONCLUSION

We should have a thorough knowledge and understanding about all the aspects of smile design. We should take into consideration the material, color, shade principles, and other rules and proportion while designing a patient's smile. The anatomy of a tooth is very important, so proper study and study models should be prepared in order to consider the smile.

## REFERENCES

1. Patnaik VVG, Singla RK, Bala S. Anatomy of 'a beautiful face & smile'. *J Anat Soc India* 2003;52(1):74-80.
2. Shillingburg HT Jr, Kaplan MJ, Grace SC. Tooth dimensions—a comparative study. *J South Calif Dent Assoc* 1972 Sep; 40(9):830-839.
3. Wheeler R, Ash MM. Dental anatomy, physiology and occlusion: an atlas of tooth form. Philadelphia (PA): Saunders; 1984. p. 137.
4. Ackerman JL, Ackerman MB, Brensinger CM, Landis JR. A morphometric analysis of the posed smile. *Clin Orthod Res* 1998 Aug;1(1):2-11.
5. Davis NC. Smile design. *Dent Clin North Am* 2007 Apr; 51(2):299-318.
6. Lavere AM. Denture tooth selection: an analysis of the natural maxillary central incisor compared to the length and width of the face. Part I. *J Prosthet Dent* 1992 Jun;67(6):661-663.
7. Bukhary SM, Gill DS, Tredwin CJ, Moles DR. The influence of varying maxillary lateral incisor dimensions on perceived esthetic smile. *Br Dent J* 2007 Dec;203(12):687-693.
8. Rosenstiel SF, Land MF, Fujimoto J. Contemporary fixed prosthodontics. 3rd ed. St Louis (MO): CV Mosby; 2001. p. 598-599.
9. Snow SR. Esthetic smile analysis of maxillary anterior tooth width: the golden percentage. *J Esthet Dent* 1999;11(4): 177-184.
10. Mohan B. Principles of smile design. *J Conserv Dent* 2010 Oct-Dec;13(4):225-232.
11. Galip G. The science and art of porcelain laminate veneers. New Malden: Quintessence Publications; 2003.
12. Methot A. M Proportions. The new golden rules in dentistry. *Can J Cosmetic Dent* 2006;1:34-40.
13. Rubin LR. The anatomy of a smile: Its importance in the treatment of facial paralysis. *Plast Reconstr Surg* 1974 Apr;53(4): 384-387.
14. Goldstein RE. Change your smile. Chicago (IL): Quintessence Publication; 1999.
15. Rajtilk G, Deepa S, Rajasekar V, Vanitha R. Anterior teeth and smile designing: a perspective view. *Int J Prosthodont Restor Dent* 2012;2(3):117-127.
16. Coachman C. Digital smile design: a tool for treatment planning and communication in esthetic dentistry. *Quintessence Dent Technol* 2012;1:1-10.
17. Ackerman M, Ackerman J. Smile analysis and design in the digital era. *J Clin Orthod* 2002 Apr;36(4):221-236.
18. Dekker BC, editor. Esthetics in Dentistry. 2nd ed. Shelton, United States;2014.