

## CASE REPORT

# Prosthodontic Rehabilitation of a Patient with Velopharyngeal Insufficiency using Hollow Speech Aid Prosthesis

<sup>1</sup>Sreeramulu Basapogu, <sup>2</sup>P Ajay, <sup>3</sup>P Suman

## ABSTRACT

Rehabilitation of the missing oral and extraoral structures is one of the main aim of prosthodontics. Each patient has a different type of defect that presents with its own limitations and difficulties for successful rehabilitation. Defect of any extent resulting from surgical treatment of benign and malignant neoplasms, trauma or congenital defects causes problems in mastication, speech and esthetics. Pharyngeal obturator is a prosthesis which closes the palatal and pharyngeal defects and improving the speech and other functions. The following case report discusses about palatopharyngeal insufficiency, impression procedures, fabrication of prosthesis and improvements in speech.

**Keywords:** Hypernasality, Pharyngeal obturator, Speech aid prosthesis, Velopharyngeal insufficiency.

**How to cite this article:** Basapogu S, Ajay P, Suman P. Prosthodontic Rehabilitation of a Patient with Velopharyngeal Insufficiency using Hollow Speech Aid Prosthesis. *J Orofac Res* 2015;5(2):68-71.

**Source of support:** Nil

**Conflict of interest:** None

## INTRODUCTION

Velopharyngeal insufficiency is a condition in which there is lack of effective closure between soft palate and one or more walls of pharynx during swallowing or speech sounds which require high intraoral pressure.<sup>1</sup> The soft palate, lateral and posterior pharyngeal walls form the velopharyngeal (VP) closure so that all of them create a three-dimensional (3D) muscular valve which is known as VP sphincter.<sup>2</sup>

Velopharyngeal insufficiency refers to speech and resonance abnormalities related to the soft palate defects which may be congenital as in cleft lip and palate (CLP)

or acquired as in palatal tumor resection.<sup>3,4</sup> The primary effects of the VP insufficiency are air-flow escape and hypernasality.<sup>5,6</sup> Secondary effects are disorders in speech articulation (distortions, substitutions and omissions).<sup>7</sup>

In this regard patients usually have psychological problems together with physical difficulties.<sup>8</sup> Surgery in combination with speech therapy is a common approach in the treatment of VP dysfunction. For patients who cannot receive surgical treatment, prosthetic treatment, such as speech aid prosthesis (SAP) combined with speech therapy is the choice of treatment.<sup>9</sup>

Speech aid prosthesis is a removable maxillary prosthesis which has a posterior extension to separate oropharynx and naso-pharynx.<sup>10</sup> It restores defect of soft palate and allows adequate closure of VP sphincter.<sup>11</sup>

## CASE REPORT

A 19 years old male patient reported to Department of Prosthodontics, Government Dental College and Hospital, Hyderabad with a chief complaint of difficulty in having food, drinking water due to aspiration and difficulty in speech. On intraoral examination patient had a class II defect according to Veau's classification of cleft palate measuring 3.5 cm in length and 1 cm in width. Maxillary central and lateral incisors on right and left side were missing (Fig. 1).

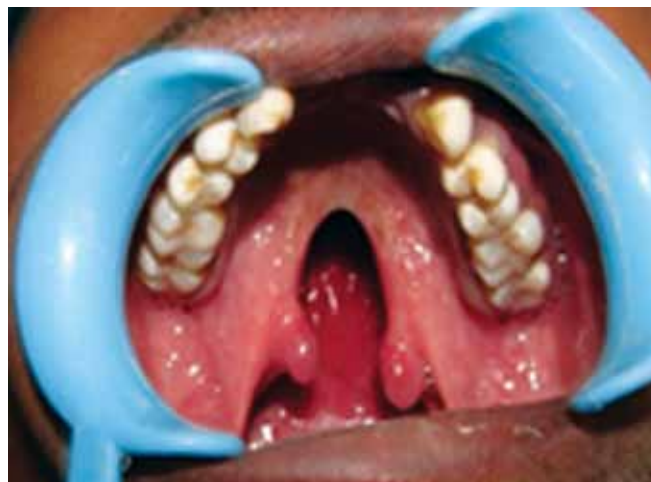
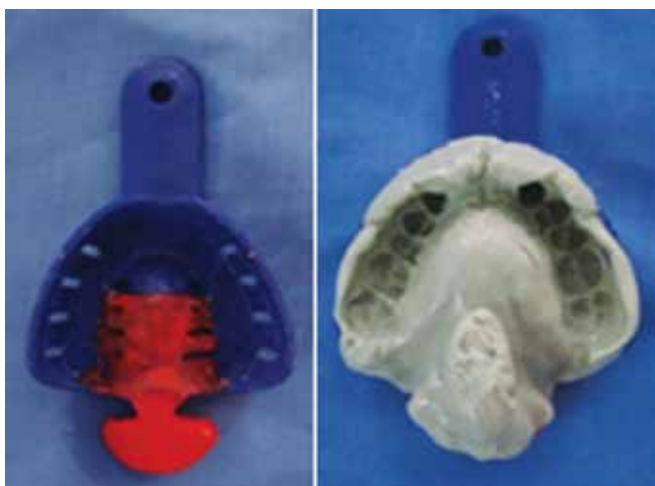
Fig. 1: Intraoral view (Pretreatment)

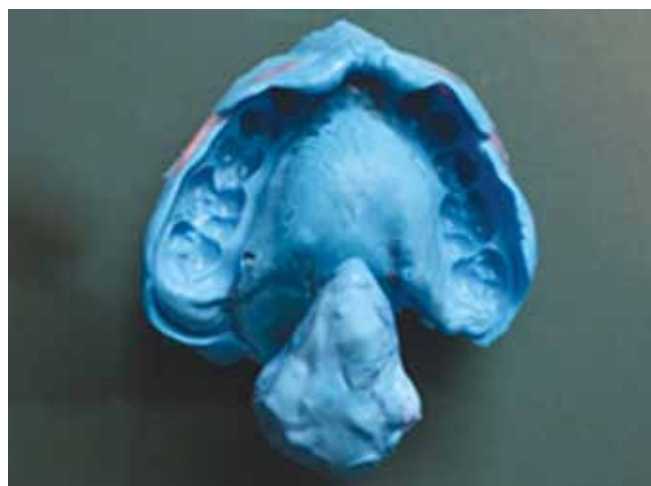<sup>1</sup>Associate Professor and Incharge, <sup>2,3</sup>Postgraduate Student

<sup>1-3</sup>Department of Prosthodontics, Government Dental College and Hospital, Hyderabad, Telangana, India

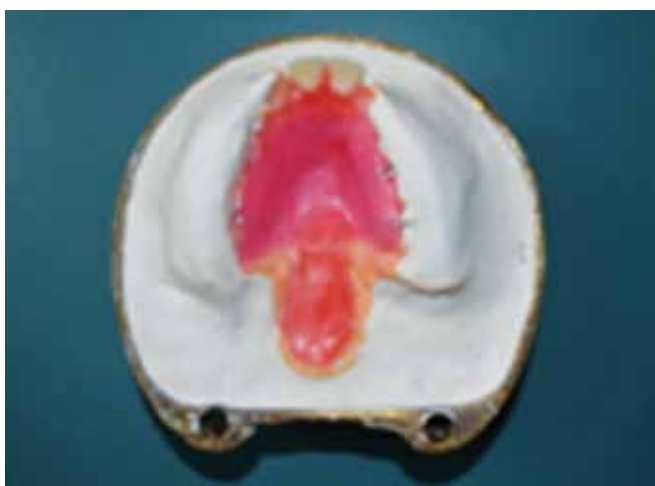**Corresponding Author:** Sreeramulu Basapogu, Associate Professor and Incharge, Department of Prosthodontics Government Dental College and Hospital, Hyderabad Telangana, India, Phone: 04024601930, e-mail: drsreeramulub@gmail.com



**Fig. 2:** Tray extension with modeling wax and primary impression



**Fig. 3:** Secondary or final impression



**Fig. 4:** Investing the master cast

The patient's speech was hypernasal, he was unwilling to smile and his esthetic appearance was negatively affected. The patient refused to have a surgical reconstruction. After clinical evaluation of the defect it was concluded that the lesion was acceptable for prosthetic rehabilitation. A temporary pharyngeal obturator with clasp retention was planned since the patient had dentition. Complete treatment procedure was explained to the patient and consent was taken.

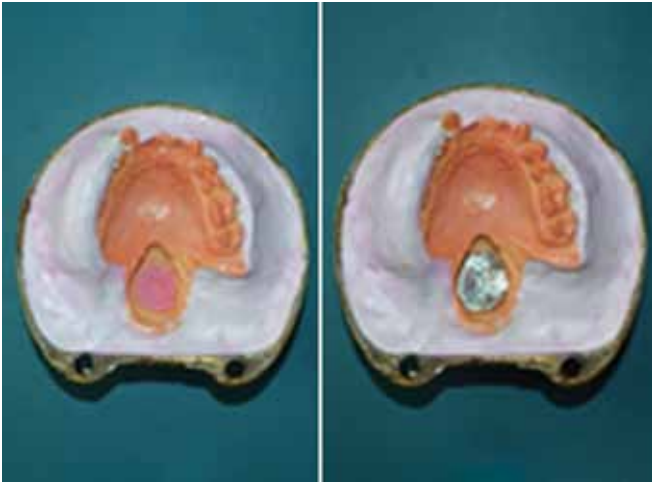
## PROCEDURE

**Preliminary impression:** A gauze pack coated with petroleum jelly (Madina chemicals, Hyderabad, India) was placed in the defect to prevent entry of the impression material into the nasal cavity. Dentulous stock tray of size-2 was selected and was extended posteriorly by 3 cm with modeling wax (Charminar Dental Products, Hyderabad, India). Impression of the maxillary arch was made using alginate (Zelgan, Dentsply India Pvt Ltd, Gurgaon, India) (Fig. 2). Primary cast was obtained using dental stone (Kalarock, Kalabhai Karson Pvt Ltd, Mumbai, India).

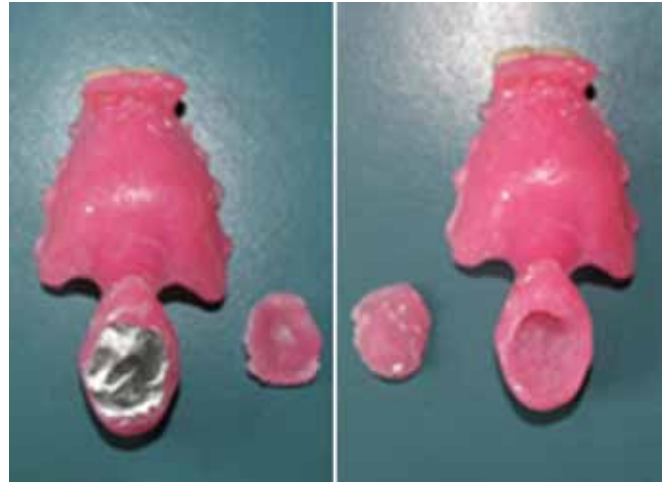
Custom tray extending into the defect was fabricated on the primary cast with autopolymerizing acrylic resin (DPI, Mumbai, India).

**Impression of pharyngeal section and final impression:** The functional impression of the pharyngeal section was made with putty vinyl polysiloxane impression material (Reposil, Dentsply Caulk, Milford, USA) using custom tray. The patient was asked to move his head in a circular manner from side to side, to extend his head as far forward and backward as possible and to say 'ah' and swallow, touch his shoulder with help of the chin then the impression was removed and inspected for over extensions, excess material was removed from the superior aspect until patient was able to breathe comfortably. If patient had difficulty in breathing, lateral surfaces of the impression was trimmed and tissues were recorded without pressure. Then wash impression was made using light body vinyl polysiloxane impression material (Reposil, Dentsply Caulk, Milford, USA) (Fig. 3). Elastomeric impression records the entire length of the soft palate and makes contact with the posterior pharyngeal wall. Later master cast was fabricated using die stone (Kalarock, Kalabhai Karson Pvt Ltd, Mumbai, India).

**Fabrication of prosthesis:** Jaw relations were recorded and casts were mounted on a semi-adjustable articulator and the artificial teeth (Premadent, Super Dental Products, Delhi, India) were arranged. A clinical wax try-in was performed. The master cast was waxed up with Adam's clasps (Konark ever bright dental SS wire, Made in India) on the first molars along with denture base and the defect area was filled with dental wax. After that master cast was invested (Fig. 4) followed by flasking and dewaxing. After dewaxing separating media (DPI, Mumbai, India) was applied all over including the defect area. Small amount of heat cure acrylic (DPI,



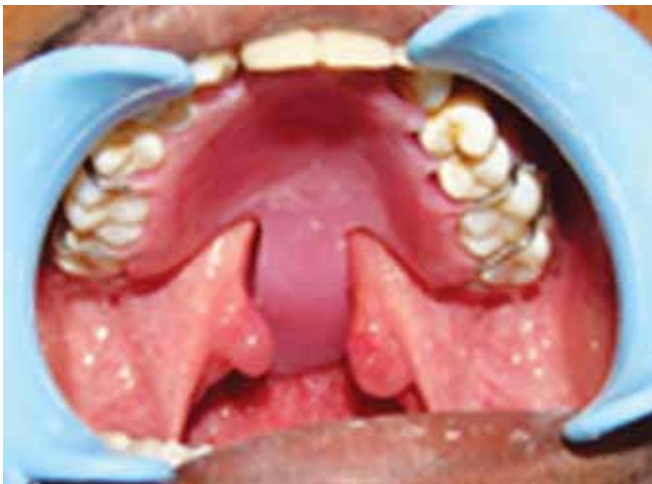**Fig. 5:** Acrylic adapted in dough stage and then covered with aluminum foil



**Fig. 6:** Upper and lower segments are separated by aluminum foil and upper segment hollowed leaving 2 mm thick walls



**Fig. 7:** Hollow speech aid prosthesis floating in water



**Fig. 8:** Postinsertion of the prosthesis

Mumbai, India) in dough stage was adapted on the base of defect after that aluminum foil (Parekh Aluminex Ltd, Dadra (U/T), India) was placed over acrylic resin in the defect (Fig. 5). Packing and processing was done similar to conventional denture fabrication. Prosthesis was retrieved after deflasking. Aluminum foil separates pharyngeal part of prosthesis into a small lower segment

and large upper segment (tissue side). Then upper segment was hollowed out leaving 2 mm thick walls (Fig. 6). Lower segment was attached to the upper segment using autopolymerizing acrylic resin (DPI). Prosthesis was trimmed, finished and polished. Air tight seal was confirmed by placing the prosthesis in a bowl of water (Fig. 7). Prosthesis was inserted in patient's mouth and checked for over extensions, occlusion, speech and nasal reflux (Fig. 8). Speech evaluation was performed by asking the patient to pronounce pressure consonants p, b, d, g and t and vowels in a sequence of i, a and u. Adequate VP closure was examined by asking the patient to drink water in upward head position and nasal reflux was checked. Postinsertion instructions were given and regular checkups were done at 1st week, 2nd week and 1 month which showed a reduced hypernasality and improved speech, mastication, swallowing and esthetics.

*Postinsertion adjustments:* Sore spots in the velopharynx were recorded on the prosthesis using pressure indicating paste and were relieved. Evaluation of speech was performed.

## DISCUSSION

Prosthetic rehabilitation of the patients suffering from VP defects with obturator prosthesis varies according to the location and nature of the defect or deficiency. Loss of some or all of the soft palate results in insufficient structure or impairment in function of the remaining structure to provide closure with the pharynx. In this report, the SAPs is designed to close the opening between the residual hard and/or soft palate and pharynx.

Retention of pharyngeal obturator can be obtained by Adams clasps. Although removable partial denture designs for patients with VP deficiencies are similar to removable partial denture designs for nonsurgical patients, the long lever arm created by the extension for the obturator must be considered. In this case report we have described a novel approach of using hollow bulb extension into nasopharynx for better retention of the prosthesis, by considerable reduction in its weight.

In this patient was asked to drink water to test the complete closure of the anatomical defect of soft and hard palate. The water should not reflux into the nasal cavity when the patient is in upright position. The success of the soft palate defect prosthesis depends on the functional adaptation of the impression material. There are several investigations like nasovideo-endoscopy, fluoroscopy, nasometric analysis and pressure flow techniques but perceptual analysis is best.

## CONCLUSION

In this case report, patient with soft palate defect such as VP insufficiency and different oral conditions was treated successfully with hollow bulb pharyngeal obturator/speech bulb prosthesis. A significant improvement in speech was observed after insertion of the prosthesis.

Overall, the esthetic outcome was satisfactory and the patient was very pleased with his new smile and speech.

## REFERENCES

1. Marsch JL. Management of velopharyngeal dysfunction. *J Craniofac Surg* 2003;14(5):621-628.
2. Bolender CL. Prosthetic treatment for edentulous patient: complete dentures and implant-supported prostheses. 12th ed. St. Louis: Mosby Inc; 2004. p. 449-470.
3. Johns DF, Rohrich RJ, Awada M. Velopharyngeal incompetence: a guide for clinical evaluation. *Plast Reconstr Surg J* 2003;112(7):1890-1897.
4. Wolfaardt JF, Wilson FB, Rochet A, McPhee L. An appliance based approach to the management of palatopharyngeal incompetency: a clinical pilot project. *J Prosthet Dent* 1993;69(2):186-195.
5. Beumer J III, Curtis TA, Marunick MT. Maxillofacial rehabilitation: prosthetic and surgical considerations; Speech, velopharyngeal function, and restoration of Soft palate defects. St. Louis: Ishiyaku EuroAmerica Inc; 1996. p. 285-324.
6. Yoshida H, Michi K, Yamashita Y, Ohno K. A comparison of surgical and prosthetic treatment for speech disorders attributable to surgically acquired soft palate defects. *J Oral Maxillofacial Surg* 1993;51(4):361-365.
7. Ragab A. Cerclage sphincter pharyngoplasty: a new technique for velopharyngeal insufficiency. *Int J Pediatr Otorhinolaryngol* 2007;71(5):793-800.
8. Hickey AJ, Salter M. Prosthetics and psychological factors in treating patients with congenital and craniofacial defects. *J Prosthet Dent* 2006;95(5):392-396.
9. McGarry TJ, Edge MJ, Gillis RE Jr, Hilsen KL, Jones RE, Shipman B, et al. Parameters of care for the American College of Prosthodontists. POC version 1. *J Prosthodont* 1996;5(1):3-70.
10. Saunders TR, Oliver NA. A speech-aid prosthesis for anterior maxillary implant-supported prostheses. *J Prosthet Dent* 1993;70(6):546-547.
11. Abreu A, Levy D, Rodriguez E, Rivera I. Oral rehabilitation of a patient with complete unilateral cleft lip and palate using an implant-retained speech-aid prosthesis: Clinical report *Cleft Palate-Craniofac J* 2007;44(6):673-677.