

CASE REPORT

Retrieval and Replacement of Fractured Zirconia Abutment

Othman Wali

ABSTRACT

Zirconia was newly introduced to implant dentistry as an abutment to enhance esthetic result. However, careful handling, is recommended to avoid failures. Mechanical complications, such as loosening or damaging of the prosthetic components of an osseointegrated implant, may occur. Fracture of zirconia abutment is not uncommon. This report describes a clinical situation involving a patient, who presented with a fractured Zirconia abutment. Upon further examination, it was determined that the abutment was fractured at the base. There was limited access and visibility in this situation since the implant was a bone-level implant. The procedure used for the removal of the fractured zirconia abutment is described in detail in this clinical report.

Keywords: Fractured zirconia abutment, Implant, Abutment screw.

How to cite this article: Wali O. Retrieval and Replacement of Fractured Zirconia Abutment. *J Orofac Res* 2014;4(4):229-233.

Source of support: Nil

Conflict of interest: None

INTRODUCTION

Dental implants are a reliable and predictable treatment for partially and completely edentulous patients. With proper treatment planning, appropriate placement, adequate prosthetic design, and proper maintenance, dental implants can achieve more success rate. However, despite high survival rates, biological and technical failures and complications may occur.

Traditionally, titanium has been used extensively as a material for implant abutments due to its excellent mechanical reliability,¹ however, the inherent gray color of titanium usually cannot be masked in situations with thin gingival biotype, giving the appearance of gingival discoloration.² Furthermore, in the event of gingival recession, exposure of the titanium abutment can be visually unpleasant.³⁻⁶ Although these restorations may

be prosthetically viable, they are often considered a failure from an esthetic viewpoint.⁷

In 1993, Prestipino and Ingber advocated aluminum oxide (alumina) as an esthetic alternative material to titanium for implant abutments.⁸ Due to alumina's favorable inherent esthetic properties, alumina abutments have shown great potential for restorations in the esthetic zone.^{8,9} To create proper gingival emergence, retention, and resistance form, early alumina abutments were prepared manually with a high-speed rotary instrument. Although the low thermal conductivity of aluminum oxide allows the abutment to be prepared safely in the mouth,⁹ manual preparation with a rotary instrument could introduce deep subsurface flaws in the ceramic abutment.¹⁰⁻¹² These flaws would act as stress concentrators, which in turn could reduce the overall strength of the material.¹⁰⁻¹² In fact, a high abutment fracture rate (7%) for single implant alumina abutments has been reported.¹³

Similar to aluminum oxide, zirconium oxide as a framework material may enhance esthetics due to its white color. Besides possessing high flexural strength zirconia also exhibits good tissue compatibility, nontoxicity, and intrasulcular adaptability, making it a widely used esthetic replacement material for implant abutments.^{8,14-21} Nevertheless, for a material to be used predictably as an implant abutment, in addition to its physical properties, the significance of abutment design, pattern of stress distribution, and degradation of material properties as a result of fatigue must also be considered.²¹

Zirconia has recently attracted significant interest because of its superior fracture resistance compared to alumina,²⁵ its superior esthetic properties,²²⁻²⁴ and its improved biocompatibility compared to metal abutments.^{26,27} Shear forces produced during mastication may create bending movements and high stresses at the abutment/implant interface.²⁸ Therefore, the wall thickness of the zirconia abutment should not be reduced below 0.5 to 0.7 mm.²¹ In addition, because there is only a limited degree of rotational freedom on the abutment/screw assembly interface, any misfit,^{29,30} can generate wedging forces on the inner walls of the ceramic abutment accentuated by the torque application to the fixation screw.²¹ Modification of the zirconia abutment is possible using high-speed preparation with copious irrigation,²⁵ but similar to alumina, is susceptible to the introduction of

Vice Dean (Dental Program) and Assistant Professor

Department of Periodontology, IBN Sina National College
Jeddah, Saudi Arabia

Corresponding Author: Othman Wali, Vice Dean (Dental Program) and Assistant Professor, Department of Periodontology, IBN Sina National College Jeddah, Saudi Arabia, Phone: 00966555710569, e-mail: owali@ibnsina.edu.sa

deep surface flaws.^{12,31,32} Furthermore, the low temperature degradation of zirconia, especially in the presence of moisture (water, vapor, body fluid, steam sterilization) causes its spontaneous transformation from a tetragonal phase into monoclinic phase, thereby decreasing the overall strength of the material.³³⁻³⁵ The aforementioned factors can individually or collectively cause the fracture of a zirconia abutment.

Zirconia abutments can be broadly classified into 2 categories: 1-piece zirconia abutments, where the entire abutment is made of zirconia,³⁶ or 2-piece zirconia abutments consisting of titanium or a titanium alloy element that engages with the dental implant and a transmucosal zirconia element.²⁴ The mode of failure of the zirconia abutments was fracture at the apical portion (thinnest portion) of the abutment without damage or plastic deformation of the abutment screw or implant and was consistent with results reported by Mitsias et al and Nothdruff et al.³⁷

A detailed understanding of implant systems and an exact diagnosis are key elements to resolve these complications. There are two fundamental connections for the implant-abutment interface: external and internal connections. The internal connection involves a tight fit between the abutment and the implant, with part of the abutment engaging the internal aspect of the implant. However, in an external connection system, the implant engages into the internal aspect of the abutment. Knowledge and understanding of these connections can help guide clinicians in the appropriate use of available retrieval kits.

There are a few precautions that a clinician can take to prevent stripping and fracturing of abutments. A comprehensive diagnostic examination should be performed to identify parafunctional habits, such as bruxism, which may contribute to implant and/or abutment fracture. When inserting the abutment, one should become familiar with the torque wrench and its components so that

the specified handle can be used to apply appropriate torque. The use of a manufacturer-specified driver and torque wrench to tighten the abutment screw is also important to prevent stripping of abutments. In addition, it is recommended that the clinician always ensure that the abutment screw head is free of debris, to allow the driver to fully engage the abutment screw.

Finally, one must ensure that the restoration is free of premature occlusal contacts. Failure to follow precautionary measures can result in mechanical complications.

This clinical report presents a situation in which a fractured zirconia abutment screw was successfully retrieved using an orthodontic stainless steel wire. A successful method for retrieval of a fractured abutment and the subsequent restoration of the implant with new definitive crown is described.

CLINICAL REPORT

A 60-year-old male patient presented with fractured upper left central incisor cervically in a very strange way, two oblique lines meet coronally (Fig. 1). Tooth was endodontically treated and restored prosthodontically with a temporary crown. But, tooth could not withstand those treatments due to unfavorable crown root ratio (Fig. 2). So, Patient was advised to extract and replaced by implant PrimaConnex[®] Tapered Implant, TC RD 4.1 × 13 with immediate nonfunctional loading temporary crown. After 3 months, Zirconia abutment was inserted and porcelain crown with Zirconia base was cemented (Fig. 3).

Two years later, patient came with fallen down crown for cementation. Unfortunately, He bit on very hard subject resulted in fractured Zirconia abutment close to its base. Clinical examination revealed a fractured zirconia abutment at its apical part (Fig. 4). Clinical access and visibility were compromised (Fig. 5). A radiograph was made to help determine the exact location of the fracture part (Fig. 6). Access to the abutment screw

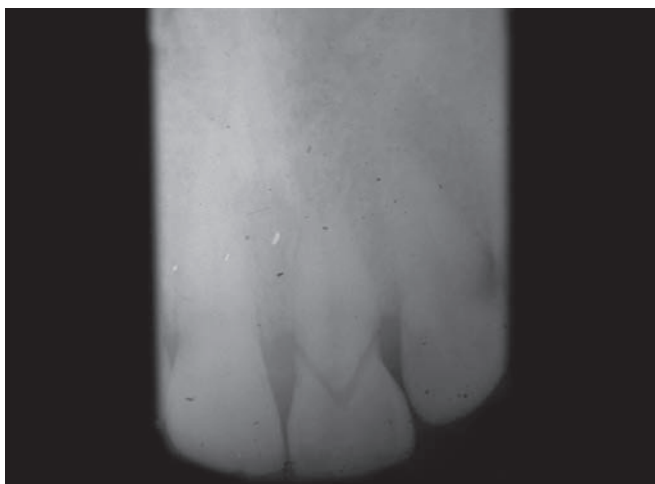


Fig. 1: Two oblique line fracture in 21

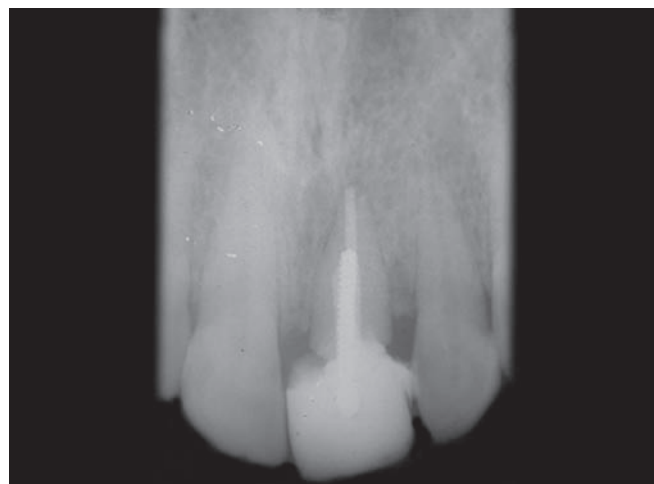

Fig. 2: Crown fracture seen in 21

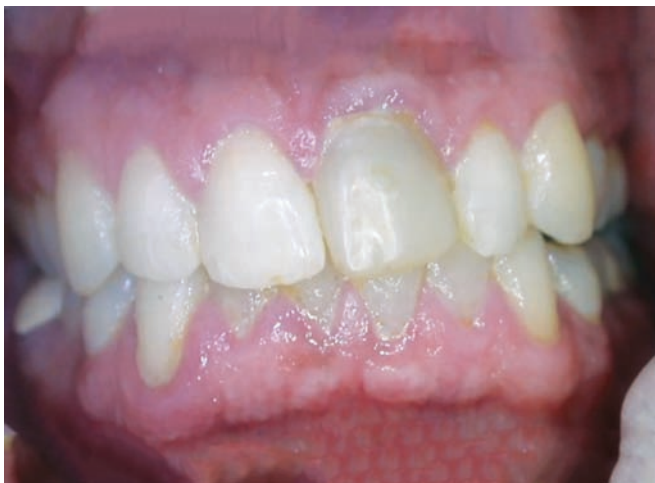

Fig. 3: Zirconia abutment with porcelain crown

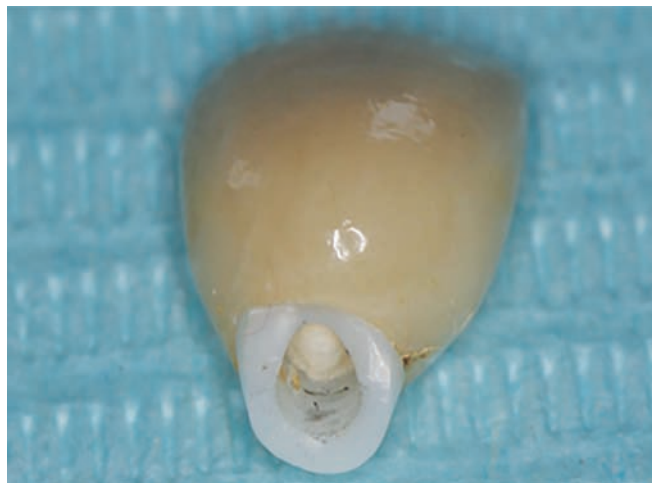

Fig. 4: Interim prosthesis and fractured zirconia abutment

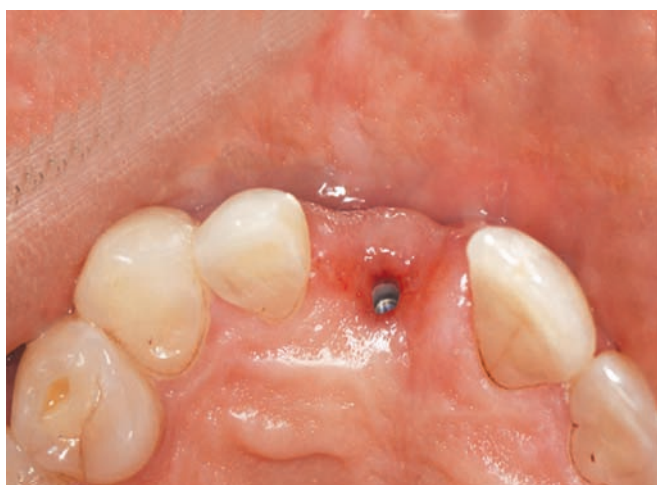

Fig. 5: Occlusal view of the fractured zirconia abutment

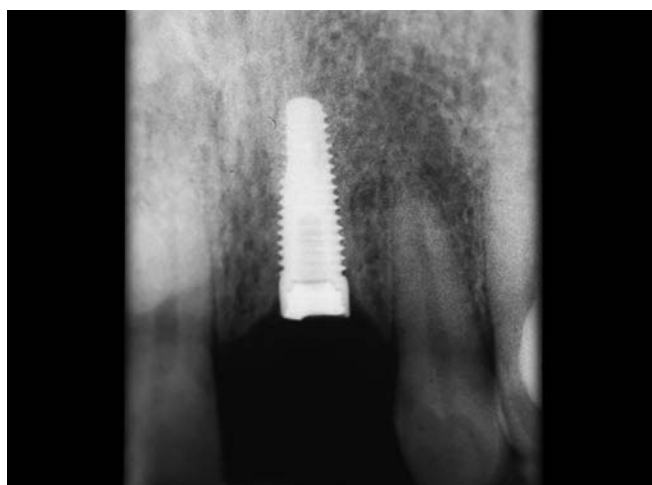


Fig. 6: Periapical radiograph displaying bone level implant and fractured zirconium abutment




Fig. 7: Orthodontic stainless steel wire (0.016") with the hook and bend

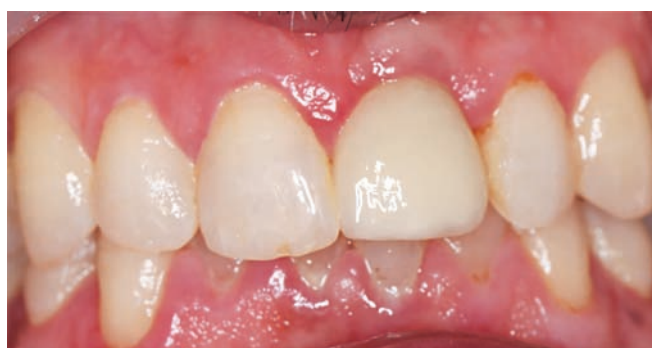

Fig. 8: New porcelain crown

had to be achieved to successfully loosen and remove the abutment without raising the flap. To remove the fractured abutment, orthodontic stainless steel wire (0.016") is used to engage the apical borders of abutment to remove it. Loop was made at the end of orthodontic stainless steel wire which was slightly bigger than head

of the abutment screw and also bend was given in middle third of the wire to get a better accessibility (Fig. 7). Different angulations were tried to engage the apical portion of the abutment. Efforts were made to minimize damage to the implant head.

New final impression and new crown has been delivered (Fig. 8). The prognosis and patient satisfaction is really high. This method is very simple and easy for routine application because this procedure is not time-consuming and involves very less risk of damaging the

threads inside the implant. The success achieved with the repair system is predictable.

CONCLUSION

Minimal invasive procedure was performed without surgical intervention to retrieve fractured part and to achieve esthetic optional result. Although management of fractured implant components can at times lead to novel innovation, it is also strenuous, time consuming, and often discouraging. To avoid being in such a predicament, it is important to understand the properties and limitations of the materials used to make the components. The incidence of ceramic implant abutment fracture can be minimized by proper case selection (anterior area *vs* posterior, proper occlusal scheme, and avoiding situations with unfavorable parafunctional habits), using copious irrigation when modifying the abutment with a high-speed rotary instrument, ensuring complete abutment seating radiographically prior to applying torque to the abutment screw, maintaining a minimal abutment thickness of 0.5 mm, and using other materials, such as titanium or a metal alloy when the thickness requirement is not met.

REFERENCES

- Andersson B, Ödman P, Lindvall AM, et al. Cemented single crowns on osseointegrated implants after 5 years: results from a prospective study on CeraOne. *Int J Prosthodont* 1998;11(3):212-218.
- Kan JY, Morimoto T, Rungcharassaeng K, et al. Gingival biotype assessment in the esthetic zone: visual versus direct measurement. *Int J Periodont Restorat Dent* 2010;30(3):237-243.
- Blatz MB, Bergler M, Holst S, et al. Zirconia abutments for single-tooth implants—rationale and clinical guidelines. *J Oral Maxillofac Surg* 2009;67(3):74-81.
- Sailer I, Sailer T, Stawarczyk B, et al. In vitro study of the influence of the type of connection on the fracture load of zirconia abutments with internal and external implant-abutment connections. *Int J Oral Maxillofac Implants* 2009;24(5):850-858.
- Prestipino V, Ingber A. All-ceramic implant abutments: esthetic indications. *J Esthet Dent* 1996;8(6):255-262.
- Jung RE, Sailer I, Hämmerle CHF, et al. In vitro color changes of soft tissues caused by restorative materials. *Int J Periodont Restorat Dent* 2007;27(3):251-257.
- Fühauser R, Florescu D, Benesch T, et al. Evaluation of soft tissue around single tooth implant crowns: the pink esthetic score. *Clin Oral Implants Res* 2005;16(6):639-644.
- Prestipino V, Ingber A. Esthetic high strength implant abutments—Part I. *J Esthet Dent* 1993;5(1):29-36.
- Prestipino V, Ingber A. Esthetic high strength implant abutments—Part II. *J Esthet Dent* 1993;8(6):255-262.
- Blue DS, Griggs JA, Woody RD, et al. Effects of bur abrasive particle size and abutment composition on preparation of ceramic implant abutments. *J Prosthet Dent* 2003;90(3):247-254.
- Luthardt RG, Holzhueter M, Sandkuhl O, et al. Reliability and properties of ground Y-TZP-zirconia ceramics. *J Dent Res* 2002;81(7):487-491.
- Kosmac T, Oblak C, Jevnikar P, et al. The effect of surface grinding and sandblasting on flexural strength and reliability of Y-TZP zirconia ceramic. *Dent Mater* 1999;15(6):426-433.
- Andersson B, Taylor A, Lang BR, et al. Alumina ceramic implant abutments used for single-tooth replacement: a prospective 1- to 3-year multicenter study. *Int J Prosthodont* 2001;14(5):432-438.
- Yildirim M, Edelhoff D, Hanisch O, et al. Ceramic abutments—a new era in achieving optimal esthetics in implant dentistry. *Int J Periodont Restorat Dent* 2000;20(1):81-91.
- Heydecke G, Sierraalta M, Razzoog MF. Evolution and use of aluminum oxide single-tooth implant abutments: a short review and presentation of two cases. *Int J Prosthodont* 2002;15(5):488-493.
- Abrahamsson I, Berglundh T, Glantz PO, et al. The mucosal attachment at different abutments. *J Clin Period* 1998;25(9):721-727.
- Blatz MB, Sadan A, Kern M. Ceramic restorations. *Compend Contin Educ* 2004;25:306-312.
- Blatz MB. Long-term clinical success of all-ceramic posterior restorations. *Quintessence Int* 2002;33(6):415-426.
- Sadan A, Blatz MB, Lang B. Clinical considerations for densely sintered alumina and zirconia restorations—Part I. *Int J Period Rest Dent* 2005;25(3):213-219.
- Sadan A, Blatz MB, Lang B. Clinical considerations for densely sintered alumina and zirconia restorations—Part 2. *Int J Period Res Dent* 2005;25(4):343-349.
- Aboushelib MN, Salameh Z. Zirconia implant abutment fracture: clinical case reports and precautions for use. *Int J Prosthodont* 2009;22(6):616-619.
- Tan PL, Dunne JT. An esthetic comparison of a metal ceramic crown and cast metal abutment with an all-ceramic crown and zirconia abutment: a clinical report. *J Prosthet Dent* 2004;91(3):215-217.
- Glauser R, Sailer I, Wohlwend A, Studer S, Schibli M, Scharer P. Experimental zirconia abutments for implant-supported single-tooth restorations in esthetically demanding regions: 4-years results of a prospective clinical study. *Int J Prosthodont* 2004;17(3):285-290.
- Brodbeck U. The ZiReal Post: a new ceramic implant abutment. *J Esthet Restor Dent* 2003;15(1):10-23.
- Adatia ND, Bayne SC, Cooper LF, Thompson JY. Fracture resistance of yttria-stabilized zirconia dental implant abutments. *J Prosthodont* 2009;18(1):17-22.
- Kerstein RB, Radke J. A comparison of fabrication precision and mechanical reliability of 2 zirconia implant abutments. *Int J Oral Maxillofac Implants* 2008;23(6):1029-1036.
- Yildirim M, Fischer H, Marx R, Edelhoff D. In vivo fracture resistance of implant-supported all-ceramic restorations. *J Prosthet Dent* 2003;90(4):325-331.
- Rangert B, Krogh PHJ, Langer B, et al. Bending overload and implant fracture: a retrospective clinical analysis. *Int J Oral Maxillofac Implants* 1995;10(3):326-334.
- Vigolo P, Fonzi F, Majzoub Z, et al. An in vitro evaluation of ZiReal abutments with hexagonal connection: in original state and following abutment preparation. *Int J Oral Maxillofac Implants* 2005;20(1):108-114.
- Vigolo P, Fonzi F, Majzoub Z, et al. An in vitro evaluation of titanium, zirconia, and alumina procera abutments

- with hexagonal connection. *Int J Oral Maxillofac Implants* 2006;21(4):575-580.
31. Luthardt RG, Holzhuter MS, Rudolph H, et al. CAD/CAM-machining effects on Y-TZP zirconia. *Dent Mater* 2004;20(7):655-662.
 32. Kosmac T, Oblak C, Jevnikar P, et al. Strength and reliability of surface treated Y-TZP dental ceramics. *J Biomed Mater Res* 2000;53(4):304-313.
 33. Sato T, Shimada M. Transformation of yttria-doped tetragonal ZrO₂ polycrystals by annealing in water. *J Amer Ceram Soc* 1985;86:356-359.
 34. Swab JJ. Low temperature degradation of Y-TZP materials. *J Mater Sci* 1991;26:6706-6714.
 35. Piconi C, Maccauro G. Zirconia as a ceramic biomaterial. *Biomaterials* 1999;20(1):1-25.
 36. Aramouni P, Zebouni E, Tashkandi E, Dib S, Salameh Z, Almas K. Fracture resistance and failure location of zirconium and metallic implant abutments. *J Contemp Dent Pract* 2008;9(7):41-48.
 37. Mitsias ME, Silva NR, Pines M, Stappert C, Thompson VP. Reliability and fatigue damage modes of zirconia and titanium abutments. *Int J Prosthodont* 2010;23(1):56-59.