

## CASE REPORT

# An Unusual Foreign Body in the Maxillary Antrum: A Case Report and Pertinent Review of Literature

<sup>1</sup>Amit S Date, <sup>2</sup>Mukul N Padhye, <sup>3</sup>Vaibhav D Shah, <sup>4</sup>Mukund J Vandekar

## ABSTRACT

Maxillary sinus is the largest of the paranasal sinuses and occupies the body of Maxilla. It is pyramidal in shape with base toward lateral wall of nose and apex directed laterally into the zygomatic process. Its roof is formed by the floor of the orbit and grooved by infraorbital nerve. Foreign bodies may present in the paranasal sinuses through a variety of traumatic and iatrogenic events. We describe a case where a sharp foreign body penetrated into the maxillary sinus. We used the open surgical approach, for the removal of sinus foreign body.

**Keywords:** Foreign body, Maxillary sinus, Surgery.

**How to cite this article:** Date AS, Padhye MN, Shah VD, Vandekar MJ. An Unusual Foreign Body in the Maxillary Antrum: A Case Report and Pertinent Review of Literature. *J Orofac Res* 2014;4(2):127-129.

**Source of support:** Nil

**Conflict of interest:** None

## INTRODUCTION

Various instances have been reported earlier citing cases of foreign bodies like tooth, dental amalgam, pellets, etc. in the maxillary sinus. The objective of this case presentation is to report an unusual metallic foreign body, an abrasive disk of irregular shape in the maxillary sinus and the open surgical technique essential to remove it.

## PERTINENT REVIEW OF LITERATURE

Foreign bodies in the interior of the maxillary sinus is an unusual clinical entity. Most cases of maxillary sinus foreign bodies in literature are related to iatrogenic dental manipulation.<sup>5</sup> Foreign bodies of very different nature, such as fillings, tooth roots, fragments of broken parts, or different types of implants, are introduced into the maxillary sinus by different mechanisms, such as apical migration of fragments of

fillings or accidental rough handling. Far rarer of maxillary sinus foreign bodies are nondental origin. Foreign bodies may be introduced willingly by the patient or accidentally usually through an oro-antral fistula.<sup>6</sup> Only a few cases of nondental paranasal sinus foreign bodies have been reported in the literature. It is difficult to estimate their frequency because of the rarity of the entity, and because of the small numbers of series published. Foreign bodies produce chronic physical and chemical irritation of the mucosa, leading to a degree of ciliary insufficiency and secondary infection.<sup>7</sup> Because foreign bodies can cause irritation of the mucosa that can be concluded to sinusitis, the removal of all foreign bodies is generally recommended, even when they do not produce symptoms.<sup>8</sup> A foreign body can be removed with different techniques depending on the size and location of it. The most common technique is endoscopic sinonasal surgery allowing the removal of most foreign bodies via a wide endonasal meatotomy.<sup>9</sup> When extraction is not possible by the endonasal approach, it can be conducted through an external approach by oral antrostomy or a combined approach of endonasal meatotomy and oral antrostomy.<sup>10</sup>

## CASE REPORT

A 23-year-old man, working in a factory came to the Oral and Maxillofacial Department, Pad. Dr DY Patil College, Nerul with complaint of pain in the left cheek. When he came to the department the external wound on the left cheek had been sutured at another hospital. He gave history of trauma at his work place while sharpening instruments 3 days back (Fig. 1).

On examination, an oblique sutured lacerated wound, about 7 cm in length, was seen on the left cheek extending till the lower lip. Intraorally there was a small laceration about a centimeter in length in the vestibule adjacent to the canine. Owing to the history narrated by the patient, we suspected a foreign body to be the cause of his pain. We made him undergo a Computerized Tomography scan of the facial bones which showed that a foreign body had penetrated the left maxillary sinus (Fig. 2).

The following procedure was carried out under general anesthesia. The patient was intubated, then scrubbed and draped in usual surgical manner. LA was administered at operative site. Extraoral sutures were removed and existing wound opening was used to gain access to the sinus. Sinus

<sup>1</sup>Reader, <sup>2</sup>Professor, <sup>3</sup>Lecturer, <sup>4</sup>Resident

<sup>1-4</sup>Department of Oral Surgery, Dr DY Patil Dental College and Hospital, Navi Mumbai, Maharashtra, India

**Corresponding Author:** Amit S Date, Reader, Department of Oral Surgery, Dr DY Patil Dental College and Hospital Navi Mumbai, Maharashtra, India, Phone: 02226169768 e-mail: asdate2001@yahoo.co.in

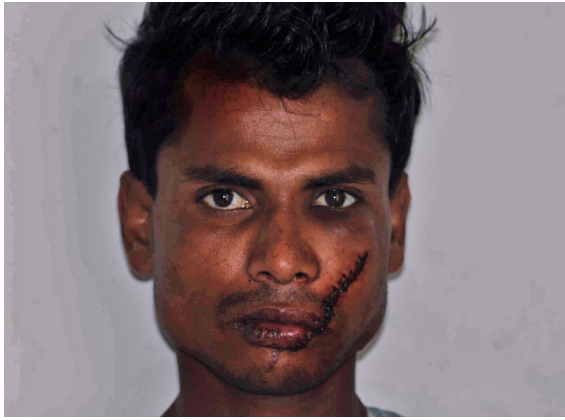

Fig. 1: Preoperative view

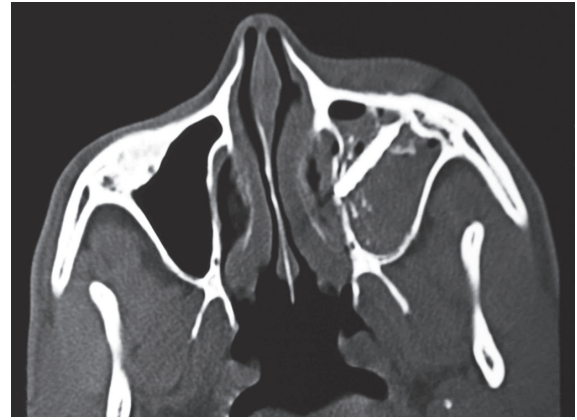


Fig. 2: Preoperative axial scan

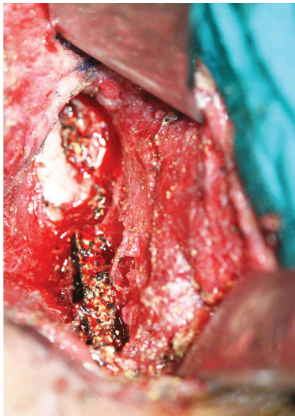


Fig. 3: Intraoperative view



Fig. 4: Recovered foreign body

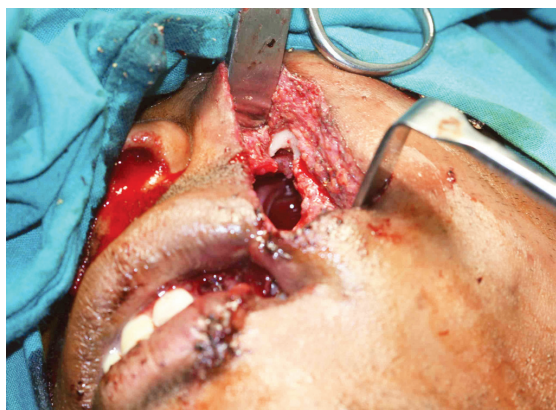

Fig. 5: Defect after removal of foreign body

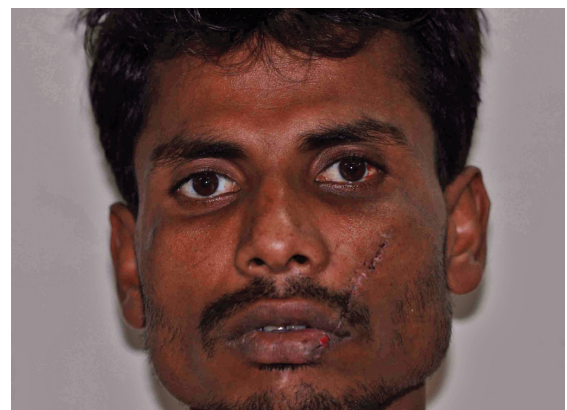


Fig. 6: Postoperative frontal view

was exposed and explored. After removal of clots and granulation tissue a foreign body, an abrasive disk was found impacted in left maxillary sinus (Figs 3 to 5).

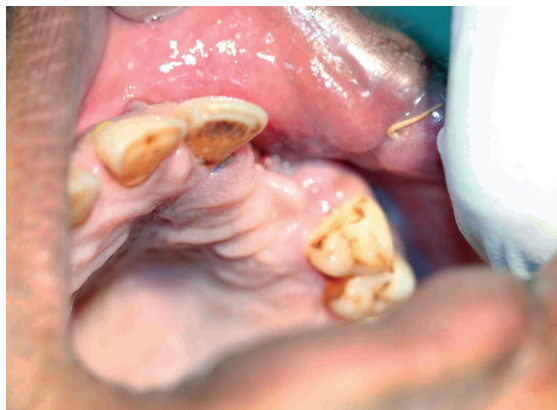Removal was difficult as the foreign body was tightly impacted and was not easy to grasp with regular surgical instruments. Only repeated rocking movements and the use of leverage around the edges allowed the foreign body to come out. Following removal, the hemorrhage was controlled with pressure pack. Nasal antrostomy was done and the sinus was packed with a medicated ribbon gauze pack. Intraorally laceration was closed using 3-0 vicryl sutures and extraoral closure was achieved giving sutures in layers.

3-0 vicryl sutures subcutaneously and 5-0 nylon sutures on skin were given.

The postoperative period was uneventful and patient was discharged after 2 days on antibiotics. Follow-up was done for 6 months, patient did not show any symptoms suggestive of wound infection or sinusitis (Figs 6 and 7).

## DISCUSSION

Foreign bodies in the paranasal sinuses are not common.<sup>1</sup> Maxillary sinus foreign bodies account for about 50% of the foreign bodies in the paranasal sinuses. They can be classified as either traumatic or iatrogenic.<sup>2</sup> Traumatic foreign



**Fig. 7:** Postoperative intraoral view

bodies include air gun pellets, pieces of glass, stones, wood, while iatrogenic foreign bodies include whole teeth, roots of teeth, dental cement, pieces of broken forceps, impression paste, gutta-percha, etc.

Metallic foreign bodies have been associated with maxillary sinus, and when the metal is lead there is an increase risk of lead poisoning, particularly in children.<sup>3</sup>

The routes of entry are usually

- a. The lower eyelid
- b. The lateral wall of the nose
- c. The cheek
- d. The mouth.

Occasionally the site of entry may be quite inconspicuous.<sup>4</sup>

In the present case, we believe that an abrasive disk could have slipped from his hand while working on a lathe and a piece could have bounced off the lathe at high speed toward his cheek and got lodged in the maxillary antrum.

## CONCLUSION

Foreign bodies in the paranasal sinuses especially of traumatic origin must be removed surgically, even when they

are asymptomatic. This is necessary to prevent infection and development of chronic maxillary sinusitis.

Computer tomography scans allows us to precisely diagnose and locate the foreign object. In addition associated bony damage is also delineated. Failure to do so can lead to chronic pain, sinusitis and fistula formation.

## REFERENCES

1. Sugiura N, Ochi K, Komatsuzaki Y. Endoscopic extraction of a foreign body from the maxillary sinus. *Otolaryngology: Head and Neck Surgery* 2004;130(2):279-280.
2. Dodson K, Bridges MA, Evan R. Endoscopic transnasal management of intracranial foreign bodies. *Archives of otolaryngology- Head and Neck Surgery* 2004;130(8):985-988.
3. Brimmeyer G. On late sequelae of metallic foreign bodies in the region of the paranasal sinuses. *Laryngol Rhinol Otol* 1963 Nov; 42:778-785.
4. Macan D, Cabov T, Kobler P, et al. Inflammatory reaction to foreign body (amalgam) in the maxillary sinus misdiagnosed as an ethmoid tumour. *Dentomaxillofac Radiol* 2006 July; 35(4):303-306.
5. Liston PN, Walters RF. Foreign bodies in the maxillary antrum: a case report. *Australian Dent J* 2002;47(4):344-346.
6. Lima M, Moreira CA. 34 Self-inflicted foreign bodies in the maxillary sinus. *Brazilian J Otorhinolaryngol* 2008;74(6): 948.
7. Pagella F, Emanuelli E, Castelnuovo P. Endoscopic extraction of a metal foreign body from the maxillary sinus, *Laryngoscope* 1999;109(2):339-342.
8. Mehra P, Murad H. Maxillary sinus disease of odontogenic Origin-Otolaryngologic Clinics of North America 2004;37(2): 347-364.
9. Tingsgaard PK, Larsen PL. Chronic unilateral maxillary sinusitis caused by foreign bodies in the maxillary sinus. *Ugeskr Laeger* 1997 July;159(7):4402-4404.
10. Friedlich J, Rittenberg BN. Endoscopically assisted Caldwell-Luc procedure for removal of a foreign body from the maxillary sinus. *J Canadian Dent Assoc* 2005;71(3): 200-201.