

CASE REPORT

Induced Apical Closure of Nonvital Immature Root Apices with MTA

¹Shikha Singh, ²Sweta Singh, ³Swapna Munaga, ⁴Gautam Singh Maurya

ABSTRACT

Endodontics is a specialty which is very receptive to new ideas and concepts. Management of open apex is a challenge to the endodontist.

The treatment of choice for necrotic teeth is apexification, which is induction of apical closure to produce more favorable conditions for conventional root canal filling. The most commonly advocated medicament is calcium hydroxide, although recently considerable interest has been expressed in the use of mineral trioxide aggregate. Introduction of techniques for one-visit apexification provide an alternative treatment option in these cases.

Research, published studies, and clinical results support this material, and have served to increase the expectation that nonsurgical treatment success is both possible and attainable.

This paper highlights a case reports for apexification using mineral trioxide aggregate.

Keywords: Calcium hydroxide, Mineral trioxide aggregate, Apexification.

How to cite this article: Singh S, Singh S, Munaga S, Maurya GS. Induced Apical Closure of Nonvital Immature Root Apices with MTA. J Orofac Res 2014;4(1):46-49.

Source of support: Nil

Conflict of interest: None

INTRODUCTION

The completion of root development and closure of the apex occurs up to 3 years after eruption of the tooth.¹ The treatment of pulpal injury during this period provides a significant challenge for the clinician. Depending upon the

vitality of the affected pulp, two approaches are possible – apexogenesis or apexification.²

If exposure due to trauma or caries occurs, the pulp undergoes necrosis, dentin formation ceases and root growth is arrested. The resultant immature root will have an open apex which is also called as Blunder Buss Canal.³

In such cases, success is related to accurate diagnosis and a full understanding of the biological processes to be facilitated by the treatment.

Complications associated with open apex³ are due to large apical diameter and smaller coronal canal diameter debridement is difficult. Also, lack of apical stop makes obturation difficult. The thin root canal walls become prone to fracture.

Mineral trioxide aggregate (MTA) has been described as a good material for this procedure owing to its good canal sealing property, biocompatibility and ability to promote dental pulp and periradicular tissue regeneration.⁴⁻⁷

In such cases, success is related to accurate diagnosis and a full understanding of the biological processes to be facilitated by the treatment.

CASE REPORTS

Case 1

A 21 years male patient referred to the department with the chief complaint of carious teeth in the upper right back region of the jaw. Clinical examination revealed that upper right maxillary second premolar 15 was grossly decayed; tooth was not tender on percussion. Vitality test confirmed pulpal necrosis with the same tooth. Patient gave a history of long standing decay of tooth. Radiographic examination revealed a radiolucency in the apical region with immature apex (Fig. 1).

Treatment Procedure

Access opening followed by conventional biomechanical preparation was done with 15.3% sodium hypochlorite and saline were used as irrigants. Working length determination was done (Fig. 2). Canal was dried using paper points and mineral trioxide aggregate was introduced into the canal using MTA Denkens carrier to form MTA plug of 3 to 4 mm length. Care was taken not to extrude MTA into periapical area (Fig. 3). A moist cotton was placed into the canal for 24 hours, as MTA requires moist condition for setting.

^{1,2}Senior Lecturer, ³Reader, ⁴Postgraduate Student

^{1,3}Department of Conservative Dentistry and Endodontics
People's College of Dental Sciences, Bhopal, Madhya Pradesh, India

²Department of Orthodontics and Dentofacial Orthopedics
People's College of Dental Sciences, Bhopal, Madhya Pradesh, India

⁴Department of Orthodontics and Dentofacial Orthopedics
Modern Dental College and Research Centre, Indore, Madhya Pradesh, India

Corresponding Author: Shikha Singh, Senior Lecturer
Department of Conservative Dentistry and Endodontics
People's College of Dental Sciences, Bhanpur, Bhopal-462037
Madhya Pradesh, India, Phone: 7697010076, e-mail:
dr.shikhasingh_sdc@gmail.com

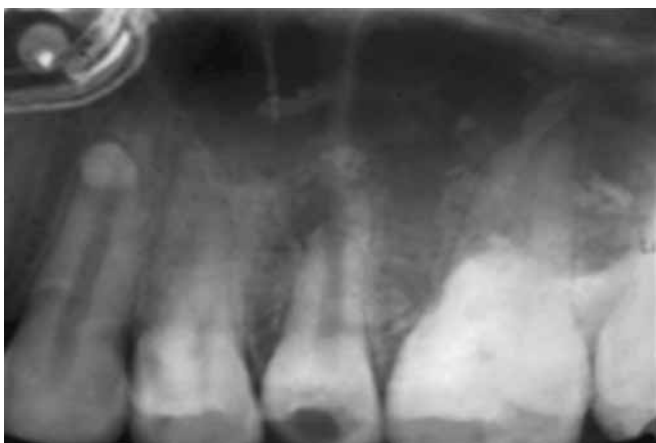

Fig. 1: Preoperative radiograph (case 1)

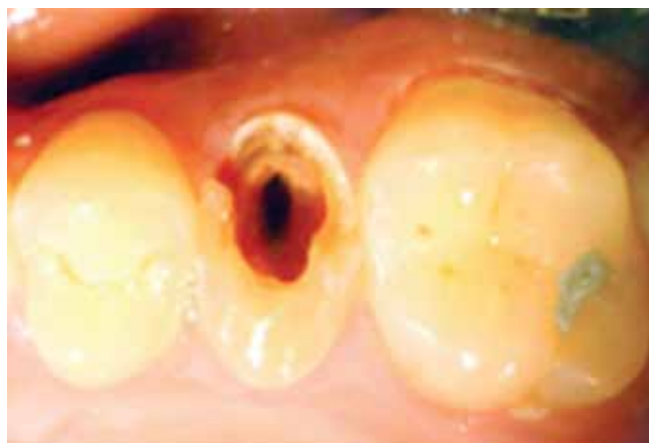

Fig. 2: After access opening (case 1)

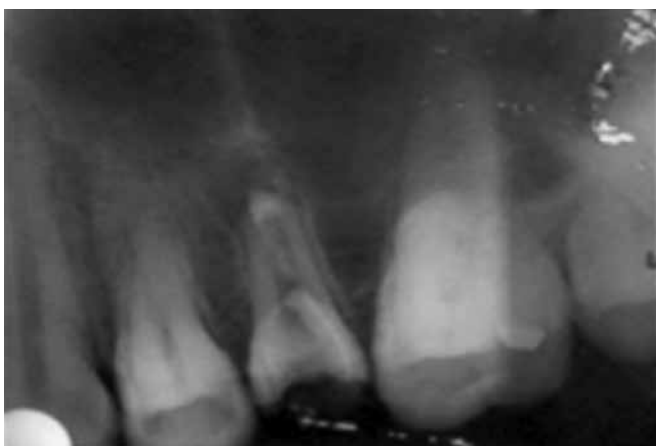

Fig. 3: Apical plug placement with MTA (case 1)

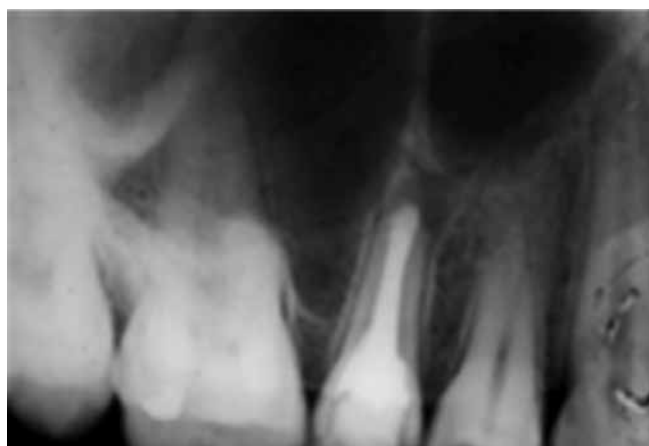

Fig. 4: After obturation (case 1)

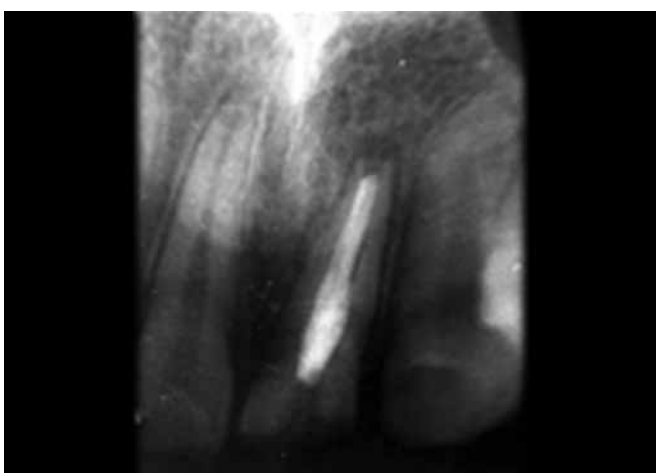


Fig. 5: Preoperative radiograph (case 2)

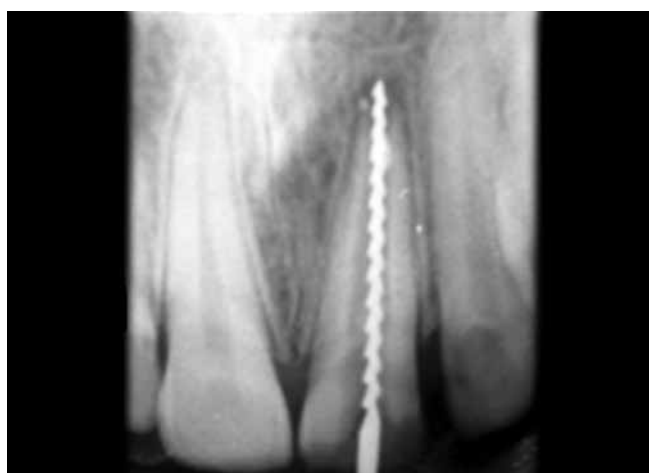

Fig. 6: Determination of working length (case 2)

Back filling of remaining canal was done with Obtura II after MTA apical barrier formation was confirmed (Fig. 4).

Case 2

A 22 years male patient referred to department with the chief complaint of fractured upper front teeth. Clinical examination revealed fracture of maxillary left central incisor 21. Patient gave a history of trauma in the same region 10 years back and history of root canal treatment in association with 21.

Radiographic examination revealed root canal filling with 21 and periapical radiolucency suggestive of peripical lesion with same (Fig. 5).

Treatment Procedure

Rubber dam application was done and access to 11 was regained and previous root filling material from all three teeth was removed. Three percent sodium hypochloride, 2% chlorhexidine digluconate and saline were used as irrigants.

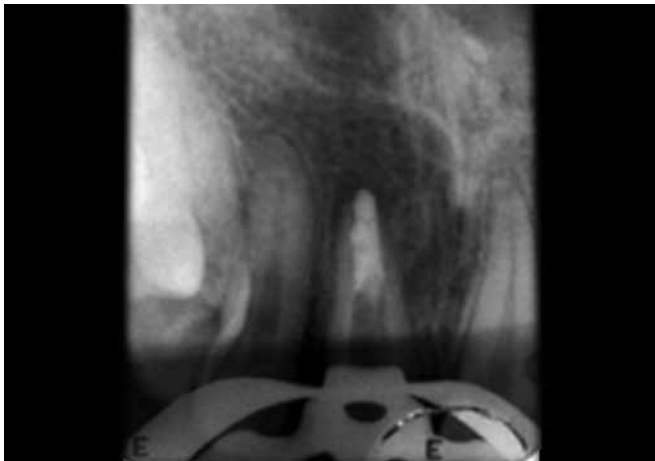


Fig. 7: Apical plug placement with MTA (case 2)

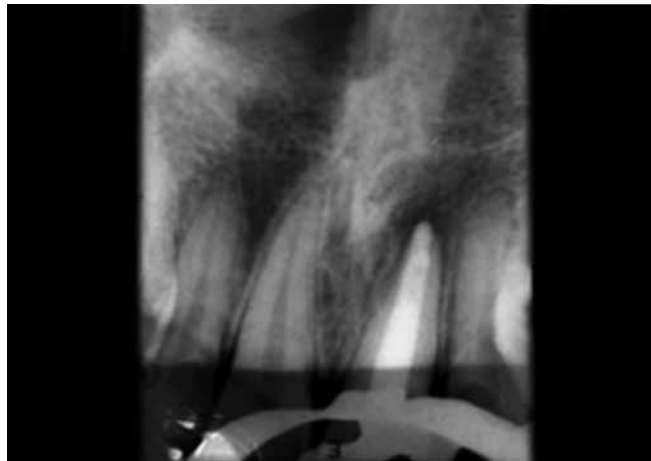


Fig. 8: Postoperative radiograph after obturation (case 2)

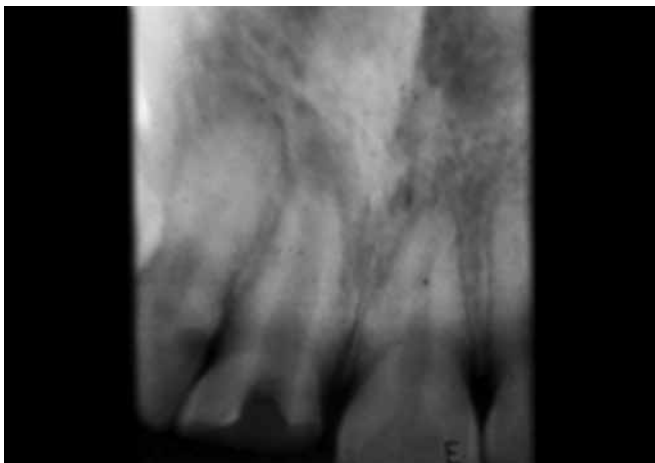


Fig. 9: Preoperative radiograph showing open apex (case 3)

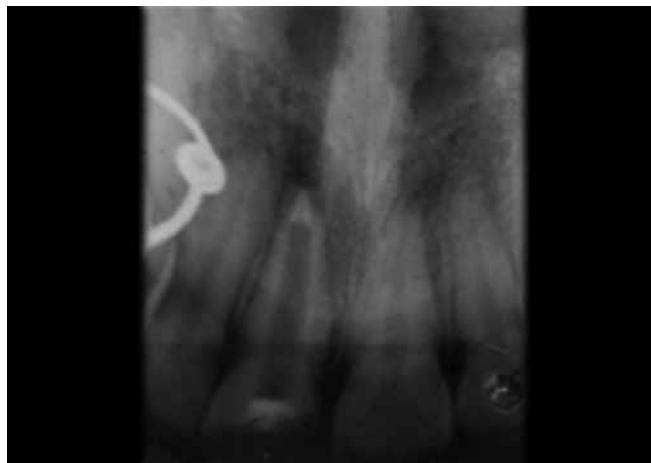

Fig. 10: Placement of apical plug (case 3)

Working length determination was done (Fig. 6). Calcium hydroxide (CH) was placed in all the canal as intracanal medicament, and patient was recalled after 3 weeks for review. Canal was dried using paper points. The MTA placement and obturation (Figs 7 and 8) was done as in case 1.

Case 3

A 20 years old female patient referred with the chief complaint of discolored upper front tooth. Clinical examination revealed fracture of maxillary right central incisor 11. Patient gave a history of trauma in the same region 4 years back in association with 11. Radiographic examination revealed periapical radiolucency (Fig. 9).

Treatment Procedure

Access opening followed by conventional biomechanical preparation was done with 5.3% sodium hypochlorite and saline. Working length determination was done. Calcium hydroxide was placed in all the canal as intracanal medicament and patient was recalled after 3 weeks for review. Canal was dried using paper points. MTA placement and obturation (Figs 10 and 11) was done like in case 1.

DISCUSSION

A large number of different apical configurations can result if an immature tooth with an open apex is traumatized. Continued root development, apical doming, in-growth of bone, and aberrant root formation have all been reported. Repair appears to be more related to the creation of an environment conducive to repair rather than the type of medicament used.

Once pulp necrosis and infection has been established, apexification procedures need to be initiated. The access cavity preparation should be made large enough to encompass the larger than normal underlying pulp and to allow access of endodontic instruments to the divergent walls. Cleaning should be carried out with great care using copious amounts of irrigant, such as sodium hypochlorite. Reliance on irrigation to remove debris rather than filing is important, as the canal walls in the apical region are thin and fragile.⁸

Traditionally, the approach has been to use CH to induce apexification after disinfection of the root canals in the conventional manner.

The disadvantages of traditional, long-term CH therapy include variability in treatment time, unpredictability of formation of an apical seal, difficulty in following up patients,

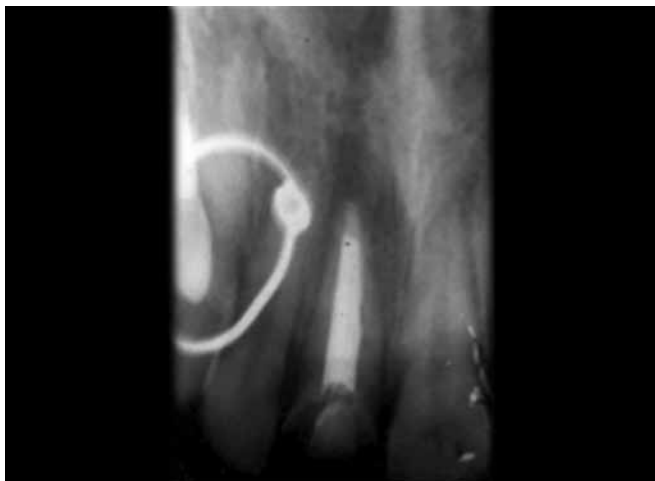


Fig. 11: After obturation (case 3)

and delayed treatment. An alternative to CH therapy is placement of an apical plug.⁹

The advantages of using an apical plug include requirement for fewer appointments to complete the treatment, more predictable apical barrier formation, and reduced need for patient follow-up appointments.⁸

Recent material like MTA is a promising material and plays an important role in healing and sealing of root canal

and, thus, saving patient from psychological trauma of surgical procedures.

REFERENCES

1. Bhasker SN. Orban's oral histology and embryology, 11th ed. St. Louis: Mosby-Year Book; 1991.
2. American Association of Endodontists. Glossary of endodontic terms. 7th ed. Chicago: American Association of Endodontists; 2003.
3. Kandos TB. Mechanism of tooth eruption. *BDJ* 1996 Aug; 181(3):91-95.
4. Torabinejad M, Watson TF, Pitt FTR. The sealing ability of a mineral trioxide aggregate as a retrograde root filling material. *J Endodon* 1993;19:591-595.
5. Torabinejad M, Chivian N. Clinical applications of mineral trioxide aggregate. *J Endodon* 1999;25:197-205.
6. Simon F, Rilliard A, Berdal, Machtou P. The use of mineral trioxide aggregate in one-visit apexification treatment: a prospective study. *International Endodontic Journal* 2007;40(3):186-197.
7. Camilleri J, Pitt Ford TR. Mineral trioxide aggregate: a review of the constituents and biological properties of the material. *International Endodontic Journal* 39(10):747-754.
8. Moule AJ. The endodontic management of traumatized permanent anterior teeth: a review. *Australian Dent J Supplement* 2007;52:(1 Suppl):S122-S137.
9. Shabahang S. Treatment options: apexogenesis and apexification. *J Endod* 2013;39:26-29.