

CASE REPORT

Pleomorphic Adenoma of Minor Salivary Gland in Parapharyngeal Space

Leena Jain, Sadat Qureshi, Ashish Maurya, Shalini Jadia

ABSTRACT

A case of pleomorphic adenoma of minor salivary gland in parapharyngeal space is being reported as the incidence of pleomorphic adenoma of minor salivary gland in parapharyngeal space is of very rare occurrence. Transpalatal complete excision of tumor was done under general anesthesia.

Keywords: Pleomorphic adenoma, Minor salivary gland, Parapharyngeal space.

How to cite this article: Jain L, Qureshi S, Maurya A, Jadia S. Pleomorphic Adenoma of Minor Salivary Gland in Parapharyngeal Space. J Orofac Res 2013;3(4):284-285.

Source of support: Nil

Conflict of interest: None declared

CASE REPORT

A 35-year-old female presented with gradually progressive swelling in throat and change in speech of 3 months duration. On examination there was a smooth, firm bulge of soft palate and right parapharyngeal space. Postnasal examination showed extension of the swelling into the nasopharynx. Contrast enhanced computed tomography showed a well delineated soft tissue mass lesion of size measuring approximately (4.8 × 3.1 × 5) cm in right parapharyngeal region involving masticator space and prestyloid compartment causing obliteration of oropharynx and nasopharynx (Fig. 1). Post contrast showed minimal enhancement without any bone erosion or destruction. Preoperative fine needle aspiration cytology (FNAC) of

the lesion was suggestive of pleomorphic adenoma. The tumor was excised under general anesthesia via transpalatine approach (Fig. 2) and was sent to pathology department for histopathological examination which confirmed the diagnosis of pleomorphic adenoma. Postoperative period was uneventful. Patient was sent for radiotherapy.

DISCUSSION

Tumors in minor salivary gland constitute 22% of head and neck tumors, majority of them are malignant, 18% are benign and commonest among benign is pleomorphic adenoma.¹ Most common site of pleomorphic adenoma of minor salivary glands is palate followed by lip, buccal mucosa and floor of mouth, tongue, tonsil, pharynx, retromolar area and nasal cavity.² Classical findings of pleomorphic adenoma in parapharyngeal space is submucosal swelling in lateral pharyngeal wall.³⁻⁵

Histopathologically it shows epithelial tumor cells dispersed in acinar, ductal and cystically dilated glandular pattern, at places small sheets, chords and nests of tumor cells also seen in myxoid mesenchymal stroma.⁶

Formation of capsule is as a result of fibrosis of surrounding salivary parenchyma which is compressed by the tumor and is referred as a false capsule.⁶ Recurrence in 7% cases has been reported and is because of pseudopods in tumor.

Pleomorphic adenoma arising *de novo* in parapharyngeal space is of very rare occurrence, high index of suspicion and an

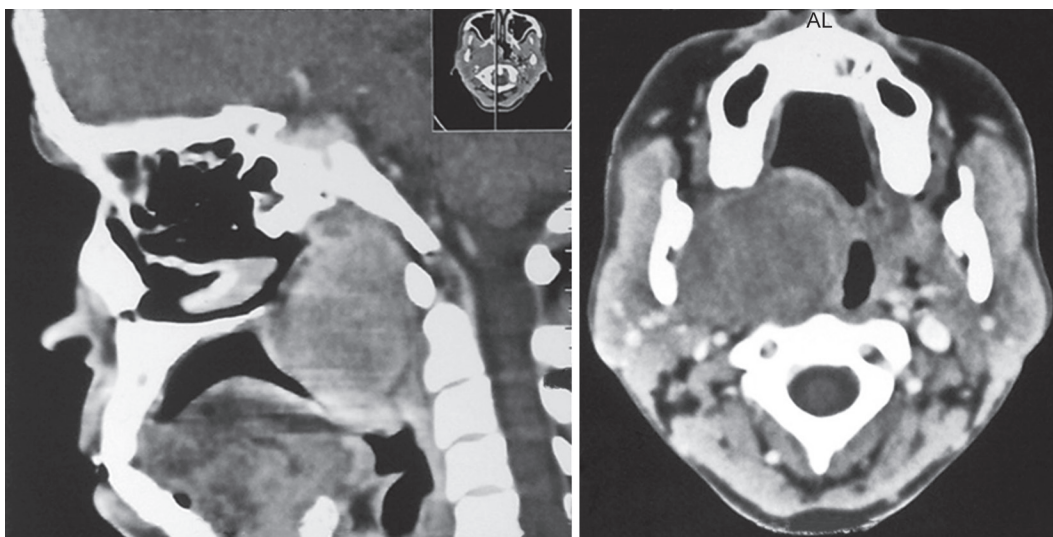


Fig. 1: CT scan showing tumor occupying oropharyngeal space

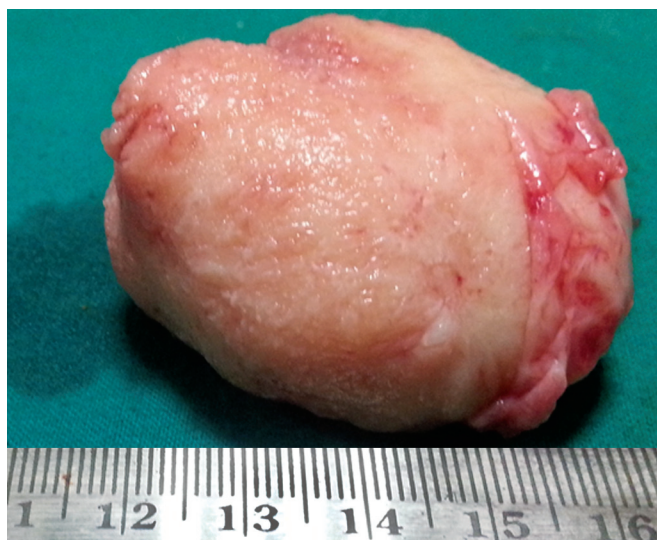

Fig. 2: Gross specimen of tumor after transoral excision

adequate clearance of the tumor with a cuff of surrounding dispensable normal tissues is the key to successful surgery. Pleomorphic adenoma has three malignant varieties: carcinoma expleomorphic adenoma, carcinosarcoma and metastasizing pleomorphic adenoma. Carcinoma ex pleomorphic adenoma is a rare mixed tumor developing from the epithelial component of the pleomorphic adenoma.⁷⁻⁹ The malignant transformation in the pleomorphic adenoma has been linked to recurrence and multiple excisions,^{10,11} laminin and collagen IV deposition.¹²

CONCLUSION

Pleomorphic adenoma of minor salivary gland in parapharyngeal space is a very rare entity so, it must be kept in differential diagnosis of any parapharyngeal swelling.

REFERENCES

1. Waldron CA, el-Mofty SK, Gnepp DR. Tumours of the intra oral salivary glands: a demographic and histologic study of 426 cases. *Oral Surg Oral Med Oral Pathol* 1988;66:323-333.
2. Eveson JW, Cawson RA. Tumour of the minor (oropharyngeal) salivary glands: demographic study of 336 cases. *J Oral Pathol* 1985;14:500-509.
3. Work PW, Gates GA. Tumours of parapharyngeal space. *Otolaryngol Clin N Am* 1969;Oct:479-514.

4. Bent JP, Dinges D, Whitehouse A. Pathologic quiz case-Minor salivary gland pleomorphic adenoma of the parapharyngeal space. *Arch Otolaryngol Head Neck Surg* 1992;118:664-666.
5. Work WP, Hybels RL. A study of tumours of the parapharyngeal space. *Laryngoscope* 1974;84:1748-1755.
6. Heeneman H. Parapharyngeal space tumours. In: Kerr AG, editor. *Scott Brown's Otolaryngology*. Edition 5. Butterworth and Co Ltd 1987;380-391.
7. Furukawa M, Suzuki H, Matsuura K, Takahashi E, Suzuki H, Tezuka F. Carcinoma ex pleomorphic adenoma of the palatal minor salivary gland with extension into the nasopharynx. *Auris Nasus Larynx* 2001;28:279-281.
8. Akan H, Yildiz L, Unal R. Carcinoma ex pleomorphic adenoma of minor salivary gland with pulmonary metastasis. *Diagn Interv Radiol* 2008;14:3-5.
9. Spiro RH, Koss LG, Hajdu SI, Strong EW. Tumors of minor salivary origin. A clinicopathologic study of 492 cases. *Cancer* 1973;31:117-129.
10. Livolsi VA, Perzin KH. Malignant mixed tumors in salivary glands; carcinomas arising in benign mixed tumors, a clinicopathologic study. *Cancer* 1977;39:2209-2030.
11. Karja V, Syrjanen K, Syrjanen S. Collagen IV and tenascin immunoreactivity as prognostic determinant in benign and malignant salivary gland tumors. *Acta Otolaryngol* 1995;115:569-575.
12. Felix AF, Costa Rosa J, Fonseca I, Cidado A, Soares J. Laminin and collagen IV in pleomorphic adenoma and carcinoma ex pleomorphic adenoma: an immunohistochemical study. *Hum Pathol* 1999;30:964-969.

ABOUT THE AUTHORS

Leena Jain (Corresponding Author)

Assistant Professor, Department of ENT, People's College of Medical Sciences and Research Centre, People's University, Bhopal, Madhya Pradesh, India, Phone: +91-7869913645, e-mail: drleejain@gmail.com

Sadat Qureshi

Assistant Professor, Department of ENT, People's College of Medical Sciences and Research Centre, People's University, Bhopal, Madhya Pradesh, India

Ashish Maurya

Assistant Professor, Department of ENT, People's College of Medical Sciences and Research Centre, People's University, Bhopal, Madhya Pradesh, India

Shalini Jadia

Associate Professor, Department of ENT, People's College of Medical Sciences and Research Centre, People's University, Bhopal, Madhya Pradesh, India