

Dentigerous Cyst associated with Impacted Supernumerary Maxillary Anterior Tooth

Preeti Nair, Pooja Khare

ABSTRACT

Dentigerous cyst (DC) is a common oral lesion formed by fluid accumulation between the fully formed tooth crown and the reduced enamel epithelium. It is associated mostly with mandibular impacted third molar and rarely with the mesiodens. This is an interesting case report of dentigerous cyst in the presence of full complement of teeth.

Keywords: Dentigerous cyst, Mesiodens, Tube shift.

How to cite this article: Nair P, Khare P. Dentigerous Cyst associated with Impacted Supernumerary Maxillary Anterior Tooth. *J Orofac Res* 2013;3(4):280-283.

Source of support: Nil

Conflict of interest: None

INTRODUCTION

Dentigerous cyst (DC) is a common oral lesion formed by fluid accumulation between the fully formed tooth crown and the reduced enamel epithelium. It is considered a developmental abnormality arising from the reduced enamel epithelium around the crown of an unerupted tooth. The predilection site of DC is the mandibular third molar. Other frequent sites include maxillary canines, maxillary third molars, and mandibular second premolar. It is always associated with any unerupted teeth, usually attached to the tooth at the cemento-enamel junction.¹ About 95% of dentigerous cysts involve the permanent dentition. Dentigerous cysts around supernumerary teeth account for 5% of all dentigerous cysts, most developing around a mesiodens in the anterior maxilla and palate.²

Supernumerary teeth can occur anywhere in dental arches but most commonly are found in the premaxilla. Supernumerary tooth develops from an extra tooth bud arising from the dental lamina near the permanent tooth bud, or possibly from splitting of the permanent tooth bud itself. Several complications may arise because of them.³ One of the rare problems associated with supernumerary teeth is the formation of dentigerous cyst.⁴ The usual age of clinical presentation of dentigerous cyst due to supernumerary tooth is in the first 4 decades. The highest incidence of dentigerous cysts occurs during the second and third decades (Shear, 1992).

Dentigerous cyst as the diagnosis in case of presence of full complement of teeth is rarest of rare condition. We report a case of dentigerous cyst associated with an impacted mesiodens.

CASE REPORT

A 30-year-old male patient reported with the chief complaint of pain and swelling in upper front teeth region of jaw since 2 months. The swelling was initially of the size of a peanut which gradually attained the present size. Swelling was followed by mild, intermittent, dull pain (Fig. 1).

A solitary swelling measuring 5 × 3 cm was present on the anterior maxillary vestibular region extending from 21 to 24. Color of the overlying mucosa was similar to the surrounding normal mucosa. There was mild palatal expansion related to similar teeth. Clinical examination revealed a tender, firm swelling fixed to the alveolar process

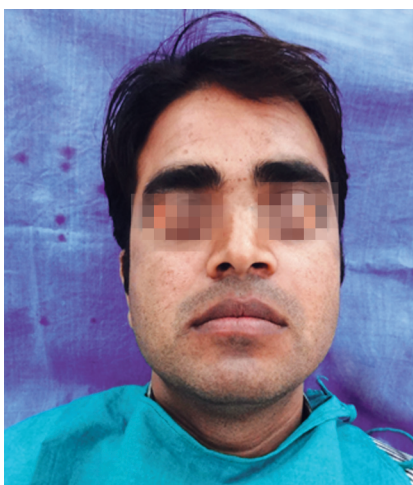

Fig. 1: Profile picture of patient

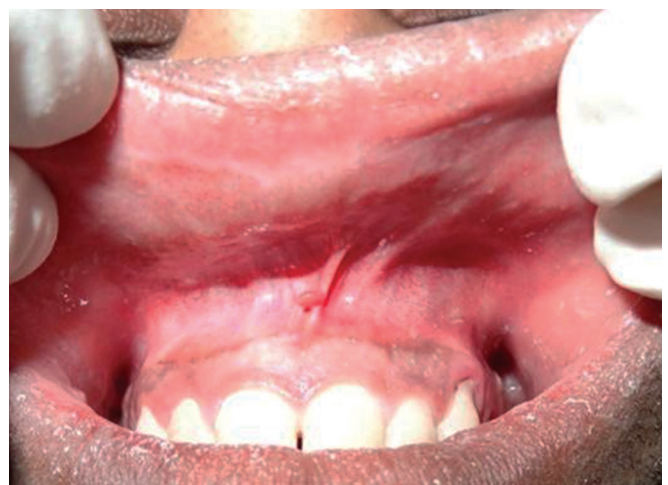

Fig. 2: Vestibular obliteration of left maxillary region

of maxilla and palate with diffuse borders. Yielding was present above 22 of the swelling (Fig. 2).

The provisional diagnosis of bony swelling with respect to 22 was given. The differential diagnosis included adenomatoid odontogenic tumor, keratocystic odontogenic tumor, calcifying epithelial odontogenic cyst and dentigerous cyst arising from supernumerary tooth.

Vitality test was done for all the maxillary teeth with electric pulp tester which did not elicit any abnormal response. An occlusal radiograph was taken which showed a well defined pericoronal unilocular radiolucency which was surrounding a radiopaque mass resembling inverted supernumerary tooth. The radiolucency measured 5.2 cm in width and 7 cm in height and it crossed the midline. The radiographic diagnosis of dentigerous cyst arising from supernumerary tooth was made (Fig. 3).

Tube shift technique was performed. The mesiodens was palatally placed (Fig. 4).

A panoramic image was obtained which shows well defined corticated radiolucency encircling an inverted supernumerary impacted tooth (Fig. 5).

An aspiration of the lesion yielded 0.9 ml of purulent fluid mixed with blood (Fig. 6).

The patient was operated under local anesthesia and enucleation was done. Histopathological examination of the enucleated specimen revealed an odontogenic cystic lining which confirmed the diagnosis of a dentigerous cyst .

DISCUSSION

The dentigerous cyst is the second most common odontogenic cyst, with periapical cyst being found more commonly. It presents mostly in the second or third decade of life in the maxillary or mandibular third molar or maxillary canine regions.⁵ Dentigerous cyst associated with supernumerary tooth constitute vast majority an about 90%, are associated with a maxillary mesiodens.⁶

Common lesions associated with anterior maxillary swelling is radicular cyst and AOT. This case presents an anterior maxillary swelling due to dentigerous cyst associated with a mesiodens.

Radiographic appearance of dentigerous cyst is that of a well-defined pericoronal radiolucent lesion, which may be unilocular or multilocular in appearance.⁷ In addition to its potential for bone destruction and because of the multipotential nature of this epithelium derived from the dental lamina, several entities may arise in or be associated

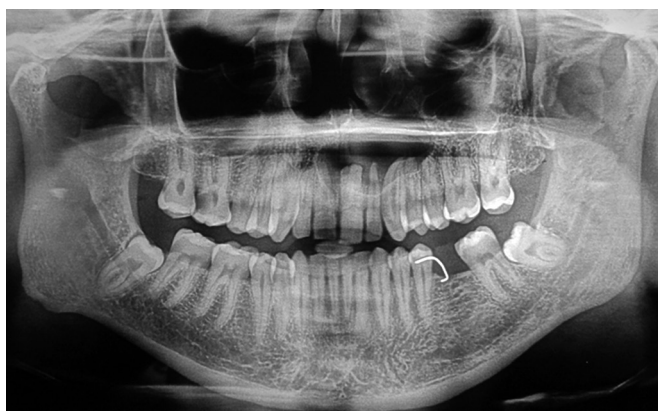

Fig. 3: Maxillary occlusal cross-sectional view showing radiolucency encircling an inverted supernumerary tooth

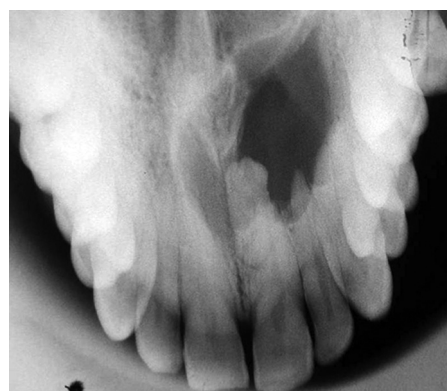


Fig. 4: Tube shift technique

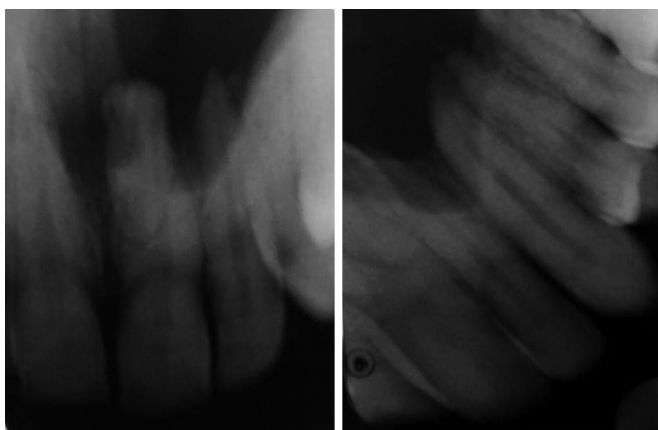


Fig. 5: Panoramic view showing pericoronal radiolucency with mesiodence

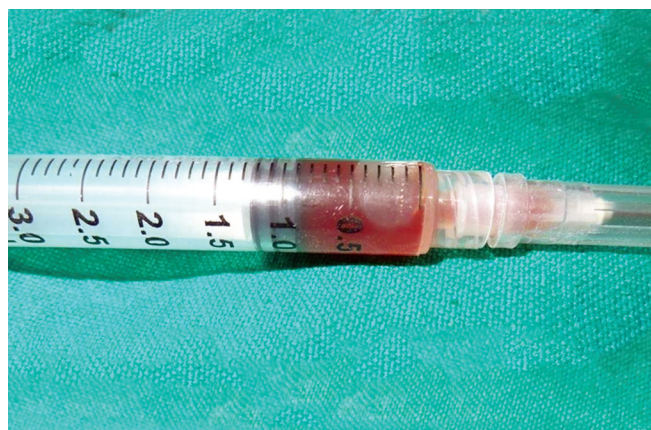

Fig. 6: Aspirate showing serosanguinous fluid

with the wall of a dentigerous cyst. Paradental cyst or buccal bifurcation cyst is a variant of the dentigerous cyst that originates at the bifurcation of molar teeth. It appears as a well circumscribed radiolucency in buccal bifurcation region and buccal tipping of crown can be demonstrated in occlusal radiograph.⁵ Waters view, panoramic radiographs and plain skull radiographs are simple and inexpensive methods that are used routinely to aid in diagnosis. Computed tomographic (CT) imaging displays bony detail, and gives exact information about the size, origin, content and relationships of the lesions involving the maxilla. The indications for CT examination of the mandible include the following cases: dentigerous cysts with large size, dentigerous cysts including >1 tooth and supernumerary impacted teeth with dentigerous cyst, especially in the transitional dentition. CT enables a more accurate visualization of the relations between the cyst and the surrounding bone structures and helps to assess the precise osteolytic changes.⁸ Magnetic resonance imaging (MRI) may fail to show the bony detail but precisely displays the lesional contents and provides information about the cyst fluid.

On histopathological examination in noninflamed cysts the lining epithelium appears 2 to 4 layers thick formed by 2 to 4 layers of flattened nonkeratinizing cells, the fibrous connective tissue wall is loose and contains substantial amount of glycosaminoglycan ground substance.

Treatment of dentigerous cyst depends on size, location, disfigurement and often requires variable bone removal to ensure total removal of the cyst, especially in cases of large ones.⁹ Thus treatment for dentigerous cysts is surgical removal.¹⁰

Because of the potential for occurrence of an odontogenic keratocyst or the development of an ameloblastoma¹¹ or mucoepidermoid carcinoma, all such lesions, when removed, should be submitted for histopathologic evaluation.

Supernumerary teeth are defined as those in addition to the normal series of deciduous or permanent dentition.¹² The exact etiology of the supernumerary teeth has not yet completely understood. Several theories have been suggested for their occurrence, such as the phylogenetic theory,¹³ the dichotomy theory,¹⁴ occurrence due to hyperactive dental lamina¹⁵ and due to a combination of genetic and environmental factors.¹⁶

AT Pitts in 1924 reported a case of dentigerous cyst associated with a supernumerary tooth palatal to molar in a 45-year-old male patient.¹⁷ Sharma et al reported a case of dentigerous cyst associated with two impacted supernumerary teeth.¹⁸ Several authors have reported dentigerous cyst with maxillary mesiodense.¹⁹⁻²¹

To conclude, dentigerous cysts have more affinity for mandibular third molar region but supernumerary tooth is more common in maxillary anterior region. Therefore finding a dentigerous cyst in this region is not a common entity. We have reported a case with such an uncommon condition and focused on the clinicoradiographic features.

REFERENCES

1. Neville BW, Damm DD, Allen CM, Bouquot JE. Oral and Maxillofacial Pathology. 2nd ed. Philadelphia: WB Saunders 2002;590-593.
2. Von Arx T. Anterior maxillary supernumerary teeth: a clinical and radiographic study: Australian Dental Journal 1992;37(3): 189-195.
3. Shun Y. Dentigerous cyst associated with an impacted anterior maxillary supernumerary tooth. J Dent Child (Chic) 2008 Jan-Apr; 75(1):104-107.
4. Lustmann J, Bodner L. Dentigerous cysts associated with supernumerary teeth. Int J Oral Maxillofac Surg 1988;17: 100-102.
5. Regezi JA, Sciubba JJ, Jodan RCK. Oral pathology, clinical pathologic correlations. 4th ed. St. Louis: WB Saunders 2003: 246-288.
6. Dinkar AD. Dentigerous cyst associated with multiple mesiodens: a case report. J Indian Soc Pedod Prev Dent 2007 March;25(1):56-59.
7. Asaumi JI, Shibata Y, Yanagi Y, et al. Radiographic examination of mesiodens and their associated complications; Dentomaxillofacial Radiology 2004;33(2):125-127.
8. Han MH, Chang KH, Lee CH, Na DG, Yeon KM, Han MC. Cystic expansible masses of the maxilla: Differential diagnosis with CT and MR. AJNR 1995;16:333-338.
9. Primosch RE. Anterior supernumerary teeth: assessment and surgical intervention in children. Pediatric Dentistry 1981;3: 204-221. P Mid: 6945564.
10. Kessler HP, Kraut RA. Dentigerous cyst associated with an impacted mesiodens. General Dentistry 1989;37(1):47-49.
11. Gardner DG, Corio RL. Plexiform unicystic ameloblastoma: a variant of ameloblastoma with a low recurrence rate after enucleation. Cancer 1984;53(8):1730-1735.
12. Yusof WZ. Nonsyndromal multiple supernumerary teeth: Literature review. J Can Dent Assoc 1990;56:147-149.
13. Smith JD. Hyperdontia: Report of a case. J Am Dent Assoc 1969;79:1191-1192.
14. Liu JF. Characteristics of premaxillary supernumerary teeth: a survey of 112 cases. ASDC J Dent Child 1995;62: 262-265.
15. Primosch RE. Anterior supernumerary teeth: assessment and surgical intervention in children. Pediatr Dent 1981;3: 204-215.
16. Brook AH. A unifying etiological explanation for anomalies of human tooth number and size. Arch Oral Biol 1984;29: 373-378.
17. Pitts AT. Dentigerous cyst apparently associated with a supernumerary tooth. Proc R Soc Med 1924;17 (Odontol Sect): 9-10.

18. Sharma A, Singh VP, Sharma S. Dentigerous cyst associated with unusual supernumerary teeth: a case report. *Asian J Medical Sciences* 2011;2:124-127.
19. Dinkar AD, Dawasaz AA, Shenoy S. Dentigerous cyst associated with multiple mesiodens: a case report. *J Indian Soc Pedod Prev Dent* 2007;25:56-59.
20. Shun Y. Dentigerous cyst associated with an impacted anterior maxillary supernumerary tooth. *J Dent Child (Chic)* 2008 Jan-Apr;75(1):104-107.
21. Shah KM, Karagir A, Adaki S, Pattanshetti C. Dentigerous cyst associated with an impacted anterior maxillary supernumerary tooth. *BMJ Case Rep.* 2013; Jan 31;2013. pii: bcr2012008329. doi: 10.1136/bcr-2012-008329.

ABOUT THE AUTHORS

Preeti Nair

Professor, Department of Oral Medicine and Radiology, Peoples College of Dental Sciences and Research Centre, Bhopal, Madhya Pradesh, India

Pooja Khare (Corresponding Author)

Postgraduate Student, Department of Oral Medicine and Radiology Peoples College of Dental Sciences and Research Centre, Bhopal, Madhya Pradesh, India, e-mail: drpoojakhare@in.com