

Management of Combined Gingival and Alveolar Fenestration in Maxillary Lateral Incisor: A Report of a Rare Case

Balachandran Ashwath, Sundaram Subramoniam, Arunachalam Muthukumaraswamy

ABSTRACT

Gingival fenestrations are of uncertain etiology having rarely been reported in the dental literature. It seems to have a multifactorial origin and is commonly associated with the anterior region of the arch, especially the incisors. They are usually associated with chronic periapical inflammation. The resorption of bone is usually not associated with such defects. The routine therapeutic modalities used for these defects include mucogingival procedures such as free gingival graft, subepithelial connective tissue graft, pouch and tunnel technique and guided tissue regeneration. The following case describes a rare clinical situation where a gingival fenestration is associated with a large bone defect treated with bone grafting and guided tissue regeneration.

Keywords: Fenestration, Dehiscence, Bone grafting, Guided tissue regeneration, Bone regeneration.

How to cite this article: Ashwath B, Subramoniam S, Muthukumaraswamy A. Management of Combined Gingival and Alveolar Fenestration in Maxillary Lateral Incisor: A Report of a Rare Case. *J Orofac Res* 2013;3(4):266-269.

Source of support: Nil

Conflict of interest: None declared

INTRODUCTION

The maxilla and mandible comprise the alveolar process, the portion of the jaw bones that forms and supports teeth and the basal bone. The morphologic features of bone are altered during periodontal disease and various osseous defects have been reported in literature. Apart from this, the normal osseous topography is altered by the morphology of the root and tooth position. Fenestration and dehiscence

are two such defects of the alveolar bone. Fenestration is a circumscribed defect of the cortical plate which exposes the underlying root surface, but does not involve the alveolar margin of the bone while dehiscence is a lack of the facial or lingual alveolar cortical plate resulting in a denuded root surface.¹ The etiology of such defects can be due to decreased thickness of the alveolar housing, labioversion of the tooth in the dental arch, contour of the root apex, orthodontic tooth movement, periodontal and endodontic pathology and high frenal attachment.² The conventional treatment modalities for fenestrations defects includes full thickness flap, free gingival grafting and guided tissue regeneration using resorbable or nonresorbable membrane.³ The following report presents an unusual clinical scenario wherein an isolated area of soft tissue and bone is denuded in the labial aspect of maxillary left lateral incisor in the attached gingiva.

CASE REPORT

A 22-year-old female patient reported to a private dental clinic in Chennai, India, complaining of discolored left upper front tooth with a tear in the gingiva. The patient was in good general health. Patient gave a history of a traumatic injury to the anterior tooth 2 years back and had undergone root canal treatment immediately following the injury. Clinical examination revealed a discolored and fractured 22 (Ellis and Davis Class III) with a perforated buccal cortical plate and a fenestration in the attached gingiva measuring 5 mm by 3 mm (Figs 1A and B). The tooth showed normal physiologic

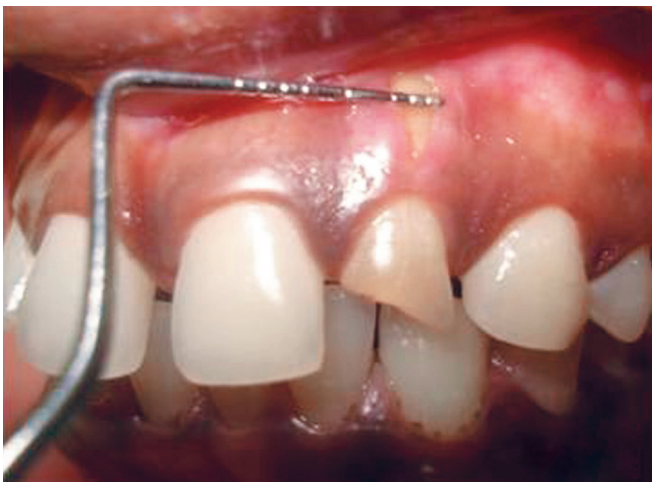

Fig. 1A: Preoperative width of the defect

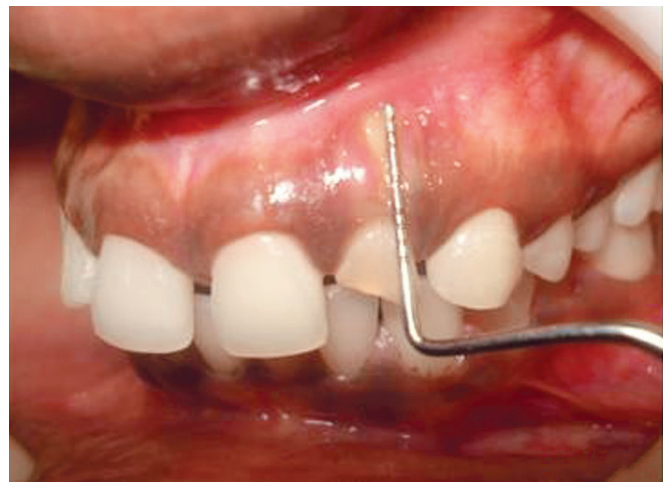

Fig. 1B: Preoperative height of the defect

mobility. Radiographic examination revealed obturated 22 with no other significant changes in the alveolar bone.

Since there was no gingival recession it was decided to perform bone sounding under local anesthesia in relation to 22. A sharp, solid sensation was felt which indicated the presence of a dehiscence and the probe must have moved over the root extending from apical third to cervical third of the root. Hence it was decided to perform an access flap surgery to expose the periapical region of 22 where the dehiscence was suspected.

The maxillary anterior region was anesthetized using 2% lignocaine with 1:100000 adrenaline. Full thickness mucoperiosteal flap was reflected in relation to the maxillary anterior segment. Flap reflection revealed complete dehiscence of the root of the lateral incisor with a bone defect

circumscribing the root apex. Flap reflection was extended 2 mm beyond the root apex of the tooth. There was no cystic or granulomatous region in the root apex of 22. Mesial and distal interproximal bone in relation to 22 was intact with no crestal bone loss. The defect was completely debrided and decortication of the surrounding bone was performed using a round bur under copious irrigation (Fig. 2A). The root was demineralized using 24% ethylenediaminetetraacetic acid. Anorganic bovine bone mineral (BioOss™) was placed in the defect area to aid in bone regeneration (Fig. 2B). A resorbable collagen barrier membrane (Healiguide®) was placed over the bone graft and the exposed root surface and the flaps were approximated with interrupted sutures using 3-0 black silk (Figs 3A and B). The soft tissue defect was also

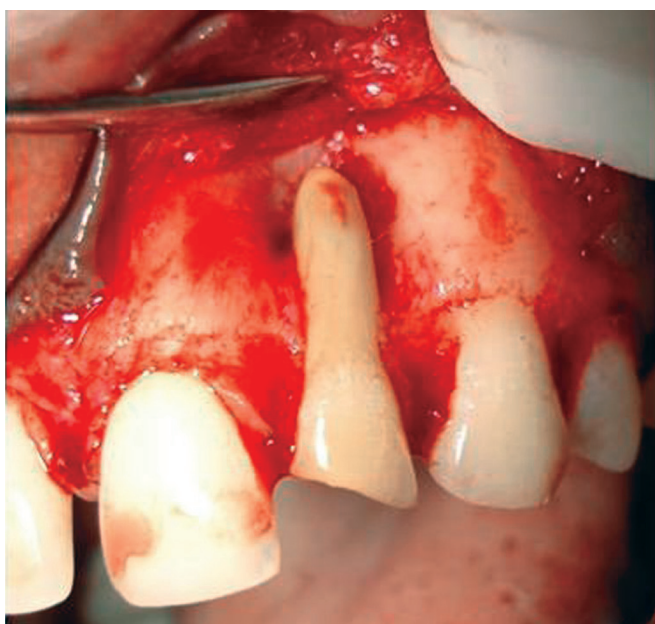

Fig. 2A: Osseous defect around the root apex of 22 after flap reflection and degranulation

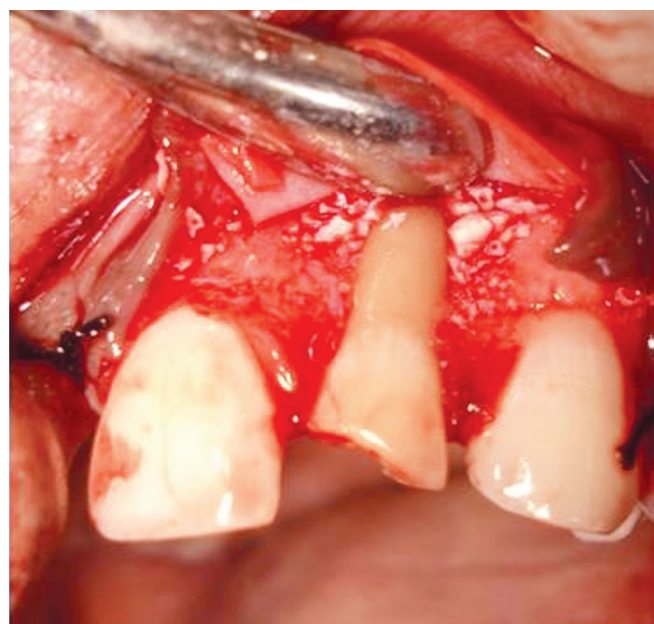


Fig. 2B: Bone graft placed in the osseous defect

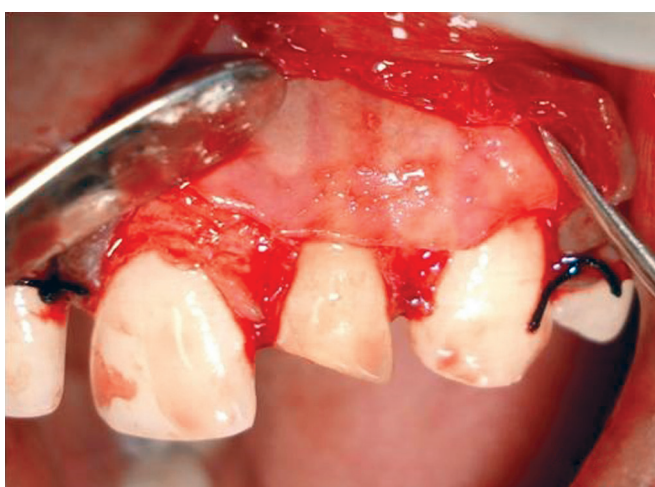

Fig. 3A: Resorbable collagen membrane placed over the bone graft in the defect site

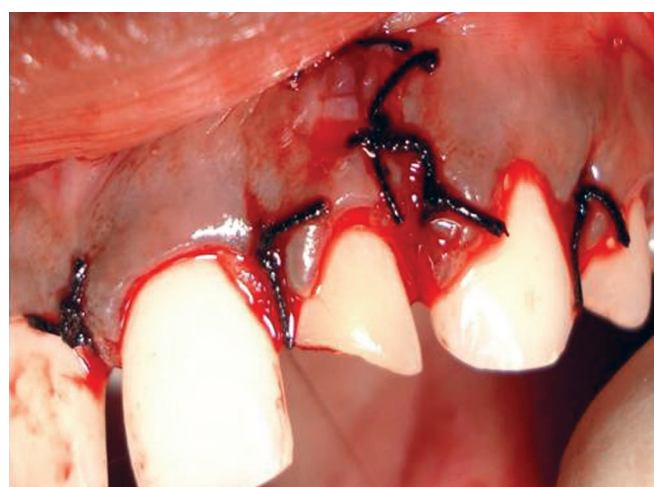
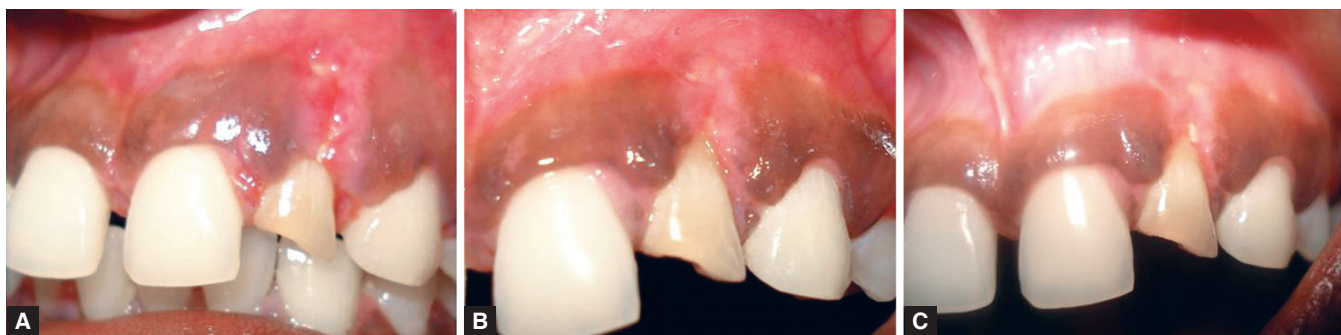

Fig. 3B: Flaps sutured



Figs 4A to C: (A) Ten days postoperative image at time of suture removal, (B) one month postoperative image showing satisfactory healing of the site and (C) three months postoperative image showing coverage of the soft tissue defect

sutured using 3-0 black silk. The patient was discharged after placement of a periodontal dressing (Coe-Pak). Post operative instructions included refraining from mechanical cleansing of the surgical site, which could disturb initial healing and to rinse with 0.2% Chlorhexidine gluconate solution (Hexidine, ICPA Health Care Products Ltd., Mumbai, India) twice a day for 1 minute. The patient was prescribed antibiotics (amoxicillin 500 mg t.i.d for 5 days) and anti-inflammatory/analgesic medications (ibuprofen and paracetamol combination t.i.d for 3 days). The wound healing was satisfactory without any local complications and suture removal was done after 10 days (Fig. 4A). The healing was uneventful. One month healing showed closure of the soft tissue fenestration defect with complete closure seen at 3 months (Figs 4B and C).

DISCUSSION

Dehiscence and fenestrations reflect anatomical variations concerning the shape and the morphology of the alveolar bone. Gingival fenestrations are not common and they are rarely encountered in clinical practice. Their presence may worsen the prognosis of the affected tooth. It was first described by Menendez OR in 1967.⁴ A combined gingival and alveolar fenestration is rarely associated with non-vital tooth as we found in the clinical case above. Gingival fenestrations are considered an uncommon complication of pulpal-periradicular disease.⁵

The etiology of these defects is not exactly clear but they are known to occur occurring in areas of thin keratinized mucosa. Due to inflammation, gingival fibers are lost, rendering the tissue freely movable by forces such as mastication and toothbrushing, which, combined with subgingival plaque, may result in the formation of a window in the gingiva.⁶ Dehiscence defects are more prevalent in the mandibular canine-first premolar region followed by the maxillary canine region.^{7,8}

This case depicts the presence of a fenestration not only in the alveolar bone but also extending to the attached gingiva in relation to the maxillary lateral incisor labially. Although clinically it was a fenestration defect of both hard and soft tissue of the teeth we suspected the osseous defect to involve the marginal bone as well. Therefore bone sounding was done which helped to detect the presence of a large dehiscence extending from marginal bone to the periapical region on the labial aspect of maxillary lateral incisor. This was confirmed following flap reflection. Since there was no cystic or granulomatous lesion or root resorption, periapical surgery was not performed. The presence of the bone defect was also not elucidated on the radiograph as it was a dehiscence defect of the labial bone of the lateral incisor. This case report highlights the significance of bone sounding and it should be a routinely performed as a part of investigation when radiographs are not useful. It helped in identifying the dehiscence defect and thereby enables the clinician to render the necessary therapeutic modality. Three months postoperative review showed clinical success of the procedure with the complete coverage of the dehiscence defect with no probing depth or attachment loss.

SUMMARY

Most of the alveolar bone fenestrations are undetectable clinically and radiographically. It frequently complicates the outcome of mucogingival surgical procedures. But the teeth affected by gingival fenestrations are usually accompanied by alveolar bone fenestrations. Attempting mucogingival procedures for such clinical situations may prove futile if there is an associated bone defect.

REFERENCES

1. Edel A. Alveolar bone fenestrations and dehiscence in dry Bedouin jaws. *J Clin Periodontol* 1981;8:491-499.
2. Chen G, Fang CT, Tong C. The management of mucosal fenestration: a report of two cases. *Int Endod J* 2009;42(2): 156-164.

3. Ling LJ. The treatment of fenestrated root: case reports. *J Dent Sci* 1989;9:137-140.
4. Menéndez OR. Bone fenestration by roots of deciduous teeth. *Oral Surg Oral Med Oral Pathol* 1967;24(5):654-658.
5. Serrano J. Gingivo-osseous pathological fenestration. *Oral Surg Oral Med Oral Pathol* 1971;32(5):697-700.
6. Lane JJ. Gingival fenestration. *J Periodontol* 1977;48:225.
7. Rupprecht RD, Horning GM, Nicoll BK, Cohen ME. Prevalence of dehiscences and fenestrations in modern American skulls. *Periodonto* 2001;7:722-729.
8. Nimijean VR, Nimijean V, Bencze MA, Dimcevic-Poesina N, Cergan R, Moraru S. Alveolar bone dehiscences and fenestrations; an anatomical study and review. *Romanian Journal of Morphology and Embryology* 2009;50(3): 391-397.

ABOUT THE AUTHORS

Balachandran Ashwath (Corresponding Author)

Senior Lecturer, Department of Periodontics, Madha Dental College, Kundrathur, Tamil Nadu, India, Phone: +91-9884166720
e-mail: ashwathbalachandran@gmail.com

Sundaram Subramoniam

Senior Lecturer, Department of Periodontics, Priyadarshini Dental College, Chennai, Tamil Nadu, India

Arunachalam Muthukumaraswamy

Associate Professor, Department of Periodontics, Tamil Nadu Government Dental College and Hospital, Chennai, Tamil Nadu, India