

Mucous Extravasation Phenomenon of Lingual Glands of Blandin and Nuhn

R Rajalakshmi, S Shabana Fathima, R Sajeew

ABSTRACT

Mucocele is a collection of mucin in the submucosa, which occurs mostly due to rupture of the gland proper or the duct of a minor salivary gland. They are most commonly found on the lower lip followed by floor of the mouth and buccal mucosa. Only 9 to 10% of Mucocele are found on the tongue and that they occur exclusively in the anterior lingual salivary glands of Blandin and Nuhn. The following is a case report of mucous extra-vasation phenomenon of lingual glands of Blandin and Nuhn.

Keywords: Mucocele, Extravasation Phenomenon, Blandin and Nuhn, Glands.

How to cite this article: Rajalakshmi R, Fathima SS, Sajeew R. Mucous Extravasation Phenomenon of Lingual Glands of Blandin and Nuhn. *J Orofac Res* 2013;3(3):230-232.

Source of support: Nil

Conflict of interest: None declared

INTRODUCTION

The mucocele is a common lesion of the oral mucosa that results from rupture of a salivary gland duct and spillage of mucin into the surrounding soft tissues.¹ The wall of this cavity is made up of a lining of compressed fibrous connective tissue and fibroblast.²

Mucoceles generally appear as soft, painless swelling of the mucosa with superficial lesion imparts a bluish translucent hue although deeper lesion appear normal in color.¹ The mucoceles are more commonly found in the lower lip but rarely reported on the tongue, upper lip, retromolar pad and palate.⁴ They may occur at any age, they are seen most frequently in the second and a third decade of life.³ This lesion has no sex predilection and occurs more frequently in children, adolescents and young adults.^{2,4}

Glands of Von Ebner, glands of Weber and the glands of Blandin and Nuhn are three main groups of minor salivary glands found in the human tongue. The glands of Von Ebner (located in association with the circumvallate and the foliate papillae) are serous glands, the glands of Weber (located along the lateral border of the tongue and posterior aspect of the dorsum of the tongue) are purely mucous glands, Whereas the glands of Blandin and Nuhn (located in the musculature of the anterior ventral surface of the tongue) are mixed mucous and serous glands. Mucoceles on the tongue occur almost exclusively on the ventral surface where the glands of Blandin and Nuhn are located.⁵

CLINICAL REPORT

A 10-year-old female patient came to the Department of Pedodontia and Preventive Dentistry, with a painless swelling of 10 days duration in the midline of the ventral surface of tongue (Fig. 1). Past medical history was non-contributory and she gave no history of trauma.

On examination, there was a soft, smooth, single, sessile, painless, translucent swelling measuring about 15 × 10 mm in the midline of the ventral surface of the tongue, 15 mm away from the tip of the tongue. On application of pressure, the lesion did not empty. The clinical appearance was that of a mucocele (Fig. 1). The lab investigations like Hb, BT and CT were conducted and the values are found to be normal.

The lesion was excised, under local anesthesia, by dissection down to the muscle layer along with associated normal minor salivary glands to avoid recurrence (Fig. 2). The wound was closed primarily with sutures. The excised tissue was submitted for pathological investigation (Fig. 3).

Histopathology Report (Fig. 4)

The given H & E stained soft tissue section shows surface epithelium associated with mucous extravasation. The lesional connective tissue comprises of haphazardly arranged collagen fibers admixed with muscle fibers and acini. Deeper down within the connective tissue shows empty space suggestive of mucin been washed and walled off by granulation tissue, resembling that of a cystic

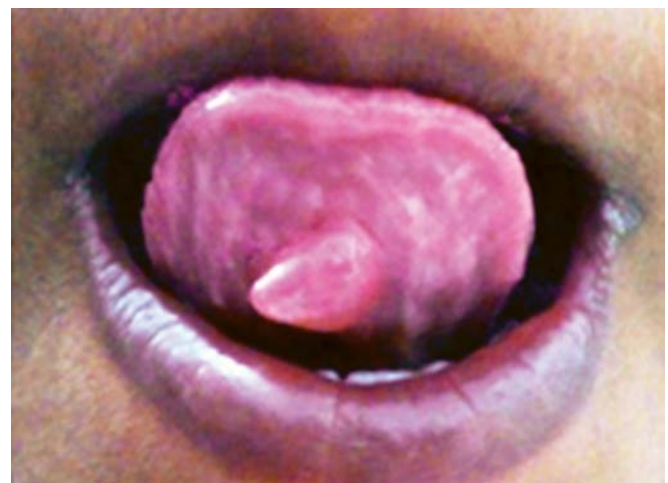

Fig. 1: The swelling on the ventral surface of the tongue

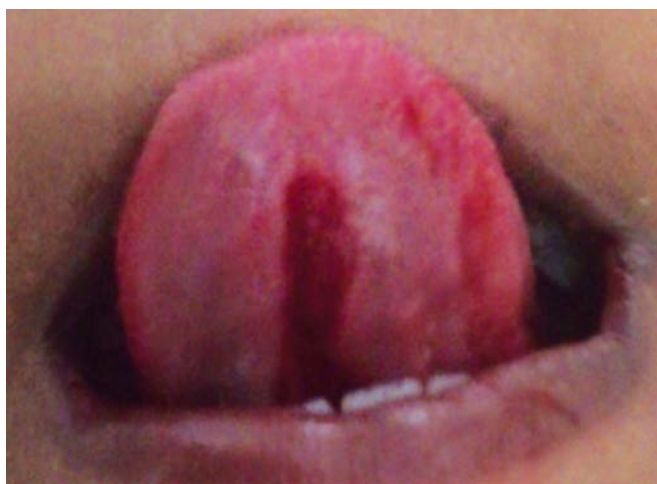


Fig. 2: Excision of the lesion

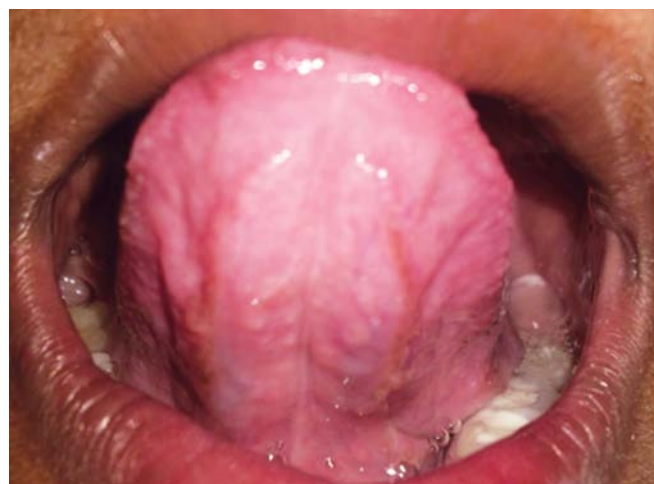

Fig. 5: Postoperative photograph after a period of 6 months

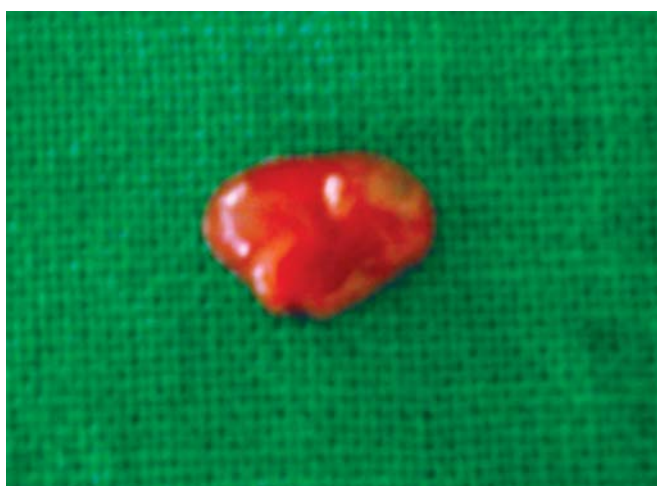

Fig. 3: Grossed tissue measuring about 15 × 10 mm

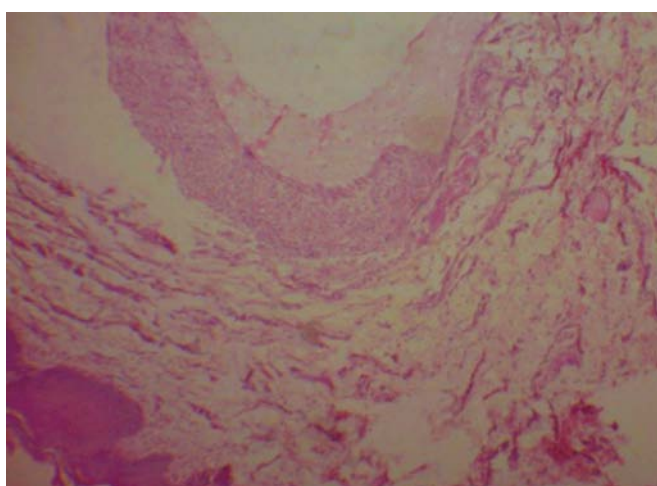


Fig. 4: The lower power photomicrograph shows epithelium with mucous extravasation

lining comprising of lymphocytes, flattened fibroblast and mucinophages. The histopathological findings were suggestive of ‘mucous extravasation phenomenon’.

Postoperative Review

The patient was followed for 6 months postsurgically. There was no recurrence of the lesion (Fig. 5).

DISCUSSION

Mucous extravasation cysts and mucous retention cysts are collectively referred as mucoceles. In mucous extravasation cyst, the mucous has extravasated into the connective tissue and there is no epithelial lining. The mucous retention cyst, occurs as a result of dilatation of the duct due to blockage by a sialolith or a mucus plug, usually found in the palate and floor of mouth and commonly seen in the older age group.^{6,7}

The extravasation type usually results from local trauma such as biting and is found most commonly in the lower lip and in younger age groups.⁷ In the present case, the patient revealed no history of trauma which can also be explained as per by Daniels et al.⁸ They describe that, the extravasation type mucoceles of Blandin and Nuhn may be reported even in the absence of trauma, which would have been so minor as to escape the patients’ attention.

Andiran et al, reported that the age of occurrence of mucoceles of Blandin and Nuhn ranged from 10 weeks to 26 years with a peak in the second decade. Jinbu et al pointed out extravasation cyst occurs in age range of 5 years to 36 years. Mucoceles of Blandin and Nuhn seem to have a predilection for females as stated by Andiran, Jinbu et al⁸ and Saurabh R Joshi et al.⁹ In our case, it is also a female patient in the beginning of second decade of life.

Mucoceleles of Blandin and Nuhn are usually less than 10 mm in diameter.⁶ Occasionally, they may reach a large size of 3 cm or greater. Larger lesions may interfere with normal feeding or may cause airway obstruction.¹⁰ The superficial lesions often imparts a bluish translucent hue, although deeper mucoceles may be normal in color. The

mucocoeles characteristically are painless, fluctuant and duration varies from few days to several years.¹ The current case presents a single, soft, smooth, sessile, painless, translucent swelling measuring about 15 × 10 mm, which coincides with the clinical features of mucous extravasation phenomenon of lingual glands of Blandin and Nuhn.

The majority of the cases of mucocoeles of Blandin and Nuhn are polypoid, fluid filled masses usually located in the tip of the ventral surface of the tongue. Rarely, these lesions are presented lateral to the midline.¹¹ Saurabh R Joshi et al⁹ reported that among 30 lesions 24 (80%) lesions were located at the midline, only six lesions occurred laterally to the midline. In the present case, the lesion is present in the midline of the ventral surface 15 mm away from the tip of the tongue.

The various differential diagnosis of mucocele are ranula, benign or malignant salivary gland neoplasms, oral hemangioma, cysticercosis (parasitic infection), oral lymphangioma, superficial mucocele may be confused with cicatricial pemphigoid, bullous lichen planus and minor aphthous ulcers.^{1,2,4}

Surgical excision with removal of the involved accessory salivary gland has been suggested as the treatment. Marsupialization will only result in reoccurrence.³ Reoccurrence of the lesion twice after marsupialization was reported by Ellis et al and it was satisfactorily treated only by complete excision.¹²

Large lesions may be marsupialized (unroofing procedure) followed by surgical excision to prevent significant loss of tissue or to decrease the risk for significantly traumatizing the labial branch of the mental nerve. The excised tissue should always be submitted to the pathological investigations to confirm the diagnosis and rule out the salivary gland tumors.⁴ Alternative method of treatment includes laser ablation, cryotherapy, electrocautery and intralesional corticosteroid injections.^{8,13}

CONCLUSION

This is a case report of mucous extravasation phenomenon of lingual glands of Blandin and Nuhn. The rate of occurrence of this lesion is only 9 to 10%. Mucocele of Blandin and Nuhn seem to have a predilection for females and the age of occurrence was ranged from 10 weeks to 26 years with a peak in the second decade. The present subject exhibited a soft, single, sessile, painless, translucent swelling measuring about 15 × 10 mm on the ventral surface of the tongue, 15 mm away from the tip of the tongue. Surgical excision

with removal of the involved accessory salivary gland was done to correct the condition and to prevent recurrence.

REFERENCES

1. Neville BW, Damm DD, Allen CM, Bouquot JE. Oral maxillofacial pathology. 3rd ed; Elsevier; 2009. p.258-269
2. Sivapathasundharam RB. Shafer's Textbook of Oral Pathology. 5th ed. Elsevier; 2009. p. 113-121.
3. McDonald, Avery and Dean: dentistry for the child and adolescent, 8th ed. Mosby; 2004. p.321-323.
4. Gupta B, Anegundi R, Sudha P, Mucocele MG. Two case reports. J Oral Health Comm Dent 2007;1(3):56-58.
5. Tandler B, Pinkstaff CA, Riva A. Ultrastructure and histochemistry of human anterior lingual salivary glands (glands of Blandin and Nuhn). Anat Rec 1994;240:167-177.
6. Shear M, Speight PM. Cysts of the oral and maxillofacial regions. 4th ed. Blackwell Munksgaard 2007. p.212-215.
7. Greenberg MS. Salivary gland disease. In: Lynch MA, editor. Burket's oral medicine: diagnosis and treatment. Lippincott-Raven: Philadelphia, PA 1997, pp. 415-418.
8. Daniels JSM, Al Bakri IM. Mucocele of lingual glands of Blandin and Nuhn: a report of 5 cases Saudi Dental Journal 2005;17(3):154-161.
9. Joshi SR, Pendyala GS, Choudhari S, Kalburge J. Mucocele of the glands of Blandin and Nuhn in children: a clinical, histopathologic and retrospective study. N Am J Med Sci 2012 Sept;4(9):379-383.
10. Andiran N, Sarikayalar F, Unal OF, Baydar DE, Ozaydain E. Mucocele of the anterior lingual salivary glands from extravasation to an alarming mass with a benign course. Int J Paediatr Otorhinolaryngol 2001;61:143-147.
11. Jinbu Y, Kusama M, Itoh H, Matsumoto K, Wang J, Noguchi T. Mucocele of the glands of Blandin and Nuhn: clinical and histopathological analysis of 26 cases. Oral Surg Oral Med Oral Pathol Oral Radiol Endod 2003;95:467-470.
12. Ellis E, Scott R, Upton LG. An unusual complication after excision of a mucocele of the anterior lingual gland. Oral Surg Oral Med Oral Pathol 1983;56:467-471.
13. Wilcox JW, Hickory R. Nonsurgical resolution of mucocele. J Oral Surg 1978;36:478.

ABOUT THE AUTHORS

R Rajalakshmi (Corresponding Author)

Senior Lecturer, Department of Pedodontia, Adhiparasakthi Dental College, Melmaruvathur, Tamil Nadu, India, Phone: 9894424241 e-mail: lux_me_laks@yahoo.co.in

S Shabana Fathima

Senior Lecturer, Department of Oral Pathology, Adhiparasakthi Dental College, Melmaruvathur, Tamil Nadu, India

R Sajeev

Professor, Department of Pedodontia, Adhiparasakthi Dental College Melmaruvathur, Tamil Nadu, India