

'Porcelain Veneers, a Smile Make Over': A Short Review

Nitesh Shetty, Savita Dandakeri, Shilpa Dandakeri

ABSTRACT

Technological advances in materials and techniques have been allowing to obtain natural esthetic results with conservative interventions. Ceramic veneers are very effective tools for both esthetic and functional rehabilitation. Laminate veneers are a conservative treatment of unesthetic anterior teeth. This evolution of materials, ceramics, and adhesive systems permits improvement of the esthetic of the smile and the self-esteem of the patient. This review gives an insight about the evolution, indications, contraindications, advantages, and disadvantages, material aspects, techniques of the laminates as an effective esthetic restoration.

Keywords: Porcelain veneers, Substrate treatment, Luting cements.

How to cite this article: Shetty N, Dandakeri S, Dandakeri S. 'Porcelain Veneers, a Smile Make Over': A Short Review. *J Orofac Res* 2013;3(3):186-190.

Source of support: Nil

Conflict of interest: None declared

INTRODUCTION

Esthetics in our culture has become a matter of necessary concern to the dentist. Evolving trends and treatments in dentistry have made it necessary to diversified dental services. In the practice of esthetic dentistry achievement of a natural and, convincing result produces immediate acceptance. Failure to achieve this would produce immediate rejection. Esthetic dentistry is the fourth dimension in addition to other factors like the biological, physiological and mechanical factors, all of which are to be combined for a successful result.¹ Based on their strength, longevity, conservative nature, biocompatibility and esthetics, veneers have been considered one of the most viable treatment modalities. Esthetic veneers in ceramic materials demonstrate excellent clinical performance and, as materials and techniques have evolved, veneers have become one of the most predictable, most esthetic, and least invasive modalities of treatment.² For this reason, both materials and techniques provide the dentist and patient an opportunity to enhance the patient's smile in a minimally invasive to virtually noninvasive way.³ Initially used to treat various kinds of tooth discoloration, porcelain laminate veneers have been increasingly replaced by more conservative therapeutic modalities, such as bleaching and enamel microabrasion.⁴ However, this evolution has not led to a decrease in indications for veneers, as materials and techniques continue to be developed. Ceramic veneers are

considered the ultimate option for a conservative esthetic approach because they leave nearly all of the enamel intact before the veneer is placed.³ Accordingly, this article discusses the aspects of ceramic laminate veneers restoration that involve materials, applications, and techniques, as they relate to the continued success of this modality of treatment.

LITERATURE REVIEW

The history of esthetic or cosmetic dentistry can be dated back to the Japanese customs of decorative tooth staining called 'Ohoguro' which was documented 4000 years ago. Dr Charles L Pincus introduced the concept of veneering anterior teeth with laminates when approached by Hollywood directors in 1928.⁵ It was Bunacore's research about the acid etching technique in 1955, which provided a simple method of increasing adhesion to enamel surface for acrylic materials.⁶ But only after the introduction of light cured composites in 1970 did the dentist have the necessary working time to properly shape direct laminate veneers. In the mid 70's and 80's the composite resin laminate veneers, (with or without facing evolved). At first the composites were directly bonded to teeth and called 'bonding'.¹ These were added directly to the facial surfaces of tooth to restore malformed, fractured or discolored permanent incisors in a procedure known as 'bonding'.^{7,8} The use of 'bonding' presented several problems such as monochromatic appearance, loss of luster over time and staining. As these restorations did not employ any tooth preparation, a bulk of material was necessary to obtain a pleasing appearance thus leading to gingival inflammation due to overcontoured restorations.^{8,9} It was in 1975 when Rochette explained the concept of acid etching porcelain and bonding to the tooth, and described a technique for making ceramic restorations.¹ Next in evolution came the procedure referred to as 'laminating' where veneer facings were bonded to etched tooth structure.⁹ Hollow ground denture teeth, preformed stock laminates, and custom fabricated laminates of processed acrylic resin were commonly used.^{10,11} Laminating was a definite improvement over bonding but color instability, surface staining, loss of surface luster, low abrasion resistance, biologic incompatibility, and a poor bond between the veneer and the tooth still persisted.¹² In the early 1980s a method of bonding porcelain to acid etched enamel was developed. Etching the porcelain with hydrofluoric acid or a derivative increases the shear bond strength between composite resin

luting agent and the porcelain veneer by a factor of four when compared to unetched porcelain.^{8,13}

ADVANTAGES OF CERAMIC VENEERS⁸

Porcelain presents various advantages over other veneering systems and acts as an excellent replacement for unesthetic tooth substance.

Conservative approach: Laminate veneer preparations are much more conservative of tooth structure than either porcelain fused to metal or all porcelain full coverage restorations.

Color: Porcelain offers better inherent color control, translucency, natural look and color stability.

Bond strength: Etched porcelain bonds to enamel surface much better than any other veneering system.

Resistance to abrasion: Porcelain is known for its exceptionally high wear and abrasion resistance as compared to composite resins.

Strength: Porcelain veneer restorations develop high shear and tensile strengths when veneer is luted to the enamel.

Periodontal health: Highly glazed porcelain surface resists plaque accumulation as compared to any other veneer system thus maintaining periodontal health.

Esthetics: Much better esthetics than any other veneer material as it enables control of color and surface texture. Both internal and superficial stains can be used with porcelain and the natural fluorescence lends a certain vitality.

Resistance to fluid absorption: Porcelain absorbs fluid to a lesser degree than any other veneering material.

DISADVANTAGES OF CERAMIC VENEERS⁸

Cost: Additional cost incurred when compared to direct restorations due to laboratory involvement and additional chairside time required. The cost will also depend on difficulty of patients problem, the time, level of skill, artistic requirements and planning involved.

Time: Veneering is a highly technique sensitive procedure and thus time consuming. Multiple visits also demand more time.

Fragility: Veneers are extremely fragile and difficult to manipulate during try-in and cementation stages.

Repair: Repairs are difficult once veneers are luted to the enamel.

Color: It is difficult to modify color once the veneer has been luted to the enamel surface, also precise shade matching is difficult.

Technique sensitive: Fabrication of veneers is an indirect process requiring accurate impression making and high quality laboratory work.

INDICATIONS FOR VENEER PLACEMENT⁸

Veneers can be used for functional and cosmetic correction of the following conditions:

1. Stained or darkened teeth
2. Hypocalcification
3. Multiple diastemas
4. Peg laterals
5. Chipped teeth
6. Lingual positioned teeth
7. Malposed teeth not requiring orthodontics.

CONTRAINDICATIONS FOR VENEER PLACEMENT INCLUDE⁸

1. Insufficient tooth substrate (enamel for bonding)
2. Labial version
3. Excessive interdental spacing
4. Poor oral hygiene or caries
5. Parafunctional habits (clenching, bruxism)
6. Moderate to severe malposition or crowding.

TYPES OF VENEERS

Direct veneers

Indirect veneers

Direct Veneers

Composite resin veneers which are free-hand placed.

Indirect Veneers¹⁴

1. Conventional powder-slurry ceramic (feldspathic porcelain). This type of porcelain is layered on the refractory die by the lab technician.
2. Heat-pressed ceramic. These products are melted at high temperatures and pressed into a mold created using the lost-wax technique (e.g. IPS Empress 1 and 2, OPC).
3. Machineable (CAD/CAM) ceramics (e.g. CEREC).

Conventional Powder-slurry Ceramic (Feldspathic Porcelain)

Porcelain laminate veneers have undergone significant evolution. Nowadays, their use has expanded beyond a simple covering for anterior teeth to include coverage of coronal tooth structures. Feldspathic veneers are fabricated by layering glass-based (silicon dioxide) powder and liquid materials. Silicon dioxide, also referred to as silica or quartz, contains various amounts of alumina. When these

aluminum silicates are found naturally and contain various amounts of potassium and sodium, they are referred to as feldspars. Feldspars are primarily composed of silicon oxide (60-64%) and aluminum oxide (20-23%), and are typically modified in different ways to create glass that can then be used in dental restorations.^{3,15,16} Thus, porcelain veneer consists of fluorapatite crystals in an aluminum-silicate glass that may be layered on the core to create the final morphology and shade of the restoration. The fluorapatite crystals contribute to the optical properties of the veneering porcelain.³ Feldspathic porcelain provides great esthetic value and demonstrates high translucency, just like natural dentition. By using a layering and firing process, ceramists developed veneers that could be made as optically close to natural teeth as possible. Feldspathic porcelain's mechanical properties are low, with flexural strength usually from 60 to 70 MPa.¹⁵ Due to the nature of the glass matrix materials and the absence of core material, the veneering porcelains are much more susceptible to fracture under mechanical stress. Therefore, a good bond, in combination with a stiffer tooth substructure (enamel), is essential to reinforce the restoration.³

Feldspathic veneer is manufactured by means of sculpting powder/liquid. The esthetic value exhibited in these restorations is a result of this technique and, therefore, depends on the ceramist's ability to build depth of anatomy, color, and translucency into the restoration.^{15,16}

Heat-pressed Ceramic/Glass-based Ceramics

Glass ceramics may be ideally suited for use as anterior restorations. Their mechanical and physical properties have generally improved, including increased fracture resistance, improved thermal shock resistance, and resistance to erosion. Improvement in properties depends on the interaction of the crystals and glassy matrix, as well as on the size and amount of crystals. Finer crystals generally produce stronger materials. They may be opaque or translucent, depending on the chemical composition and percent crystallinity.^{3,15-17} Increased strength in glassy ceramics is achieved by adding appropriate fillers that are uniformly dispersed throughout the glass, such as aluminum, magnesium, zirconia, leucite, and lithium disilicate. For esthetic veneers, ceramics reinforced by leucite and lithium disilicate are commonly indicated for their optical properties and because they are acid-sensitive. Filler particles are added to the base glass composition to improve the mechanical properties and optical effects such as opalescence, color and opacity.¹⁸ The glass matrix is infiltrated by micron-size crystals of leucite and lithium disilicate, creating a highly filled glass matrix.^{3,15-18} The flexural strength depends on the shape and

volume of these crystals. This material can be translucent, even with the high crystalline content; this is due to the relatively low refractive index of the crystals. Both leucite and lithium disilicate are fabricated through a combination of lost-wax and heat-pressed techniques.^{3,17,18}

Machineable (CAD/CAM) Ceramics

Recent developments in dental CAD-CAM technology utilize special partially sintered ceramic (zirconia), glass-bonded ceramic ('Vitablock') or glass-ceramic ('ips.emax' lithium disilicate) formed into machinable blocks, which are fired again after machining. CAD/CAM restorations created with glass-ceramic CEREC technology appear to last well.³

TECHNIQUES

Preparation of Teeth

Although early concepts suggested minimal or no tooth preparation, current belief supports removal of varying amounts of tooth structure.^{19,20} Enamel reduction is required to improve the bond strength of the resin composite to the tooth surface. In doing so, the aprismatic surface of mature unprepared enamel, which is known to offer only a minor retention capacity, is removed.^{3,21} In addition and when possible, care must be taken to maintain the preparation completely in enamel, because the better the adhesion between the veneer and the prepared tooth, the better the stress distribution in the system enamel-composite-ceramic.³ Three types of preparation forms have been described for porcelain laminate veneers, namely, window, overlapped and feathered preparations.^{3,14,22} To date, there is no consensus as to which preparation type is more resistant to fracture. Therefore, the least invasive preparation with maximal preservation of enamel is advisable. The types of preparation differ only at the incisal region of the tooth. At the cervical third, the gingival margin of the veneer must be located at the same level as the gingival crest or lightly subgingival for the anterior teeth. In this region, it is difficult to obtain a preparation with suitable depth while preserving intact enamel; therefore, in this place, the wear must be approximately 0.3 mm. At the medium third, the preparation may achieve 0.5 to 0.8 mm. At the incisal third, the preparation may be modified. The options include the 'window' preparation, the most conservative and maintain enamel in incisal third, which results in a visible line between enamel, resin, and ceramic; in addition, the remaining structure is more prone to fracture. The other possibility is the 'feather' preparation, which recovers the incisal of the tooth, maintaining its format. The critical points of this technique are the difficulty in positioning the ceramic restoration at the moment of its cementation and

in matching the optical properties of the remaining incisal structure.¹⁸ So, to obtain adequate color properties at the incisal third of the laminate veneers, the preparation needs to allow a thickness of ceramic of 1.5 to 2.0 mm, and this is possible with the 'overlap' preparation. At the proximal region, the preparation must follow the papilla and extend until interproximal contact.^{3,8,14,22}

Substrate Treatment^{3,14}

The ceramic veneer technique includes the bonding of a thin porcelain laminate to the tooth surface, enamel and/or dentin, using adhesive techniques.

Substrate Treatment of Tooth Surface (Enamel and Dentin)

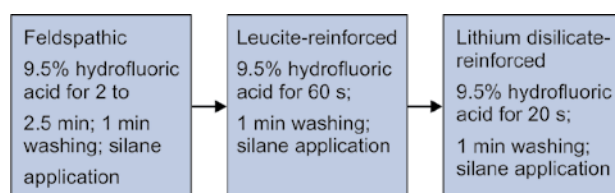
The enamel surface must be conditioned with phosphoric acid (37%). This procedure increases the surface energy of the structure, which leads to a perfect wetting of the surface with the bond. While the etching of enamel with phosphoric acid leads to a 'frosty' surface – a sign of a successful procedure, because of its inorganic composition and perfect etchability. Different kinds of dentin-bonding agents deal with surface wetness and the obtaining of a hybrid zone. Sealing this structure with a dental bonding agent is suggested immediately after the completion of tooth preparation and before the final impression itself²³ because the newly prepared dentin is ideal for the adhesion.^{23,24} This technique, called the 'resin-coating technique,' consists of interposing a layer of low viscosity resin between the dental substrate and the luting cement. The use of a conventional adhesive with three steps or autoconditioning with two steps, with polymerization of the adhesive separated from the composite resin.²⁴⁻²⁷

Substrate Treatment Ceramic

Effective etching of the ceramic surface is considered an essential step for the clinical success. Alteration of the surface topography by etching will result in changes in the surface area and in the wetting behavior of the porcelain. This may also change the ceramic surface energy and its adhesive potential to resin. The treatment of the ceramic surface is different according to its composition.^{3,24}

Acid conditioning with hydrofluoric acid is efficient in removing superficial defects and rounding off the remaining flaw tips, thereby reducing stress concentrators and increasing the overall strength. Silanization of etched porcelain with a bifunctional coupling agent provides a chemical link between the luting resin composite and porcelain. A silane group at one end chemically bonds to the hydrolyzed silicon dioxide at the ceramic surface and a methacrylate group at

Flow Chart: Ceramic surface treatment protocols



the other end copolymerizes with the adhesive resin. Single-component systems contain silane in alcohol or acetone and require prior acidification of the ceramic surface with hydrofluoric acid to activate the chemical reaction.²⁴ With two-component silane solutions, the silane is mixed with an aqueous acid solution to hydrolyze the silane, so that it can react directly with the ceramic surface.^{3,21}

Luting Cements

The clinical success of laminate veneers depends on the cementation of the indirect restorations (Flow Chart 1). The resin cements have good retention and resistance to fracture.

Luting cements may be classified into two subgroups: (1) cements associated with the use of conventional or self-etching adhesives, and (2) self-adhesive cements, which do not require any prior conditioning of the tooth structure.³

DISCUSSION

Porcelain veneers are a recent and very exciting development in the dental armamentarium. They enable the dentist to change the appearance, size, color, spacing, and to a minor extent, the positioning of the teeth. Many veneering procedures can be accomplished with little or no preparation of the natural dentition, and commonly, anesthesia is not required. The facial expression is the most common aspect of nonverbal communication, and any deformity or unappealing feature that greets the observer's eye is bound to influence, and perhaps bias, the messages that are received.^{1,3,8} We should always keep in mind that we are dealing with organs which can change an individual's entire visual personality. A captivating smile showing an even row of natural, gleaming white teeth is a major factor in achieving that elusive dominant characteristics known as personality. Porcelain laminate veneers offer a conservative approach to restoring anterior teeth. The incorporation of ceramic veneers has resulted in restorations with improved strength, durability, periodontal health preservation, marginal integrity, wear resistance and color match and stability.^{1,3,8,21,22}

CONCLUSION

Ceramic laminate veneers have been developed as one of the best methods for conservative anterior esthetic restorations. In comparison to other veneer materials like composite

resin, ceramic laminates offer various advantages like: color stability, life like translucency, high strength, resistance to abrasion, enhanced bond strength. Therefore, based on this literature review, it is possible to conclude that the clinical success of laminate veneers depends on both the suitable indications of the patient and the correct application of the materials and techniques available for that, in accordance with the necessity and goals of the esthetic treatment.

REFERENCES

1. Mathew CA, Mathew S, Karthik KS. A review on ceramic laminate veneers. *JIADS* 2010;1:33-37.
2. Radz GM. Minimum thickness anterior porcelain restorations. *Dent Clin North Am* 2011;55(2):353-370.
3. Pini NP, Aguiar FHB, Lima DAN, Lovadino JR, Terada RS, Pascotto RC. Advances in dental veneers: materials, applications and techniques. *Clinical, Cosmetic and Investigational Dentistry* 2012;4:9-16.
4. Belsler UC, Magne P, Magne M. Ceramic laminate veneers: continuous evolution of indications. *J Esthet Dent* 1997;9: 197-207.
5. Pincus CL. Pincus principles. In: Goldstein RE, Haywood VB, editors. *Esthetics in dentistry*. 2nd ed. Hamilton. Ontario: BC Decker 2002;1:131.
6. Buonocore MGA. Simple methods of increasing the adhesion of acrylicfilling materials to enamel surfaces. *J Dent Res* 1995; 34:849-853.
7. Goldstein R. Diagnostic dilemma: to bond, laminate or crown? *Int J Periodont Rest Dent* 1987;5:9-29.
8. Dhanda M, Srivastava M, Dobhal A, Sharma N. Ceramic laminate veneers: a conservative approach to esthetics. *IJDS* 2011;3:20-22.
9. Faunce FR, Myers DR. Laminate veneer restoration of permanent incisors. *J Am Dent Assoc* 1976;93:790-792.
10. Boyer DB, Chalkley Y. Bonding between acrylic laminates and composite resin. *J Dent Res* 1982;61:489-492.
11. Horn HR. Porcelain laminate veneers bonded to etched enamel. *Dent Clin North Am* 1983;27:671-684.
12. Calamia JR. Etched porcelain facial veneers: a New treatment modality based on scientific and clinical evidence. *NY State Dent J* 1983;53:255-259.
13. Hsu CS, Stangel I, Nathanson D. Shear bond strength of resin to etched porcelain. *J Dent Res* 1985;64:296.
14. Crest® Oral-B at dentalcare.com [Internet] Kugel G, Sharma S: Do's and Don'ts of porcelain laminate veneers. c2008 – [cited 2008 Dec 05]: Available from www.dentalcare.com/en-US/dental-education/continuing.../ce333.aspx
15. Giordano R, McLaren EA. Ceramics overview: classification by microstructure and processing methods. *Compend Contin Educ Dent* 2010;31(9):682-684.
16. Conrad HJ, Seong WL, Pesun IJ. Current ceramic materials and systems with clinical recommendations: a systematic review. *J Prosthet Dent* 2007;98(5):389-404.
17. Spear F, Holloway J. Which all-ceramic system is optimal for anterior for anterior esthetics? *J Am Dent Assoc* 2008;139:19-24.
18. Culp L, McLaren EA. Lithium disilicate: the restorative material of multiple options. *Compend Contin Educ Dent* 2010;31: 716-725.
19. Fradeani M, Redemagni M, Corrado M. Porcelain laminate veneers: 6 to 12 years clinical evaluation—a retrospective study. *Int J Periodontics Restorative Dent* 2005 Feb;25(1):9-17.
20. Calamia JR. Etched porcelain veneers: the current state of the art. *Quintessence Int* 1985 Jan;16(1):5-12.
21. Peumans M, Van Meerbeek B, Lambrechts P, Vanherle G. Porcelain veneers: a review of the literature. *J Dent* 2000 Mar;28(3):163-177.
22. Gresnigt M, Özcan M. Esthetic rehabilitation of anterior teeth with porcelain laminates and sectional veneers. *Canadian Dental Association* 2011;77:1-8.
23. Magne P, Douglas WH. Porcelain veneers: dentin bonding optimization and biomimetic recovery of the crown. *Int J Prosthodont* 1999;12:111-121.
24. Frankenberger R, Lohbauer U, Schaible RB, Nikolaenko SA, Naumann M. Luting of ceramic inlays in vitro: marginal quality of selfetch and etch and rinse adhesives versus selfetch cements. *Dent Mater* 2008;24:185-191.
25. Magne P, Woong-Seup S, Cascione D. Immediate dentin sealing supports delayed restoration placement. *J Prosthet Dent* 2007;98:166-174.
26. Jayssoiya PR, Pereira PN, Nikaido T, Tagami J. Efficacy of resin coating on bond strengths of resin cement to dentin. *J Esthet Restor Dent* 2003;15:105-113.
27. Udo T, Nikaido T, Ikeda M, et al. Enhancement of adhesion between resin coating materials and resin cements. *Dent Mat* 2007;26(4):519-525.

ABOUT THE AUTHORS

Nitesh Shetty

Professor, Department of Prosthodontics, Century Dental College Poinachi, Kasargod, Kerala, India

Savita Dandakeri

Professor, Department of Prosthodontics, Yenepoya Dental College Mangalore, Karnataka, India

Shilpa Dandakeri (Corresponding Author)

Lecturer, Department of Prosthodontics, AB Shetty Memorial Institute of Dental Sciences, Mangalore, Karnataka, India, Phone: 9008150986 e-mail: dandakeri@gmail.com