

Peripheral Giant Cell Granuloma in 9-Year-Old Female Patient

Jalark Chimanbhai Patel, Sunanda Gul Sujan, Anshula Neeraj Deshpande, Bhavna H Dave

ABSTRACT

The peripheral giant cell granuloma (PGCG) is a benign hyperplastic gingival lesion of unknown etiology occurring mostly in adults. However, it is less commonly seen in females with preponderance for fifth and sixth decade of the life. It is clinically difficult to distinguish PGCG from pyogenic granuloma, fibrous epulis or irritation fibroma. This article presents a case with exophytic gingival lesion in 9 years old female patient. This lesion was interfering with functions and altering the esthetics. It is a challenge for the clinician to manage such type of pathologies in young children.

Keywords: Exophytic gingival lesion, Peripheral giant cell granuloma, Young children.

How to cite this article: Patel JC, Sujan SG, Deshpande AN, Dave BH. Peripheral Giant Cell Granuloma in 9-Year-Old Female Patient. *J Orofac Res* 2013;3(2):148-151.

Source of support: Nil

Conflict of interest: None declared

INTRODUCTION

Peripheral giant cell granuloma (PGCG) is a reactive, exophytic gingival lesion of the oral cavity, also known as giant cell epulis, osteoclastoma or giant cell hyperplasia. It is relatively uncommon lesion of the gingiva or alveolar mucosa and is considered to be reactive in nature.¹

PGCG originates mainly from the connective tissue of the gingiva, periodontal membrane or periosteum of the alveolar ridge.² Since the reparative response is quite rare, the term 'peripheral giant cell granuloma' is currently preferred and universally accepted.

Some studies have shown the highest occurrence of PGCG in females than males (1.2:1), commonly involves mandible than maxilla (54.5%) and more chances of the occurrence during the fourth to sixth decades of the life (average: 43.2 years).³ PGCG is a tumor like pathologic condition arising on the buccal or lingual attached gingival or alveolar mucosa and the crest of the edentulous alveolar ridge of uncertain etiology.

Sometimes bleeding and discomfort is seen with this kind of situation which creates anxiety to the patient and psychological trauma to the parents. It is a challenge for the clinician to manage this type of condition in young patients and making a proper management plan for successful outcome of the treatment.

CASE REPORT

A 9-year-old female patient reported to the Department of Pedodontics and Preventive Dentistry, KM Shah Dental College and Hospital, Vadodara with a chief complaint of growth in the lower right posterior region from last 25 days and had difficulty while chewing. Medical and family history was noncontributory.

History revealed that the growth was noticed 25 days back, it grew in size gradually. There was negative history of the associated symptoms such as pain, paresthesia or bleeding. Patient gave the history of food lodgement in mandibular right deciduous 1st and 2nd molars. It was revealed by the patient that the food lodgement irritated her and for relieving this discomfort she used wooden sticks (toothpicks) to remove the food lodgement.

Extraoral examination did not reveal any abnormalities. Intraoral examination revealed a well defined reddish, nontender, soft pedunculated oval-shaped gingival growth measuring $1.3 \times 1 \text{ cm}^2$ in relation to mandibular right primary 1st molar, extending from the middle aspect of the mandibular right primary canine to mesial aspect of the mandibular right primary 2nd molar (Fig. 1). The lesion appeared to arise from the underlying soft tissue and no bleeding or ulceration was present on the lesion (Fig. 2).

Based on the history and clinical findings the following differential diagnosis was made: focal fibrous hyperplasia, PGCG and pyogenic granuloma. Then patient was advised for necessary radiographic and hematological investigation.

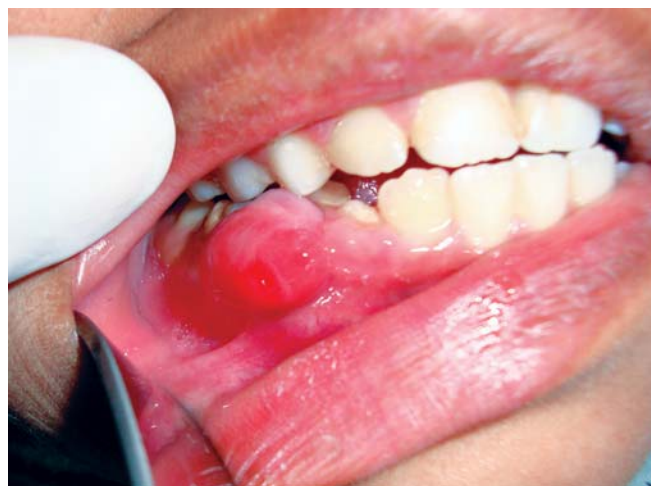

Fig. 1: Intraoral view of the lesion

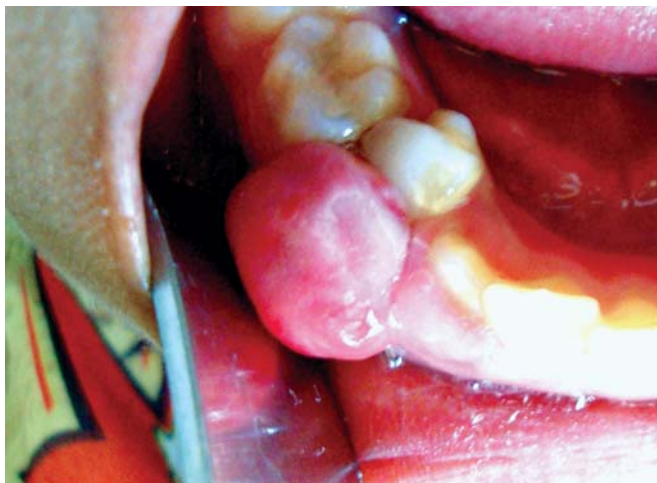

Fig. 2: Occlusal view of the lesion

The patient was referred to the Department of Pediatrics for hematological checkup. Hematological reports were within normal limits except hemoglobin (Hb: 8.7 gm%). The intraoral periapical radiograph did not reveal any pathological changes except for the natural resorption of the roots of mandibular right primary 1st molar.

The treatment plan was discussed and formulated. As the patient had low level of Hb, she was advised for additional iron supplements (Haem-up Syrup: 2 teaspoon bid). After completion of 15 days again blood reports were advised. The reports showed normal Hb level in blood (Hb: 11.4 gm%).

First of all oral prophylaxis and fluoride application was done. Then the lesion was surgically excised with its surrounding tissues by scalpel and curetted followed by extraction of the mandibular right primary 1st molar under local anesthesia in the same visit (Fig. 3). The bleeding was controlled by placing pressure gauze and abgel followed by analgesics medicine and postsurgical instructions were given to the patient as well the parents (Figs 4 and 5). The

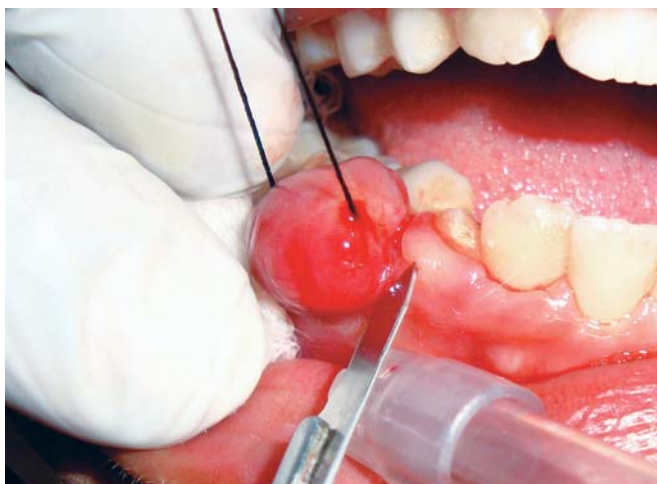

Fig. 3: Surgical removal of the lesion with scalpel

patient was recalled after 7 days for further follow-up and restorative treatments (Fig. 6).

The excised lesion was sent to the Department of Oral Pathology for further histological examinations. Histological examination was done and reported that it consists of a nonencapsulated mass of tissue composed of a delicate reticular or fibrillar connective tissue stroma (Fig. 7). There is also presence of large numbers of ovoid or spindle-shaped young connective tissue cells and multinucleated giant cells in medullary as well as core region. The histopathological report confirmed that the lesion was PGCG.

DISCUSSION

PGCG is seen in young as well as in the elderly population with highest incidence in 4th to 6th decades of life.^{2,3} However, 20 to 30% of cases manifest in the 1st and 2nd decades of life.⁴ The preferential location of the lesion according to Pindborg⁵ is the premolar and molar zone, though Shafer⁶ and Giansanti⁴ suggest that it generally occurs in the incisor and canine region.

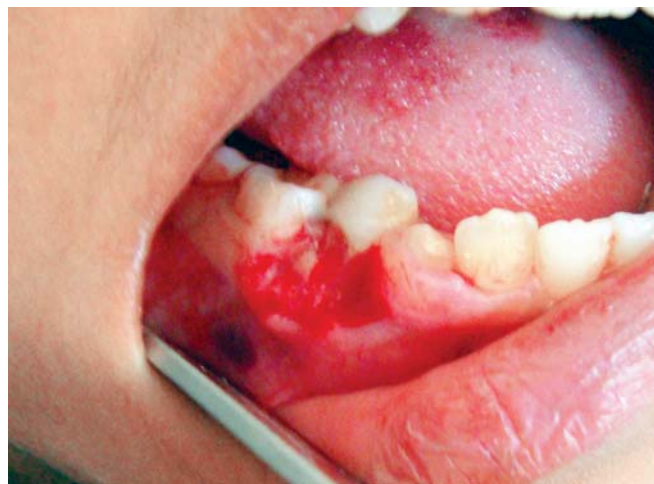

Fig. 4: Fresh bleeding after excision of the lesion

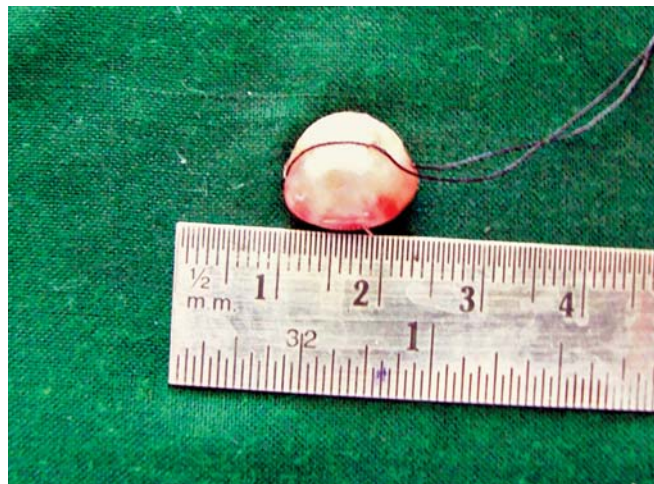

Fig. 5: Excised lesion of peripheral giant cell granuloma

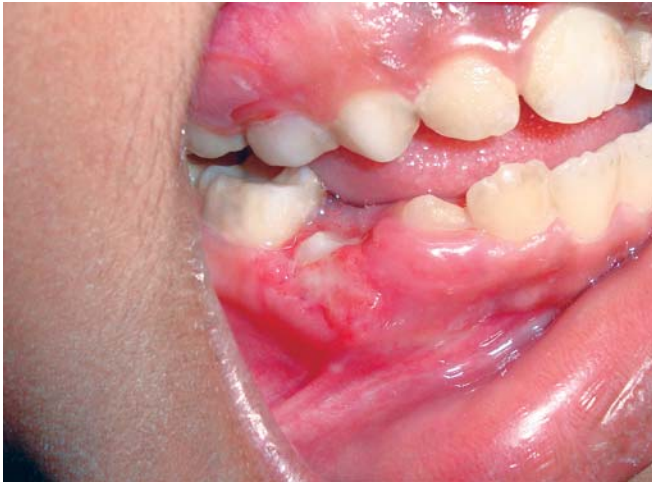

Fig. 6: Postoperative photograph shows uneventful healing after 7 days

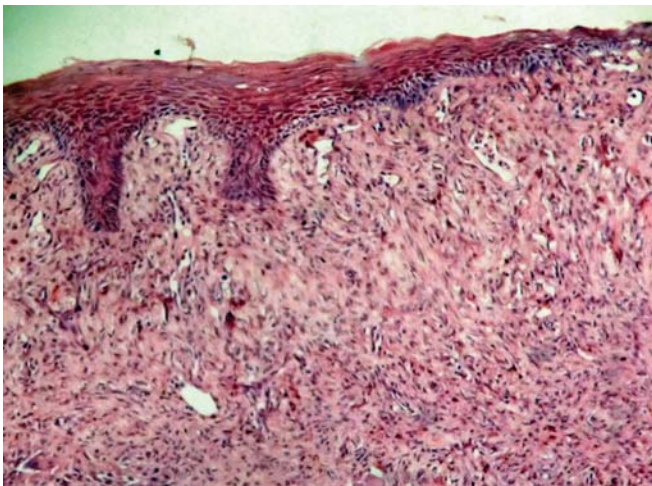


Fig. 7: Histological image of the PGCG (original magnification $\times 100$ and H&E stain was used)

Gingival lesions in children that mimic the PGCG are the pyogenic granuloma, gingival epulis and irritation fibroma or focal fibrous hyperplasia.^{7,8} The pyogenic granuloma presents a soft, friable nodule that bleeds freely with minimal manipulation. Another erythematous nodule of the gingiva is the parulis which is associated with an entrapped foreign body, a gingival pocket or a nonvital tooth. Pain and expression of purulent exudates with fluctuation in lesion size help to differentiate this inflammatory disease from the PGCG.

The etiology of PGCG is not clearly known. Evidence suggests that it is not a true neoplasm but rather a benign hyperplastic reactive lesion originating from the periodontal ligament or mucoperiosteum caused by local irritation or chronic trauma. The local etiological factors may include traumatic extractions, poorly contoured dental restorations, food impaction, plaque and tartar, etc.⁹⁻¹¹ Reversely as they

bear close resemblance to the central giant cell granuloma it is also believed that it represents soft tissue counterpart of the bony lesion and considered to originate secondary to an abnormal proliferative response.¹

Clinically they occur exclusively on the gingiva or edentulous alveolar ridge and mandible is more commonly affected than maxilla at a proportion of about 2.4:1.¹² Generally the size of the lesion can vary from 0.5 to 1.5 cm in diameter; most lesions are smaller than 2 cm in diameter and larger than those are seldom seen.¹³ Whereas, in rare cases, giant cell granuloma may be associated with hyperparathyroidism and at times it can be the sole manifestation.²

Treatment of PGCG includes elimination of the etiological factor and complete surgical resection of the lesion with or without removal of the associated tooth.^{1,6} More recently resection has been tried out with cold scalpel, electrocautery and carbon dioxide lasers.¹³ The characteristic feature of PGCG is that recurrence is frequent and is observed in 5 to 11% of cases, hence complete resection and curettage is required to avoid recurrence.¹¹

CONCLUSION

PGCG is a disease encountered often in the adult population. It is rarely found in children and represents only a small proportion of the hyperplastic gingival lesions. Careful examination of the oral mucosa is important to identify such type of reactive lesions. Early definite diagnosis of PGCG on the basis of clinical, radiographical and histopathological examination allows conservative management with minimal risk to the adjacent hard tissues.

REFERENCES

1. Neville BW, Damm DD, Allen CM, Bouquot JE. Oral and maxillofacial pathology. Pennsylvania: WB Saunders Company 2004:449-50.
2. Katsikeris N, Kakarantza-Angelopoulou E, Angelopoulou AP. Peripheral giant cell granuloma: Clinicopathologic study of 224 new cases and review of 956 reported cases. *Int J Oral Maxillofac Surg* 1988;17:94-99.
3. Buchner A, Shapiro AS, Vered M. Relative frequency of localized reactive hyperplastic lesions of the gingiva: A retrospective study of 1675 cases from Israel. *J Oral Pathol Med* 2010;39:631-38.
4. Giansanti JS, Waldron CA. Peripheral giant cell granuloma: A review of 720 cases. *J Oral Surg* 1969;27:787-91.
5. Pindborg JJ. Atlas de enfermedades de la mucosa oral (5th ed). Barcelona: Ediciones Cientificas Tecnicas 1994:186.
6. Shafer WG, Hine MK, Levy BM. A textbook of oral pathology (4th ed). Philadelphia: WB Saunders Company 1983:144-46.

7. Kfir Y, Büchner A, Hansen LS. Reactive lesions of the gingiva. A clinicopathological study of 741 cases. *J Periodontol* 1980;51:655-61.
8. Anneroth G, Sigurdson A. Hyperplastic lesions of the gingival and alveolar mucosa: A study of 175 cases. *Acta Odontol Scand* 1983;41:75-86.
9. Pandolfi PJ, Felefl S, Flaitz CM, Jhonson JV. An aggressive peripheral giant cell granuloma in a child. *J Clin Pediatr Dent* 1999;23:353-55.
10. Bhaskar NS, Cutright DE, Beasley JD, Pérez B. Giant cell reparative granuloma (peripheral): Report of 50 cases. *J Oral Surg* 1971;29:110-15.
11. Eversole LF, Rovin S. Reactive lesions of the gingiva. *J Oral Pathol* 1972;1:30-38.
12. Reichart PA, Philipsen HP. *Atlas de patología oral*. Barcelona: Masson 2000:164.
13. Chaparro AV, Berini AL, Escoda CG. Peripheral giant cell granuloma. A report of five cases and review of the literature. *Med Oral Pathol Oral Cir Bucal* 2005;10:48-57.

ABOUT THE AUTHORS

Jalark Chimanbhai Patel (Corresponding Author)

Postgraduate Student, Department of Pedodontics and Preventive Dentistry, KM Shah Dental College and Hospital, Vadodara, Gujarat India, Phone: 9974132646, e-mail: jalarkpatel@ymail.com

Sunanda Gul Sujan

Professor, Department of Pedodontics and Preventive Dentistry, KM Shah Dental College and Hospital, Vadodara, Gujarat, India

Anshula Neeraj Deshpande

Professor, Department of Pedodontics and Preventive Dentistry, KM Shah Dental College and Hospital, Vadodara, Gujarat, India

Bhavna H Dave

Professor, Department of Pedodontics and Preventive Dentistry, KM Shah Dental College and Hospital, Vadodara, Gujarat, India