

Augmentation of Acquired Defect of the Forehead with Subperiosteal Silicone Implant

Rijesh Krishnan, Ramesh Chetty, Ram Prakash

ABSTRACT

The need to look normal is a universal need. To be more than normal, i.e. to look exceptional is also possible now due to availability of various surgical and nonsurgical methods available to common people to either remove signs of old age or to enhance the present appearance. The technology for these procedures like nose lifts, chin augmentation, wrinkle removal, breast enhancements, etc. has advanced in leaps and bounds. The positive side of such technology is its use in case of disfigurement due to trauma. When a person experiences trauma, the appearance may be compromised. But corrections of such disfigurement have become routine surgical practice. The use of hard and soft alloplastic materials is also very much the norm. The following case presentation is about a patient with a concave defect on his forehead. This concave defect was augmented with a preshaped silicone implant. This silicone was preshaped with reference to a contoured acrylic mold that was made on a facial moulage of the patient. As it was contoured on the moulage, it represented the exact need of the patient and hence the surgery was done just to place it subperiosteally. The result was a patient with minimal pain and less morbidity.

Keywords: Silicone implant, Facial sculpting, Restoration of facial deformity, Trauma deformity, Custom-shaped silicone implant, Esthetic correction, Soft tissue recontouring, Facial moulage.

How to cite this article: Krishnan R, Chetty R, Prakash R. Augmentation of Acquired Defect of the Forehead with Subperiosteal Silicone Implant. *J Orofac Res* 2013;3(1):72-75.

Source of support: Nil

Conflict of interest: None declared

INTRODUCTION

Esthetic transformation of the body is an art practiced since time immemorial. The concept of beauty has changed from time to time and from civilization to civilization. To attain their goal of esthetic needs, various procedures to enhance one's person have been practiced since advent of civilization. Though most of the procedures have been temporary in nature, more permanent transformations for esthetic needs have also been documented. Such procedures apart from transforming a normal person to more esthetically pleasing looks, they have been consistently used on less fortunate people with distorted appearance to look more normal.

To remove a growth surgically is usually a simple procedure. The challenge arises when a deficient anatomy has to be enhanced to appear more normal and pleasing. Before the advent of biocompatible materials, these anatomical defects were usually covered from view with a

mask or such. With the advent of biocompatible materials, the field of surgical enhancement of deficient anatomy has been revolutionized.¹

Augmentation can be accomplished with synthetic fillers, autologous grafts, soft tissue repositioning techniques, and/or alloplastic implants. Only alloplastic implants, however, provide truly long-term volumetric correction.² In the middle of 20th century, polyethylene (a material used in insulation of electric cables in planes) was used as a cranioplasty material. Especially, it was easy shapeable and build with heat, made this material popular.³

Silicon was proposed as a cranioplasty material in 1968. Use of silicone implant is documented extensively for recontouring of various anatomical structures to bring about both functional and esthetic modifications. Solid silicone augmentation mentoplasty is a common procedure with consistent esthetic results in properly selected patients.⁴

CLINICAL REPORT

This patient presented with a concave defect on the left portion of his forehead. Interview with the patient revealed a history of trauma which was operated on by the Orthopedic Surgery ward. Following this, the patient was asymptomatic from his trauma wound. On examination, a defect that was monocortical, this presented as a concave defect on his forehead. The patient wanted the contour of his forehead corrected (Fig. 1). Following this, the Department of Plastic Surgery, sought the help of Department of Prosthodontics.

The patient did not want any costly and lengthy procedures and he was phobic about any autogenous bone graft harvesting procedures. So, this left only an option of heterograft or alloplastic materials. Correction with contoured plates and screws tended to be costly which was unacceptable for the patient. After careful deliberation, it was decided by the plastic surgeons to plump up the defect with silicone which was characterized, a scenario similar to chin enhancement was visualized.¹ A silicone sheet was meant to be shaped and contoured such that the defect area would be filled.

CLINICAL PROCEDURES

A procedure similar to that explained by Carruthers et al⁵ and Chen et al⁶ was planned. Instead of fillers, a preshaped and contoured silicone implant was planned.

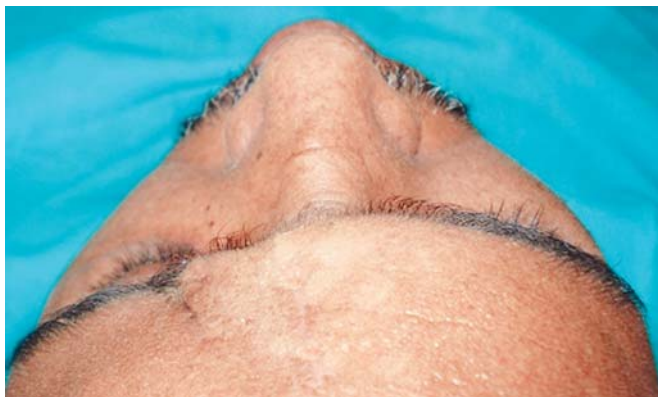

Fig. 1: Presurgical photograph



Fig. 2: Presurgical moulage

The prosthetic part involved in getting a facial moulage of the patient. The facial impression of the patient was made using irreversible hydrocolloid (Jeltrate).

To begin with a straw was placed in the patient's mouth to enable him to breathe when the nose was covered with the irreversible hydrocolloid. Then two pellets of moist cotton were placed in the nostrils to prevent the irreversible hydrocolloid from getting inside and irritating the nasal cavity. The patient was advised to have the eyes closed through the procedure. Then five different mixes of irreversible hydrocolloid was made simultaneously using the water powder ratio given by the manufacturer. The simultaneous mix was important because, the material will tend to form layers if it was mixed separately, which will lead to imperfect impression. The mix so obtained was applied on the patient's face, care taken to adapt it to all the anatomical landmarks that was required. A few bits of set plaster and some gauze was placed on the surface. After the irreversible hydrocolloid is set, a layer of dental plaster (Kaldent, Kalabhai, India) was applied on the surface, to about 5 mm thickness, this layer will act as a custom tray. After this plaster set, the whole impression was removed. The plaster bits and gauze placed on the surface of the irreversible hydrocolloid aided in retention of the plaster to the irreversible hydrocolloid. The impression was inspected for details and then cast was poured using type 3 gypsum product (Kalstone, Kalabhai, India) and the moulage (Fig. 2) was retrieved.

The area of the defect was analyzed. The change in contour was compared with the contralateral side which was normal in appearance. Wax was used to fill and contour the defect. This wax was processed with heat-cured acrylic (Fig. 3). The acrylic stent was checked on the moulage for fit and accuracy. Then the acrylic stent was sterilized.

The acrylic stent was used as a template to shape and contour a carving block of silicone (Implantech silicone—rectangular carving block size 3) (Fig. 4). Then, this reshaped silicone implant was given to the plastic surgeon.

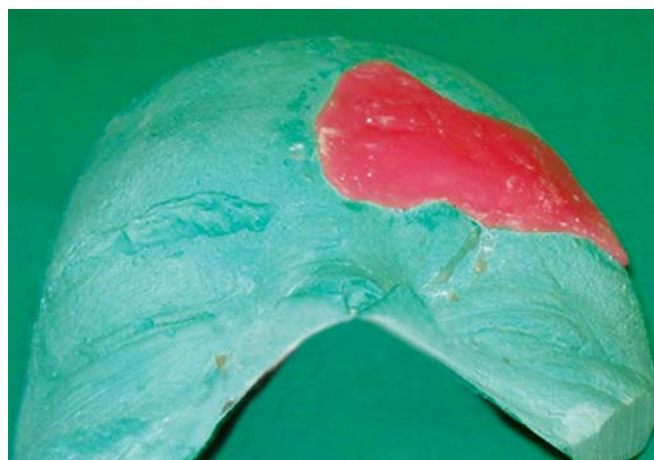


Fig. 3: Moulage with acrylic stent

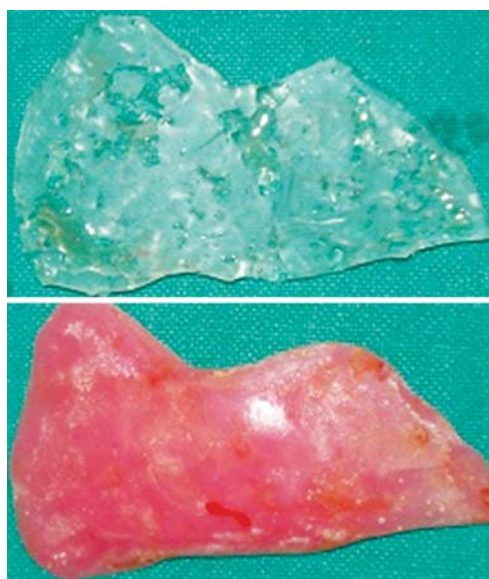

Fig. 4: Silicone-shaped like the stent

The surgical part was handled by the plastic surgeon. A vertical incision was made lateral to the defect, till the subperiosteal level. Subperiosteal tunneling was done on the area of the defect from the incision. The precontoured silicone implant was inserted and placed subperiosteally (Fig. 5). The contour of the forehead was checked before

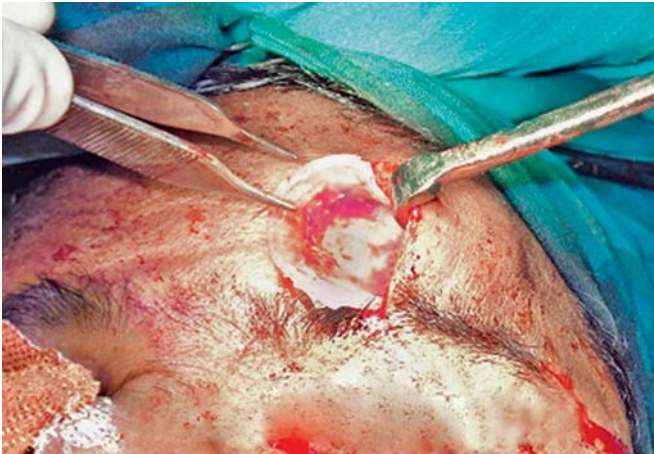

Fig. 5: Surgery-implant placement

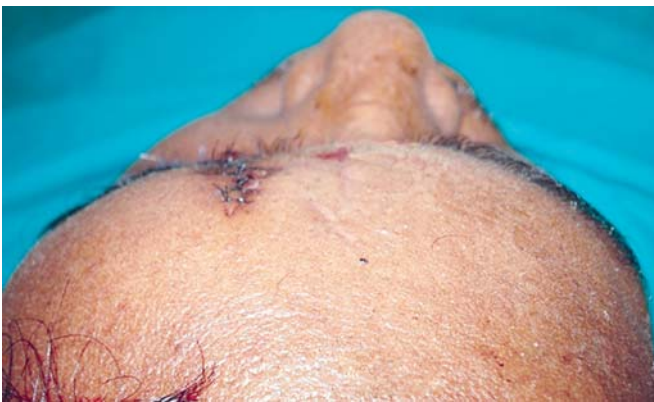

Fig. 6: Post-surgical photograph

suturing. The implant was anchored in position with an internal suture to the periosteum and the surrounding soft tissue, similar to the technique proposed by Barutcu.⁷

Postsurgery, the contour of the forehead was improved visibly (Fig. 6). The patient was advised not to lay down on his left and to keep the treated site as stress free as possible.

DISCUSSION

Usually bony disfigurement of the face requires complex surgical procedures involving autografts, plates, screws and membranes which is costly and also requires practitioners with special skills. Furthermore, the morbidity of autograft harvesting procedure is also high. This case depicts a situation, where minimal surgery was done to bring about the desired effect.

Many authors have proposed surgical procedures for face lift involving the forehead as it is a key feature for recognition of ageing.^{8,9} Mostly they involve plumping up the volume of the forehead.¹⁰ But usually, fillers were used. These were in minimal quantity, just enough to smooth out the wrinkles. But our patient needed a significant volume concentrated in a particular area; hence, a more firm alternative was planned.¹¹

The use of preformed and personalized silicone implants have been well documented for chin enhancements and full face lift procedures.^{12,13} So, a similar scenario was envisioned and planned for. As these preformed silicone implants are costly, a more cost effective use of carving blocks of silicone which are then shaped to the desired dimension was used.

The procedure was simple and needed minimal invasive surgery, but brought about an acceptable esthetic result.

SUMMARY

A case of concave bony defect of the forehead is presented. Customarily, such defects are corrected with a combination of autografts and plates and screws which tended to be costly and time consuming. As the patient wanted only esthetic correction and was phobic to autograft harvesting procedures, a minimally invasive procedure to place a preshaped silicone implant to plump up the defect was planned. The shaping of the silicone implant was done using an acrylic stent.

A facial moulage was made on which modeling wax was used to contour the defect and then this was processed using self-cure acrylic which formed the stent. A carving block of silicone (Implantech silicone—rectangular carving block size-3) was shaped using the stent as reference.

In the surgical phase, a vertical incision was made lateral to the defect, and the area of defect was tunneled subperiosteally. Then the shaped silicone implant was placed and held with a suture to the periosteum. Then after careful inspection of the desired contour, the incision was sutured.

On postsurgical evaluation, the defect was properly filled and the contour of the forehead was restored satisfactorily.

REFERENCES

1. Lamb J. Volume rejuvenation of the face. *Mo Med* 2010 May-Jun;107(3):198-202.
2. Hopping SB, Joshi AS, Tanna N, Janjanin S. Volumetric facelift: Evaluation of rhytidectomy with alloplastic augmentation. *Ann Otol Rhinol Laryngol* 2010 Mar;119(3):174-80.
3. Romo T 3rd, Baskin JZ, Sclafani AP. Augmentation of the cheeks, chin and pre-jowl sulcus, and nasolabial folds. *Facial Plast Surg* 2001 Feb;17(1):67-78.
4. Aynehchi BB, Burstein DH, Parhiscar A, Erlich MA. Vertical incision intraoral silicone chin augmentation. *Otolaryngol Head Neck Surg* 2012 Apr;146(4):553-59.
5. Carruthers JD, Carruthers A. Facial sculpting and tissue augmentation. *Dermatol Surg* 2005 Nov;31(11 Pt 2):1604-12.
6. Chen CT, Hu TL, Lai JB, Chen YC, Chen YR. Reconstruction of traumatic nasal deformity in Orientals. *J Plast Reconstr Aesthet Surg* 2010 Feb;63(2):257-64.
7. Barutcu A. A new method for rigid fixation of silicone implants. *Plast Reconstr Surg* 1994 May;93(6):1286-89.
8. Rose AE, Day D. Esthetic rejuvenation of the temple. *Clin Plast Surg* 2013 Jan;40(1):77-89.

9. Pavicic T, Gauglitz GG. Modern soft tissue augmentation—away from treating the single fold to volume replacement in the whole face. *MMW Fortschr Med* 2012 Sep 10;154(15):51-52, 54.
10. Lorenc ZP. Techniques for the optimization of facial and nonfacial volumization with injectable poly-L-lactic acid. *Aesthetic Plast Surg* 2012 Oct;36(5):1222-29.
11. Montes JR. Volumetric considerations for lower eyelid and midface rejuvenation. *Curr Opin Ophthalmol* 2012 Sep;23(5):443-49.
12. Pitanguy I. Facial cosmetic surgery: A 30-year perspective. *Plast Reconstr Surg* 2000;104:1517-26.
13. Yaremchuk MJ, Doumit G, Thomas MA. Alloplastic augmentation of the facial skeleton: An occasional adjunct or alternative to orthognathic surgery. *Plast Reconstr Surg* 2011;127:2021-30.

ABOUT THE AUTHORS

Rijesh Krishnan (Corresponding Author)

Reader, Department of Prosthodontics, Adhiparasakthi Dental College Melmaruvathur, Tamil Nadu, India, e-mail: rijeshkris@gmail.com

Ramesh Chetty

Professor, Department of Prosthodontics, Adhiparasakthi Dental College, Melmaruvathur, Tamil Nadu, India

Ram Prakash

Professor, Department of Prosthodontics, Sree Sai Dental College Hyderabad, Andhra Pradesh, India

SUBSCRIPTION INFORMATION

Annual Subscription

Individual:	₹ 3500.00	(National)
	\$ 200.00	(International)
Institutional:	₹ 5000.00	(National)
	\$ 280.00	(International)

Subscription can be sent to

M/s Jaypee Brothers Medical Publishers (P) Ltd

Journals Department

Jaypee Brothers Medical Publishers (P) Ltd

4838/24 Ansari Road, Daryaganj

New Delhi 110 002, India

Phone: +91-11-43574357

Fax: +91-11-43574314

e-mail: journals@jaypeebrothers.com

This journal is published quarterly in a year, i.e. March, June, September and December. Dollar rates apply to subscribers in all the countries except India where INR price is applicable. All subscriptions are payable in advance and all the rates include postage. Journals are sent by air to all the countries except Indian subcontinent. Subscriptions are on an annual basis, i.e. from January to December. Payment will be made by dollar cheque, credit card or directly through our bank account at the following address:

1. Our Banker's Name: Canara Bank, Netaji Subhash Marg
Darya Ganj, New Delhi 110 002
2. Telephone No: 011-23273015, 011-23273849
3. Fax No: 011-23255606
4. Telex No: 3166291
5. Our Current A/c No: **3828**
6. Amount to be Transferred
in the Name of: JAYPEE BROTHERS MEDICAL
PUBLISHERS (P) LTD, NEW DELHI
7. Swift Code No: CNRB IN BB DFM

For further queries, please do not hesitate to contact at subscriptions@jaypeejournals.com

ADVERTISEMENT RATES

(For the Print Issues)

Page

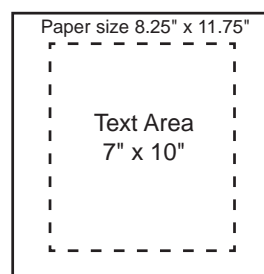
Single Issue

Back cover—color	₹ 50,000	\$ 1000
Inside front cover—color	₹ 40,000	\$ 800
Inside back cover—color	₹ 35,000	\$ 700
Inside full page—color	₹ 30,000	\$ 600

Special position: **Price on request**

Technical Details

Paper size	8.25 x 11.75 inches
Print size	7 x 10 inches
Digital file format	EPS on CD (at 300 dpi resolution)
Printed on art paper using offset printing.	



Schedule

Issues are published in the months of March, June, September and December.

Advertisement material along with purchase order and payment should reach us at least four weeks prior to the scheduled print date.

Payment Details

- Payment should favour "Jaypee Brothers Medical Publishers (P) Ltd." and should be payable at New Delhi, India.
- Payment to be done at the time of submitting the advertisement material/booking the advertisement. Please send your advertisement request, payment and advertisement material to the address given above. Editorial board reserves the right to accept or decline the advertisement.

For further queries, please contact advertisements@jaypeejournals.com