

# A Time Saving Method to Fabricate a Custom Ocular Prosthesis

Sandeep Chiramana, Gopinadh Anne, Kavya Ravuri, Phani Praneetha Boppana, Sampath Kumar, Krishna Chaitanya Appana

## ABSTRACT

Ocular prostheses have a long history of successful use. Several variations of the techniques and materials used have been proposed before. The replication of the natural iris by oil painting requires skill and also takes a lot of time. In this article some alternate procedures have been presented to save time while fabrication of a custom ocular prosthesis. Digital photography was used to replicate the iris of the patient, replacing the conventional oil paint technique. Advantages, such as reduced treatment time and increased simplicity make this method an alternative for fabricating ocular prostheses.

**Keywords:** Ocular prosthesis, Custom-made, Digital iris image, Time saving.

**How to cite this article:** Chiramana S, Anne G, Ravuri K, Boppana PP, Kumar S, Appana KC. A Time Saving Method to Fabricate a Custom Ocular Prosthesis. *J Orofac Res* 2013; 3(1):42-45.

**Source of support:** Nil

**Conflict of interest:** None declared

## INTRODUCTION

‘Eyes are the windows to the soul’ and they are generally the first features of the face to be noted. An important component of facial expression, the vital organ of vision has been given a paramount status for beauty. The loss or absence of the eye, due to irreparable trauma, tumor, a painful blind eye, sympathetic ophthalmia, or a congenital defect<sup>1</sup> leaves a person grappling not only with a functional disability but also the discouraging effect of impaired facial esthetics.

The importance of an ocular prosthesis with acceptable esthetics and reasonable motility in restoring normal appearance in patients with anophthalmia has long been recognized. Artificial eyes have been in existence since the very early times in Egypt before 3000 BC and the materials used varied from clay, leather and cloth to precious gems. It was only in the 16th century that the prosthesis was made to fit into a socket. Frenchman Ambroise Pare, a pioneer of maxillofacial prosthodontics was the first to use both glass and porcelain eyes. Artificial glass eyes were later replaced by acrylic during and after the two world wars.<sup>2</sup>

Several techniques have been used in fitting and fabricating artificial eyes. Empirically fitting a stock eye, modifying a stock eye by making an impression of the ocular

defect, and the custom eye technique are the most commonly used techniques.<sup>3</sup> The fabrication of a custom acrylic resin eye provides more esthetic and precise results because an impression establishes the defect contours, and the iris and the sclera are custom fabricated and painted.<sup>1</sup> The traditional method of painting the iris demands skill as well as time. Use of a digital image of the iris of the adjacent normal eye to duplicate the iris color and its intricacies gives better esthetics in a fraction of the time required for painting the iris.<sup>1</sup>

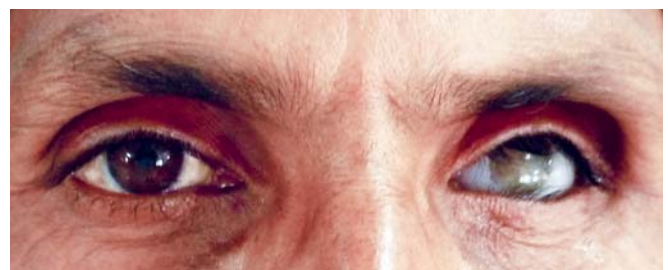This case report describes a custom fitted ocular prosthesis using a digital image of the natural eye.

## CLINICAL REPORT

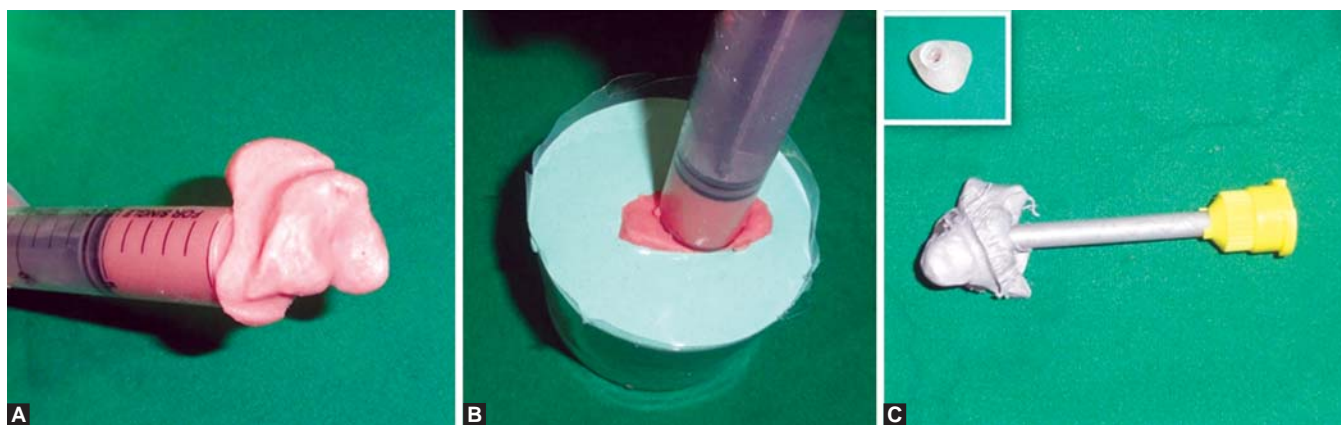
A 40-year-old male patient reported to the Department of Prosthodontics, Sibar Institute of Dental Sciences, with a chief complaint of unsatisfactory esthetics of his stock ocular prosthesis. According to the reports from the ophthalmic surgeon, he had undergone enucleation of his left eye following a complication of snake bite 10 years ago and had been rehabilitated with a stock ocular prosthesis in a private clinic.

On examination, it was observed that the whole eyeball was surgically excised, but the muscles at the base of the socket were intact. The existing prosthesis had poor retention and did not match the opposite eye (Fig. 1).

A 5 ml disposable syringe without the needle was used to record the defect using irreversible hydrocolloid impression material (Fig. 2A). The impression obtained was invested in a small bowl of dental stone (type III gypsum product) (Fig. 2B). From the cast obtained, a custom tray was fabricated with clear acrylic (Fig. 2C, Inset). This tray was adapted to the tip of an elastomeric automixing syringe.



**Fig. 1:** Previous stock ocular prosthesis

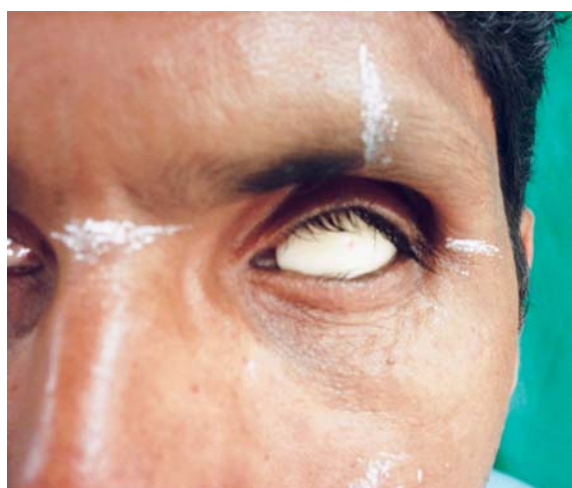

**Figs 2A to C:** Impression making

The final impression was made with light body elastomeric material (Affinis, Coltene Whaledent) (Fig. 2C).

The impression was then invested in irreversible hydrocolloid and modeling wax was melted and poured into the mold space after removing the impression material. This helped in obtaining the scleral wax pattern almost immediately. The wax pattern was placed into the defect and evaluated for esthetics and comfort following which, the iris plane and pupil point were evaluated by drawing guide lines on the patient's face. The contralateral eye was used as a guide. This pattern was then processed with heat cure tooth colored (DPI tooth molding powder, D shade) acrylic resin. The scleral blank was then finished, polished and tried in the patient's ocular defect (Fig. 3). In the finished blank it was ensured that the eye contour and lid configurations resembled the natural eye of the patient, and the eyelids closed completely over it.

A digital photograph of the patient's natural eye was made while the patient was looking straight ahead. This image was then edited using Adobe Photoshop and a color print was obtained on a photo paper. The paper was cut



**Fig. 3:** Scleral blank



**Fig. 4:** Iris printed on photo paper

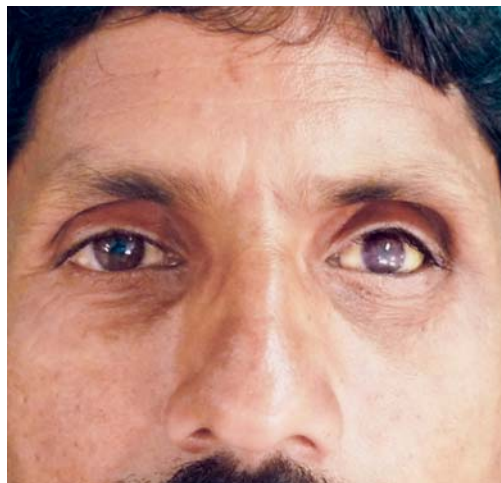along the shape of the iris and coated with cyanoacrylate to make it water resistant (Fig. 4).

Ocular buttons (Fig. 5) are usually used to attach onto this paper iris disk.<sup>1,2,4</sup> However, in order to obtain the convex shape of the cornea, self-cure clear acrylic resin was molded over the iris paper. After finishing and polishing, the custom-made ocular button was attached to the scleral blank at the previously determined position (Fig. 6).

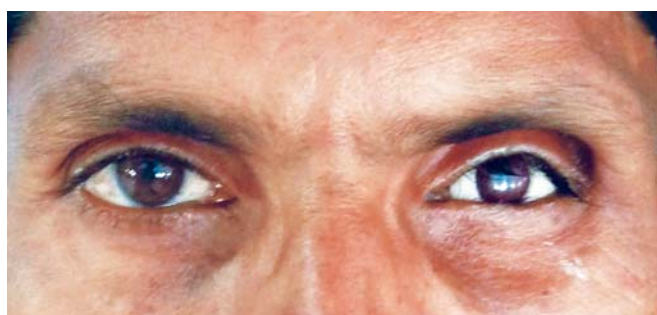The scleral blank was then prepared for the final layer of clear acrylic resin on the surface by removing about 1mm of acrylic from its surface. Characterization of the scleral region was done by attaching red colored silk threads using monomer polymer syrup (clear acrylic). A small amount of yellow colored stain was added to the syrup to obtain the yellowish tinge of the patient's natural eye. This prosthesis was then processed after packing a thin layer of heat cure clear acrylic on the surface of the characterization. The prosthesis was finished and polished (Fig. 7) with meticulous care to avoid any sharp areas and was inserted (Fig. 8).



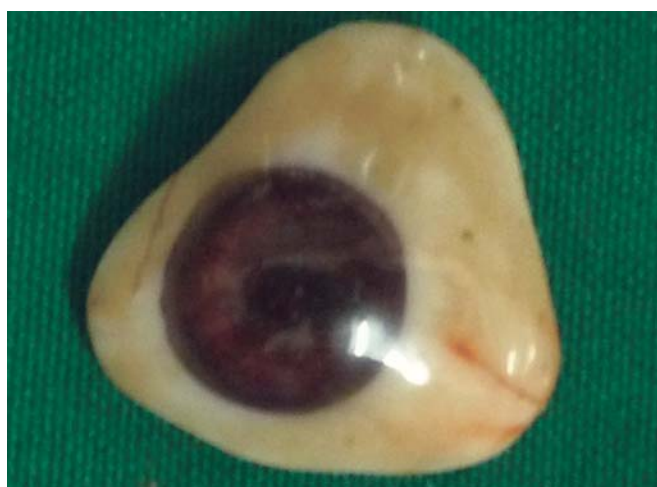**Fig. 5:** Ocular button



**Fig. 8:** Finished ocular prosthesis in place



**Fig. 6:** Positioning of iris portion of eye



**Fig. 7:** Characterization of the sclera

Post-insertion instructions included regular removal and cleaning of the prosthesis with an ophthalmic irrigation solution.<sup>4</sup>

## DISCUSSION

Numerous ocular impression and fitting techniques have been described in the literature. Most can be placed into one of several broad categories direct impression/external

impression, impression with a stock ocular tray or modified stock ocular tray, impression with custom ocular tray, impression using a stock ocular prosthesis, ocular prosthesis modification, and the wax scleral blank technique.<sup>5</sup> We had customized the tray prepared from the preliminary impression to accept the automixing syringe of light body elastomeric impression material.

For the fabrication of a wax scleral pattern it has been suggested to make a stone mold and break it after pouring the wax.<sup>3,6-9</sup> It is however a time consuming and cumbersome procedure. We simplified the process of obtaining the wax pattern by using irreversible hydrocolloid to form the mold. It also helped save a lot of time and material. In the conventional methods for replicating the iris proposed previously, the paper iris disk technique and the black iris disk technique, the iris is painted on the ocular disk using oil paints.<sup>2,6</sup> Dos Reis et al<sup>10</sup> had evaluated the color stability of painted iris colors on ocular prosthesis and concluded that the colors degraded as a function of time. Artopoulou et al<sup>1</sup> suggested the use of digital photography to replicate the iris of the patient. Though, there are no studies on the photodegradation of the digitally replicated iris. It is hoped that it will be more color stable than the traditionally painted colors. This procedure not only saves time but also helps obtain a very good replica of the natural iris with only a few modifications.

## SUMMARY

Ocular prostheses have a long history of successful use, and variations of the techniques and materials used have been introduced throughout the years. In the technique described, digital photography is used to replicate the iris of the patient, replacing the conventional oil paint technique, which simplified the process of fabrication of a custom ocular prosthesis. Advantages, such as reduced treatment

time and increased simplicity make this method an alternative for fabricating ocular prostheses.

## REFERENCES

1. Artopoulou I, et al. Digital imaging in the fabrication of ocular prostheses. *J Prosthet Dent* 2006;95:327-30.
2. Chalian VA, Drane JB, Standish MS. Maxillofacial prosthetics, multidisciplinary practice. Baltimore: The Williams & Wilkins Co 1971:286-93.
3. Bartlett SO, Dorsey JM. Ocular prosthesis: A physiologic system. *J Prosthet Dent* 1973;29(4):450-59.
4. Parr GR, Goldman BM, Rahn AO. Post insertion care of the ocular prosthesis. *J Prosthet Dent* 1983;49(1):220-24.
5. Ponnanna AA, Porwal A, Verma N. Impressions techniques for ocular prosthesis: A clinical review. *Int J Dent Clin* 2009;1(1):27-31.
6. Taylor TD. Clinical maxillofacial prosthetics. Chicago: Quintessence Pub Co 2000:265-77.
7. Brown KE. Fabrication of an ocular prosthesis. *J Prosthet Dent* 1970;24 (2):225-35.
8. Kaira LS, Mandal NB, Bharathi S. Prosthodontic rehabilitation of patient with ocular defect using an alternative technique. *J Orofac Sci* 2012;4(1):60-63.
9. Kalavathi SD, Arvind M, Phaneendra K. Restoring ocular esthetics using ocular prosthesis. *J Dent Sci Res* 2010;1(2):39-44.
10. Reis R, Dias R, Carvalho JC. Evaluation of iris color stability in ocular prosthesis. *Brazil Dent J* 2008;19(4):370-74.

## ABOUT THE AUTHORS

### Sandeep Chiramana (Corresponding Author)

Professor, Department of Prosthodontics, Sibar Institute of Dental Sciences Guntur, Andhra Pradesh, India, e-mail: chiramanasandeep@gmail.com

### Gopinadh Anne

Professor and Head, Department of Prosthodontics, Sibar Institute of Dental Sciences, Guntur, Andhra Pradesh, India

### Kavya Ravuri

Postgraduate Student, Department of Prosthodontics, Sibar Institute of Dental Sciences, Guntur, Andhra Pradesh, India

### Phani Praneetha Boppana

Postgraduate Student, Department of Prosthodontics, Sibar Institute of Dental Sciences, Guntur, Andhra Pradesh, India

### Sampath Kumar

Postgraduate Student, Department of Prosthodontics, Sibar Institute of Dental Sciences, Guntur, Andhra Pradesh, India

### Krishna Chaitanya Appana

Postgraduate Student, Department of Prosthodontics, Sibar Institute of Dental Sciences, Guntur, Andhra Pradesh, India