

Minimal Intervention in Pediatric Dentistry

Sachin Gunda, Narendra Varma

ABSTRACT

Dental caries is an infectious disease, identifying the risk factors and controlling them is important in preventing tooth demineralization. Early recognition of risk factors allows dentist to implement preventive regimes. Prevention includes rebalancing the oral environment to its natural state and preventing oral diseases progression. Once cavitation occurs restoring with minimal intervention technique shall minimize tooth loss and restore function.

Keywords: Minimal intervention, Demineralization - Remineralization, Glass ionomer cements, Atraumatic restorative treatment, Preventive dentistry.

How to cite this article: Gunda S, Varma N. Minimal Intervention in Pediatric Dentistry. J Orofac Res 2013;3(1):28-33.

Source of support: Nil

Conflict of interest: None declared

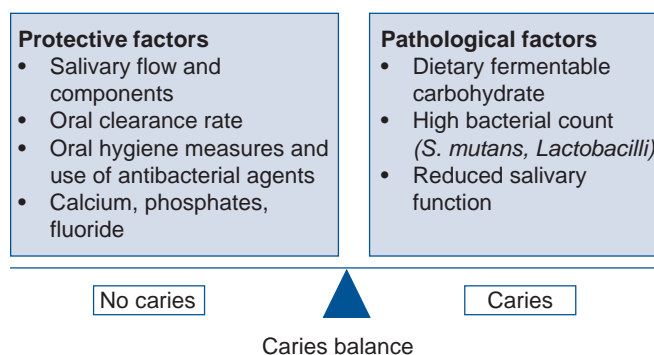
INTRODUCTION

Historically, when oral health problems became visible as frank cavitations, bleeding gums and loose teeth, the clinical outcome of the above was loss of tooth. Then GV Black came up with the concept of ‘extension for prevention,’ based on classification of caries,¹ whereby carious lesions were treated by surgical approach with removal of diseased portion of tooth and extending into areas which were not carious resulting in weakening the tooth structure. There has been a paradigm shift as dentists gained better knowledge of carious process and periodontal diseases. Caries has been identified to be infectious diseases of bacterial origin hence identifying the risk factors and controlling them are the key factors. Today restoration of cavity is not only the treatment of choice but early recognition of the risk factors will allows dentist to implement proper preventive regime before oral diseases/ caries become apparent. In the management of dental caries, it is also important to consider that dental caries is an infectious disease. ‘Drilling and filling’ a tooth is not the only solution to the damage caused by the caries process and is not an effective method to treat the cariogenic infection. A comprehensive preventive and treatment program is necessary to manage dental caries.² Minimal intervention is modern approach for management of caries, its principal are very simple: Identify, prevent, restore.³ Thus, minimally invasive dentistry (microdentistry) is ‘respecting the health, function and esthetics of oral tissue by preventing disease from occurring or intercepting its progress with minimal tissue loss’.⁴

To practice minimal intervention technique a proper knowledge of caries process is necessary. With minimally invasive dentistry, dental caries is treated as an infectious condition rather than an end product of it.

Caries Process⁵

Today it has been scientifically proved that caries is a multifactor disease wherein tooth, oral flora (*Streptococcus mutans*), dietary fermentable carbohydrate along with saliva play important role in caries progress. It is also been proved that enamel and dentine demineralization is not a continuous, irreversible process but a cycle of demineralization–remineralization, wherein tooth structure alternately loses and gains calcium and phosphate ions depending on the pH of oral cavity. Whenever pH drops below 5.5 the subsurface enamel and dentine begin to demineralize (loss of calcium and phosphate ions); as pH rises above 5.5 remineralization may occur (gain of calcium and phosphate ions). If the loss of calcium and phosphate continues from the crystals, large microporous areas develop. These areas are identified visually as ‘white spots’ when the tooth is dried, or are seen visually without drying when large microporous areas develop in enamel. If the loss of tooth structure continues, a cavity develops. Caries progression or reversal is determined by the balance between protective and pathological factors.



Identify (Risk Assessment)³

The first step of minimally invasive dentistry requires the assessment of a patient’s caries risk. Identify caries risk at early stage by:

- General health and diet of patient
- Oral hygiene status/Plaque accumulation
- Evaluation of caries activity
 - Level of cariogenic bacteria in oral environment (saliva and plaque).

Identify: Identify caries risk at early stage by checking oral hygiene status, plaque accumulation, pH of saliva, bacterial count in saliva, buffering capacity of saliva.

Prevent: Prevent demineralization and promote remineralization to heal the early lesions by proper oral hygiene methods, use of antibacterial rinses, fluoride rinses.

Restore: Repair the cavitations by minimal invasive technique and maintain maximum amount of healthy tooth structure. Restore for proper esthetics and function.

- Evaluation of saliva
 - Quality and quantity of saliva
 - pH of saliva
 - Buffering capacity of saliva
- Early caries diagnosis.

Accurate diagnosis of occlusal and proximal caries is difficult. The established diagnostic methods are visual and radiographic examination. New diagnostic technologies are now emerging to meet the challenge of diagnosing occlusal and proximal decay. Such new techniques include measurements of the scattering of light, fiber optic transillumination, electrical conductance measurements and quantitative laser- or light-induced fluorescence. These new technologies quantify changes in the physical characteristics of enamel related to demineralization.⁶

Prevention²

Prevention in minimal intervention is modifying risk factors using various strategies, i.e. reducing cariogenic bacteria and promoting remineralization of early carious lesions. This is achieved by:

1. Rebalancing the oral environment
2. Approach to remineralization
3. Surface protection
 - Changing the microflora, using agents such as topical chlorhexidine and topical fluoride
 - Reducing the amount of dietary sucrose
 - Decreasing the intake of fermentable carbohydrates
 - Adding fluoride, particularly through daily application during tooth brushing
 - Increasing salivary flow, using mechanical stimulation during vigorous chewing to enhance flow, by changing drugs which reduce flow, or by using drugs to enhance flow
 - Fissure protection by use of sealants.

Cure is achieved when diagnostic tests show that the disease is no longer active and the risk is low.

Rebalancing the Oral Environment

For example, patients with high *S. mutans* counts can use a chlorhexidine mouthwash twice a day, limit their intake of

fermentable carbohydrates, ensure an optimum salivary flow, use buffering agents to control oral pH, and practice good oral hygiene to prevent plaque accumulation. The goal is now to change the local biochemistry so that the patient is no longer losing tooth mineral and further cavitation does not occur.³

Approach to Remineralization⁷

Fluoride is widely known molecule that enhance remineralization. It is used in various forms, topical application of gel/foam, mouthwash, varnish, in toothpastes. Fluoride combines with hydroxyapatite to form fluorapatite layer that is resistant to dissolution in acid produced by microorganisms.

Non-Fluoride Remineralizing Agents⁸

CPP-ACP complex (casein phosphopeptides–amorphous calcium phosphate) is naturally occurring molecules that is able to bind calcium and phosphate ions. In case of low pH (acidic condition) CPP is able to release calcium and phosphate ions. The delivery of CPP-ACP complexes into plaque can be achieved through range of vehicles like chewing gums, dentifrices and topical gels. CPP binds to dental plaque, and during episodes of acid challenge were there is diffusion of calcium ions out of enamel, the CPP-ACP complex serves as a source of calcium for subsequent remineralization.

Studies have shown that CPP-ACP + fluoride are able to reduce caries more significantly than CPP-ACP or fluoride alone.

Calcium Sodium Phosphosilicate⁸

NovaMin[®] (calcium sodium phosphosilicate) is the trademark product of NovaMin Technology Inc. (NTI), which was acquired by GlaxoSmithKline in 2009. The compound is a bioactive glass composed of minerals that naturally occur in the body and reacts when it comes into contact with water, saliva or other body fluids. This reaction releases calcium, phosphorus, sodium and silicon ions in a way that results in the formation of new hydroxycarbonate apatite (HCA) crystals. NovaMin forms a mineralized layer that is mechanically strong and more resistant to acid.

Xylitol containing chewing gums increase salivary flow rate and enhance protective properties of saliva by increasing the buffering activity. The concentration of bicarbonate and phosphates ions in stimulated saliva is high which help in preventing demineralization.

Surface Protection⁹

Newly erupted teeth are at risk of developing caries as outer enamel surface has not undergone post-eruptive maturation.

Hence, enamel crystals are more prone to acid challenges. Surface protection by means of fissure sealants helps in reducing caries in these immature teeth. Fissure sealants act as a mechanical barrier for plaque accumulation in a deep pit and fissures, preventing tooth demineralization.

Restore²

In MIT concept, restoration is last resort and carried out when:

1. Tooth surface becomes cavitated and restoration is required for esthetics and function.
2. Repair of defective restoration, i.e. replacement of restoration.

GV Black's concept of cavity designs were carried out with respect to amalgam the only material of choice in 20th century. According to Black's concept it was necessary to:

- Remove excess tooth structure to gain access and visibility
- Place retentive grooves
- Extend cavity into self-cleansing areas to avoid recurrent caries
- Prepare a cavity so that material can be placed in sufficient bulk to provide strength.

Above factors caused structurally weak tooth with non adhesive restorative material, leading to high incidence of tooth fracture. More importance in Black's concept was given to restorative material than tooth structure. No restorative material can be regarded as completely effective in preventing secondary caries but today development of materials that can stimulate remineralization and adhesive materials that can prevent micro leakage and further secondary caries are available.

Principals of Minimally Invasive Restoration¹⁰

1. Shape of cavity is dictated by the caries and unique for each carious lesion (conservative cavity preparation).
2. Only demineralized enamel and infected dentine is removed, affected dentine can be left.
3. Macromechanical retention not required.
4. Undermined enamel cavity can be restored with adhesive materials.

The two wonder materials available today are glass ionomer cements and composites, help in restoring tooth strength, and reduce microleakage hence less chances of secondary caries.

Glass Ionomer Cements¹¹

Referred as 'Dentine Substitute' benefits are:

- Chemically bonded to tooth structure, hence less chances of secondary caries

- Antimicrobial
- Fluoride releasing property hence helps in remineralization.

Due to above properties it is it can also be used as a restorative material, liner and base under resin-based composite restorations and luting agent.

New Classification¹²

Site/size	No. cavity	Minimal	Moderate	Enlarge	Extensive
	0	1	2	3	4
Pit/fissure (1)	1.0	1.1	1.2	1.3	1.4
Contact area (2)	2.0	2.1	2.2	2.3	2.4
Cervical (3)	3.0	3.1	3.2	3.3	3.4

Carious lesions occur in only three different sites on the surface of the crown of a tooth (Table 1).

Site 1: The pits and fissures on the occlusal surface of posterior teeth and similar defects on otherwise smooth enamel surfaces.

Site 2: The contact areas between any pair of teeth, anterior or posteriors.

Site 3: The cervical areas related to the gingival tissues including exposed root surfaces.

Lesion Size

A neglected lesion will continue to extend as an area of demineralization in relation to one of the sites noted above. As it extends so the complexities of restoration will increase. The sizes that can be readily identified are as follows:

Size 0: The initial lesion at any site that can be identified but has not yet resulted in surface cavitation—it may be possible to heal it.

Size 1: The smallest minimal lesion requiring operative intervention. The cavity is just beyond healing through remineralization.

Size 2: A moderate sized cavity. There is still sufficient sound tooth structure to maintain the integrity of the remaining crown and accept the occlusal load.

Size 3: The cavity needs to be modified and enlarged to provide some protection for the remaining crown from the occlusal load. There is already a split at the base of a cusp or, if not protected, a split is likely to develop.

Size 4: The cavity is now extensive following loss of a cusp from a posterior tooth or an incisal edge from an anterior.

Cavity Design

The cavity designed in minimal intervention technique is simply to eliminate surface cavitation and to ensure that the restorative material will properly seal the margins against

any potential microleakage.¹² Armamentarium used in MIT should be such that only demineralized and infected tooth structure removed, hence sharp spoon excavator and small round diamond bur be used. The conservation of healthy tooth structure is the most important benefit a dentist can offer to their patients and represents a step forward in dentistry. The key is early detection and treatment of hidden caries, 'Watch and Wait' policy is no longer acceptable theory for the treatment of hidden carious lesions.³ Untreated caries, although they may be very small in stature, can be extremely and very rapidly destructive. The earliest detection and treatment of carious lesions promotes complete and sound dental health.¹⁰

Occlusal Approach²

Preventive resin restoration is an extension technique of sealant application. It is indicated when there is a localized pit caries extending into dentine with otherwise sound deep pit and fissures.

Pit caries cavity is prepared by conservative removal of demineralized enamel and dentin, and restoring with resin-based composite, unaffected deep pit and fissures are then sealed 'sealed for prevention'. Adhesive restorative materials are retained with help of dentin bonding agents (micromechanical retention); hence macromechanical retention with dovetails and undercuts is not required.

Atraumatic restorative technique (ART) is a procedure based on excavating carious cavities in teeth using hand instruments only and restoring them with an adhesive filling material (glass ionomer). This procedure was originally developed because millions of people in less industrialized countries and special groups like refugees and people living in deprived communities are unable to obtain dental care. Their teeth generally decay until removal is required. These people have not benefited from the developments that have brought about improved oral health in the industrialized world. The absence of electricity and the traditional idea that restorative dental care requires electrically driven equipment are the main reasons underlying this situation. In contrast the ART approach enables treatment of cavities in teeth of people residing in areas where electricity is not available, or where the community cannot afford expensive dental equipment.¹³

The ART technique provides the oral health worker with a tool that supports the concept 'Teeth for Life'. Removing carious tooth tissue with hand instruments alone and restoring the cavity with glass ionomer will conserve as much tooth structure as possible and prevent further decay.

Air abrasion technique in which abrasive particles like aluminum oxide are released at high velocity with help of

compressed air. These abrasive particles on are striking over tooth structure at high velocity, remove small amount tooth structure. Efficiency of hard tissue removal depends on number factors like particle size, gas pressure, diameter of nozzle, distance of nozzle from surface. More helpful in cases of pit and fissure caries limited to enamel, were use of burs shall remove more amount of sound enamel. Air abrasion shall remove minimal carious enamel which can then be sealed.¹⁴

With changing time not only better materials are available but burs for ultraconservative preparation have been developed.

The Fissurotomy® Bur

1. It can be used to progressively explore suspect fissure systems or portions of fissure systems.
2. The bur can be used to create one pass cutting to the DEJ, when its depth is accurately judged by knowing the bur head length (2.5 mm) and gauging depth by relating the bur head/neck junction to the cavosurface cavity preparation margin.
3. The bur can be used to remove very small amounts of carious dentin. When larger amounts of carious dentin are encountered, appropriate round burs (#2 to #6) or hand excavators should be used.
4. The bur can be used to gain access to larger dentin carious lesions by efficiently removing overlying enamel. When positioned in the developing cavity preparation at full depth, the portion of the bur head closer to the head/neck interface will quickly and smoothly remove enamel as the bur is directed laterally. The greater head diameter in this region as well as the design of the bur blades provides efficient, yet controlled cutting.
5. Finally, the bur can be used for enameloplasty procedures to remove irregular surface and fissure-related defects, and to prepare an area for restoration or sealing.¹⁵

The goals of ultraconservative preparation are quite simple:

1. Recontouring the fissure and pit anatomy for access and visibility.
2. Exploration of the cavity to ensure that no decay remains undetected.
3. Ultraconservative (but complete) caries removal.

Proximal lesion in posterior teeth poses problems due to access and possible undermining of marginal ridge as occlusal load has to be taken in account. It is suggested that there are at least three primary variations in dealing with a proximal lesion.

Tunnel

A conservative tunnel restoration situated 2 mm from the marginal ridge, does not significantly weaken an otherwise intact tooth.¹⁶ In this situation the lesion is more than 2.5 mm from the crest of the marginal ridge. It is possible that the remaining proximal enamel is sufficiently strong that it can be retained and a tunnel cavity designed, the approach to lesion is from occlusal surface obliquely. Retention of the marginal ridge is desirable to maintain the intrinsic strength of the crown.

Slot

In this case the lesion is closer to the crest of the marginal ridge than 2.5 mm.¹⁷ So if a tunnel had been designed the marginal ridge will almost certainly fail. A slot design or 'minibox' is therefore the best choice.

Proximal approach—this is a rather unusual design because access is dependent upon the presence of a rather large size 3 lesion in the adjacent tooth. Though unusual, it is very conservative of tooth structure and will lead to preservation of the marginal ridge.¹⁶⁻¹⁸

Tunnel	Slot or box	Proximal
>2.5 mm below crest of marginal ridge	<2.5 mm below crest of marginal ridge	Through adjacent large cavity

FDI Policy for Minimal Intervention in the Management of Dental Caries

1. *Modification of oral flora*: Dental caries is an infectious diseases and primary focus therefore should be on control of bacterial count and plaque
2. *Patient education*: Motivate patient for proper oral hygiene measures and means of prevention through dietary methods
3. *Remineralization of noncavitated lesions*: Saliva plays an important role in demineralization/remineralization cycle, quality and quantity should therefore be assessed. There is evidence 'white-spot' lesions of enamel can be managed initially by remineralization technique.
4. *Minimal operative intervention of cavitated lesions*: Operative intervention should focus on preservation of natural tooth structure and limited to removal of friable enamel and infected dentine. These cavities should then be restored with adhesive material like glass-ionomer cement and/or composite.
5. *Repair of defective restorations*: Defective/fractured restorations may lead to secondary caries or gingival problems.

SUMMARY

Minimally invasive dentistry integrates prevention, remineralization and minimal intervention for the placement and replacement of restorations. The essential aspects of this approach emphasis on risk assessment, early diagnosis of carious lesions effectively diagnose much smaller lesions

in the teeth, prevention and remineralization of noncavitated enamel and dentin. The initial lesion at any site that can be identified but has not yet resulted in surface cavitation – it may be possible to heal it.

Such, healing processes were not available to GV Black because fluoride and adhesion were not understood. The ultimate aim now must be preservation of remaining tooth structure which, of course, will lead to maintenance of physical properties as well as esthetics. Fortunately, the current era of dentistry has witnessed the development of new materials, new techniques, and new instruments that make conservative dentistry practical and ultraconservative dentistry a reality. Adhesive restorations eliminate the need for more extensive retentive preparations. Minimally invasive dentistry has changed the philosophy of restorative dentistry. A conservative approach is favored, one that will help patients maintain their dentition for their lifetimes.

We must also move:

'From Era of Extension for Prevention to Prevention of Extension'.

REFERENCES

1. Black GV. A work on operative dentistry: The technical procedures in filling teeth. Chicago: Medico-Dental Publishing House 1917:111-19.
2. Tyas MJ, Anusavice KJ, Frencken JE. Minimal intervention dentistry: A review. *Int Dent J* 2000;50:1-12.
3. Donly KJ, Brown DJ. Identify, protect, restore: Emerging issues in approaching children's oral health. *Gen Dent* 2005 Mar-Apr;53(2):105-10.
4. World Congress of Minimally Invasive Dentistry. www.mcmid.com
5. Featherstone JD. The caries balance: Contributing factors and early detection. *J Calif Dent Assoc* 2003;31:129-33.
6. Milicich G. Clinical application of new advances in occlusal caries diagnosis. *NZ Dent J* 2000;96:21-26.
7. Walsh LJ. Contemporary technologies for remineralization therapies: A review. *Int Dent SA* 2009;11(6):6-16.
8. Reynolds EC. Calcium phosphate based remineralization systems: Scientific evidence. *Aust Dental J* 2008;53(3):268-73.
9. Feigal RJ. The use of pit and fissure sealants. *Pediatr Dent* 2002;24:415-22.
10. Satehle HJ. Minimal invasive restorative treatment. *J Adhesive Dent* 1999;1:267-84.
11. Croll TP, Nicholson JW. Glass ionomer cements in pediatric dentistry: Review of the literature. *Pediatr Dent* 2002;24:423-29.
12. Mount GJ, Hume WR. Classification and cavity preparation for carious lesions in preservation and restoration of tooth structure (2nd ed). Sandgate (Qld): Knowledge Books and Software 2005:243.
13. Frencken JE, Pilot T, Songpaisan Y, et al. Atraumatic restorative technique (ART): Rationale, technique and development. *J Public Health Dent* 1995;56:135-40.

14. Milicich G. The use of air abrasion and glass ionomer cements in micro dentistry. *Compendium* 2001;21(11A):1036-38.
15. Boston DW. A novel approach for treating fissure caries. *Dent News* 2000;7:27-31.
16. Strand GV, Tveit AB, Gjerdet NR, Eide GE. Marginal ridge strength of teeth with tunnel preparations. *Int Dent J* 1995 Apr;45(2):117-23.
17. Mount GJ, Hume WR. Basic principles for cavity design. In: Mount GJ, Hume WR (Eds). *Preservation and restoration of tooth structure*. Sandgate (Qld): Knowledge Books and Software 2005:145-62.
18. Chalmers JM. MID: Strategies for addressing restorative challenges in older patients. *J Canad Dent Assoc* 2006;72(5): 435-40.

ABOUT THE AUTHORS

Sachin Gunda

Professor, Department of Pediatric and Preventive Dentistry, Bharti Vidhyapeeth Dental College and Hospital, Sangli, Maharashtra, India

Correspondence Address: Savali H Ghatge Colony, Kadamwadi Road, Kolhapur, Maharashtra, India, Phone: 09850276069, e-mail: sachingunda@rediffmail.com

Narendra Varma

Assistant Professor, Department of Pediatric and Preventive Dentistry IBN Sina Institute of Medical Sciences, Jeddah, Saudi Arabia