

CASE REPORT

Double Lateral Sliding Bridge Flap for the Treatment of Multiple Gingival Recessions: Case Series

SVVS Musalaiah, V Satya Krishna, P Aravind Kumar, M Nagasree

ABSTRACT

Esthetic concerns of patient have become an essential part of dentistry, especially periodontics. Root coverage is being achieved by a variety of surgical techniques. The presence of shallow vestibule, inadequate width of attached gingiva and aberrant frenum pull may pose a challenge to cover the denuded root surface for which several independent surgical solutions are reported in the literature. This article highlights on two case reports in which a double lateral sliding bridge flap technique has been used for root coverage as a single step solution for the above mentioned mucogingival problems, if present simultaneously in any case.

Keywords: Gingival recession, Root coverage, Bridge flap.

How to cite this article: Musalaiah SVVS, Krishna VS, Kumar PA, Nagasree M. Double Lateral Sliding Bridge Flap for the Treatment of Multiple Gingival Recessions: Case Series. *J Orofac Res* 2012;2(4):247-250.

Source of support: Nil

Conflict of interest: None declared

INTRODUCTION

Gingival recession is the exposure of the root surface by an apical shift in the position of the gingiva. There are two types of gingival recession, one due to periodontitis and the other primarily related to mechanical factors, especially toothbrushing.¹ Recession due to periodontitis can affect all the tooth surfaces and is irreversible. In contrast, facial recession due to mechanical factors is often reversible, or partially reversible, with periodontal reconstructive procedures. In general, complete coverage of facial recession defects can be achieved when there is no loss of interproximal bone or soft tissue.² Other factors that can predispose to gingival recession include tooth malposition, bone dehiscence, thin marginal soft tissue, high frenum attachment, inflammation, inflammatory viral eruption and dental restorative, orthodontic or periodontal treatments.³ Marginal tissue recession results in dentinal hypersensitivity, esthetic problems and tendency for root caries. Therefore, root coverage procedures have become an important part of periodontal regenerative therapy.

There are several procedures for the treatment of gingival recessions. The double lateral sliding bridge flap technique was proposed by Margraff.⁴ This technique utilizes the combination of a coronally advanced flap and modified Edlan and Mejchar technique.⁵ The primary concept of this technique is that a connected soft tissue flap is slid over the

area of recession after releasing muscular tension at the vestibular end. Essentially the original attached gingiva is used for the coverage and the vestibular alveolar mucosa is pushed in place of the attached gingiva. The denuded alveolar mucosa heals by secondary intention.

This technique is indicated in multiple gingival recessions. Advantages of the technique are that it does not require: (1) A second surgical site, as in free soft tissue grafting procedures, (2) separate frenectomy procedure. This procedure is contraindicated in conditions where recession is circumferential with horizontal bone loss.

Two patients came to the Outpatient Department of Periodontics, St Joseph Dental College with a chief complaint of poor esthetics and hypersensitivity and were selected for the procedure after phase one therapy. Prior to therapy and after surgery the parameters recorded were dimensions of gingival recession (i.e. width and depth of gingival recession), probing pocket depth (PPD), clinical attachment level (CAL) and width of the keratinized gingiva using Williams periodontal probe.

CASE REPORTS

Case 1

A 26-year-old male patient revealed the following on intraoral examination: Deep narrow gingival recession (Sullivan and Atkins 1968) was present on 31, 32, 41, 42. The width of recession 2 mm and depth of recession was 3 mm and width of keratinized gingiva was 3 mm. A PPD of 2 mm and CAL 5 mm was present (Figs 1 to 6).

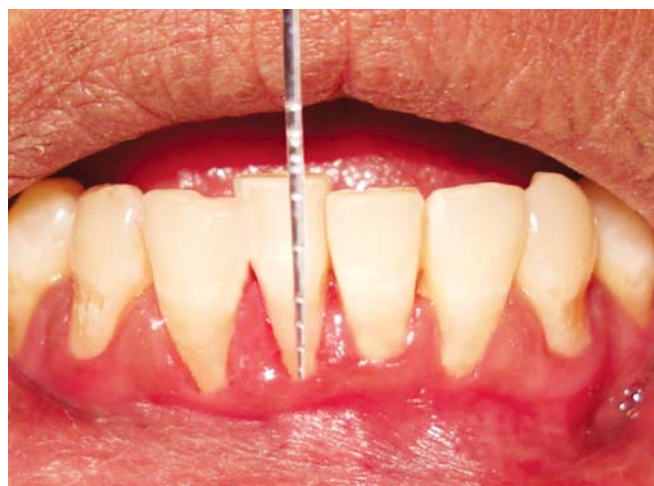

Fig. 1: Preoperative view

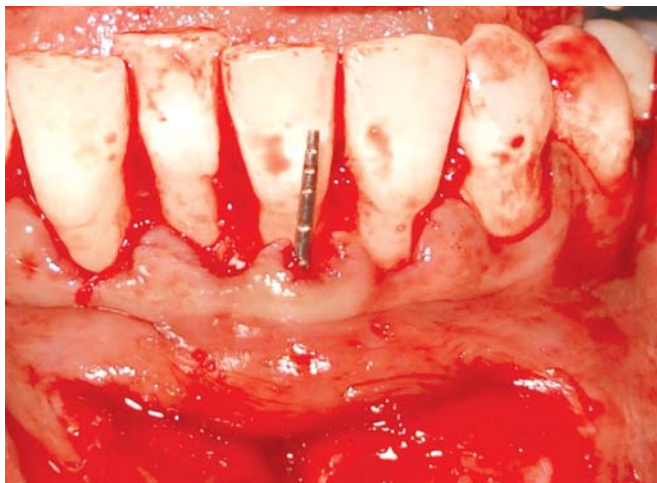


Fig. 2: Bridge flap elevated and coronally positioned

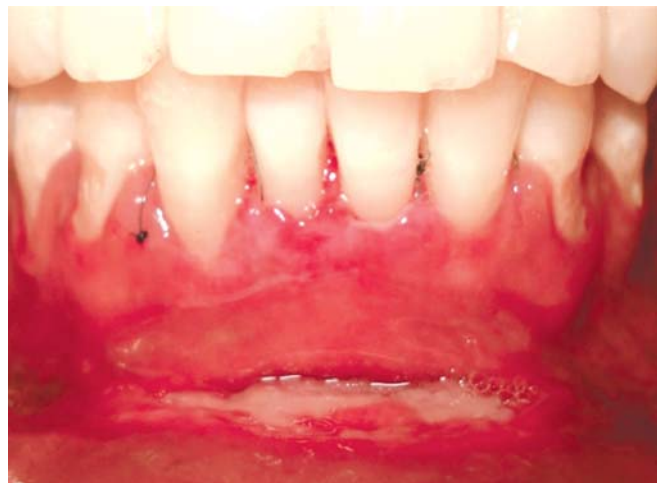

Fig. 5: Ten days postoperative photograph

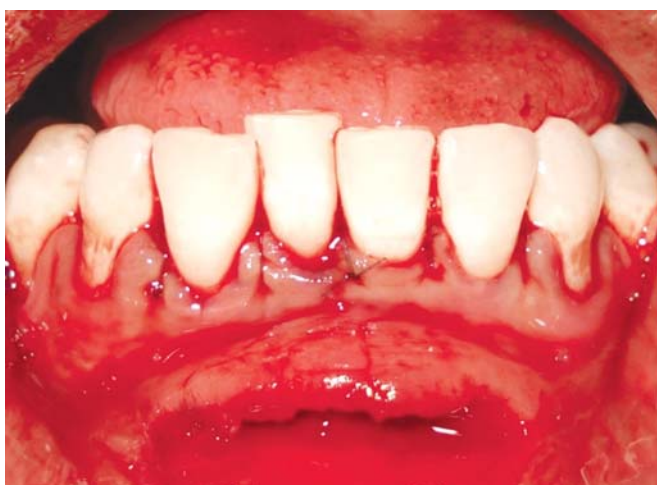

Fig. 3: Coronally positioned and sutured

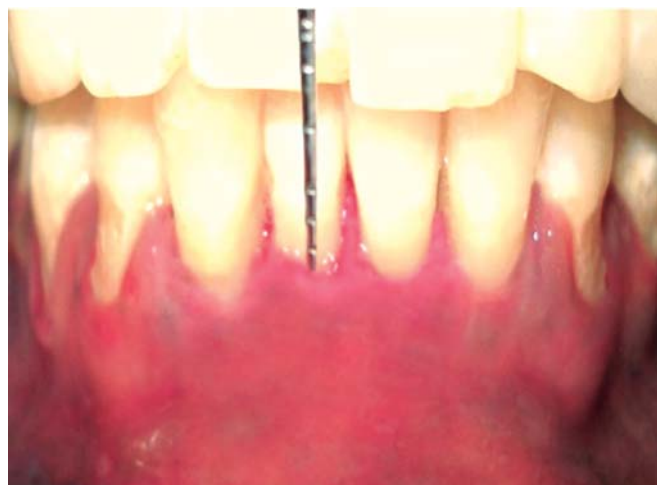

Fig. 6: Three months postoperative photograph

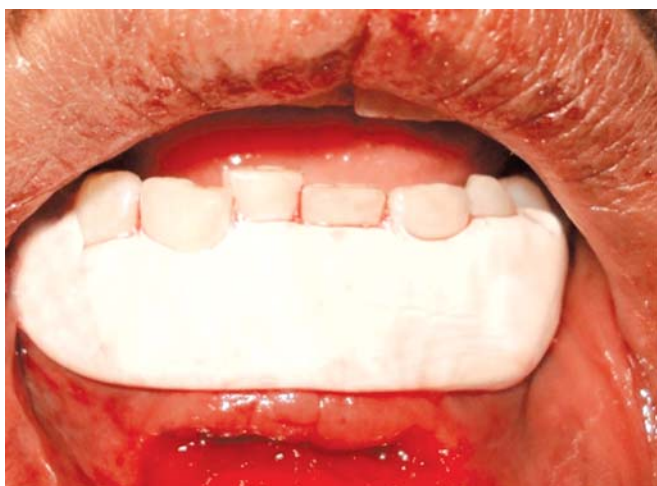

Fig. 4: Periodontal pack placed

keratinized gingiva was 2 mm. A PPD of 2 mm and CAL 4 mm was present (Figs 7 to 10).

SURGICAL TECHNIQUE

In the surgical procedure, first a semilunar-arch shaped incision is given at the lower aspect of the vestibule such that the ends must be turned toward the vestibule.⁶ This is necessary in order to produce a sufficiently wide bridging flap, ensuring sufficient blood supply. A split thickness flap is elevated in coronoapical direction after a sulcular incision is given. The whole bridge flap is coronally positioned and pressed toward the alveolar bone for at least 3 minutes to avoid hematoma formation. Coronally positioned bridge flap is sutured and periodontal pack is placed.

After surgery the patients were instructed to avoid brushing at the surgical area for 2 weeks and to rinse with 0.12% chlorhexidine solution three times daily for 6 to 8 weeks. Amoxicillin (500 mg daily) three times was prescribed for 5 days after the surgery to prevent postoperative infection. Patients were recalled once a week for review for the first month and then for every month.

Case 2

A 24-year-old male patient revealed the following on intraoral examination: Shallow wide gingival recession (Sullivan and Atkins 1968) was present on 31, 32, 41, 42. The width and depth of recession was 2 mm and width of

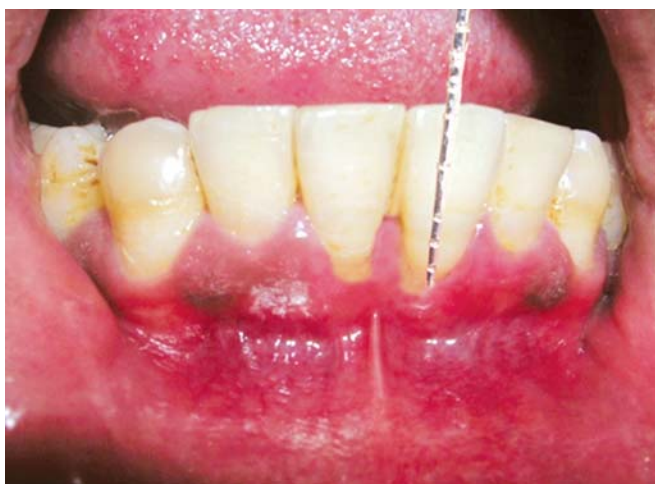

Fig. 7: Preoperative view

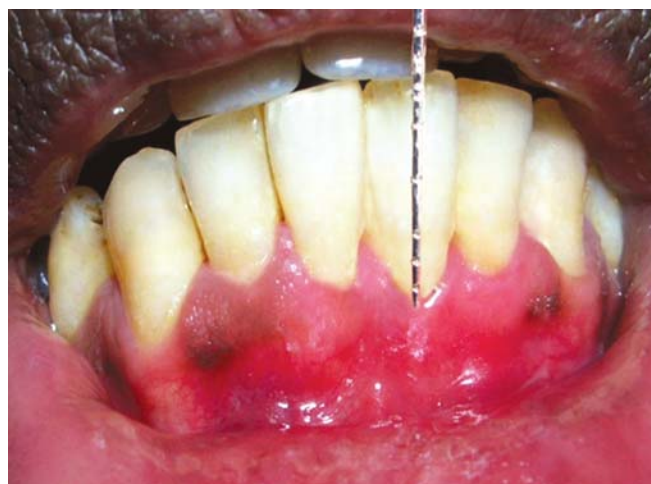

Fig. 10: Three months postoperative photograph

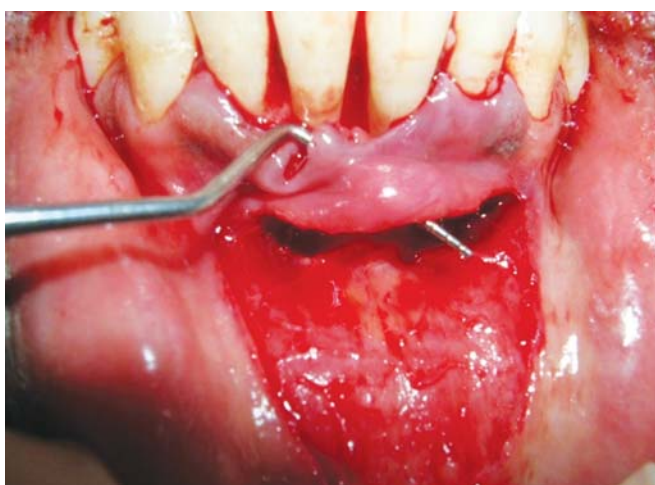


Fig. 8: Bridge flap elevated and coronally positioned

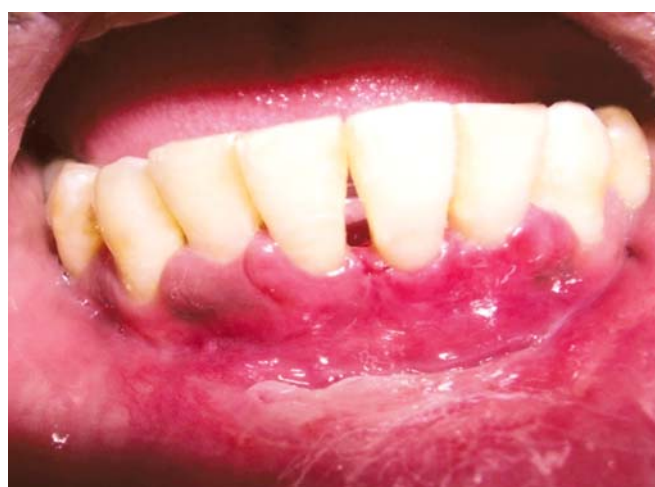

Fig. 9: Ten days postoperative photograph

RESULTS

Recall examination after a postoperative period of 3 months revealed complete root coverage. In case 1, the width of attached gingiva increased from 3 to 5 mm, gain in CAL is 3 mm and a PPD of 2 mm was present. In case 2, the width

of attached gingiva increased from 2 to 4 mm, gain in CAL of 2 mm and a PPD of 2 mm was present. Patients were instructed to use soft bristles toothbrush for mechanical plaque control by coronally directed roll technique.

DISCUSSION

A wide variety of periodontal plastic surgical procedures have been described to correct mucogingival problems and to cover denuded root surfaces. There existed still an unresolved controversy in the literature regarding adequate width of attached gingiva and periodontal health maintenance⁷ and the contemporary opinion suggested that regions with less than 2 mm attached gingiva and thin gingival tissue are at increased risk for gingival recession even if it is possible to maintain the gingival health in the areas with insufficient or absent attached gingiva.⁸

In both the cases, there existed an uncomplicated healing and complete root coverage was achieved as defined by Miller.⁹ There was no change in PPD from the preoperative value clinically as the cases selected were already scaled and thoroughly root planed. This result was in accordance to the study conducted by Gupta et al.¹² The gain in CAL from the preoperative value was 3 mm (case 1), 2 mm (case 2) which also reasserted the gain in width of attached gingiva and was similar to the studies by Romanos et al⁶ and Gupta et al.¹² The incidence for recurrence of recession is reduced as in (a) case-1: By deepening the vestibule, as the mucosal flap cannot be influenced by tension from an apical direction which was in accordance with the study by Wennstorm¹⁰ which showed that narrow band of attached gingiva did not interfere with gingivectomy or flap surgery results (b) in case-2: As the frenal pull was relieved by releasing the periosteal fibers and this was in accordance with study done by Romanos et al,⁶ Vijayalakshmi et al¹¹ and Vivek Gupta et al¹² and therefore no necessity for separate frenectomy procedure which is the advantage of this technique.

The quality of the flap can be improved by placement of a free gingival graft or a submerged connective tissue graft, or a submerged connective tissue graft which may increase the probability of a stable result.⁶

CONCLUSION

Surgical treatment of gingival recession defects aims at obtaining soft tissue coverage of exposed root surfaces and/or augmentation of gingival tissue dimensions. A variety of protocols have been developed to manage these clinical problems. This procedure is a very useful surgical procedure to eliminate the problem of gingival recession and hypersensitivity even in the presence of shallow vestibule, high frenal pull in single step with careful performance of the operation. However, future studies with larger sample size should be employed for the results to be generalized.

REFERENCES

1. Loe H, Anerud A, Boysen H. The natural history of periodontal disease in man: Prevalence, severity, and extent of gingival recession. *J Periodontol* 1992;63:489-95.
2. Miller PD Jr. A classification of marginal tissue recession. *Int J Periodontics Restorative Dent* 1985;5(2):8-13.
3. Baker D, Seymour G. The possible pathogenesis of gingival recession. *J Clin Periodontol* 1976;3:208-19.
4. Marggraf E. A direct technique with a double lateral bridging for the coverage of denuded root surface and gingival extension. Clinical evaluation after 2 years. *J Clin Periodontol* 1985; 12:69-76.
5. Edlan A, Mejchar B. Plastic surgery of the vestibule in periodontal therapy. *Int Dent J* 1965;13:593-97.
6. Romanos GE, Bernimoulin JP, Marggraf E. The double lateral bridging flap for coverage of denuded root surface. Longitudinal study and clinical evaluation after 5 to 8 years. *J Periodontol* 1993;64:683-88.
7. Remya V, Kumar KK, et al. Free gingival graft in the treatment of class III gingival recession. *Indian J Dent Res* 2008;19: 247-52.
8. Popova C, Kotosilkov K, et al. Mucogingival surgery with free gingival graft (strip technique) for augmentation of the attached gingival tissues. Report of three cases. *J IMAB Annl Proc (scientific papers)* 2007;2:25-30.
9. Miller PD. Root coverage with free gingival graft. Factors associated with incomplete root coverage. *J Periodontol* 1987;58:674-81.
10. Wennstorm JL. Regeneration of gingiva following surgical excision. A clinical study. *J Clin Periodontol* 1983;10:287-97.
11. Vijayalakshmi R, Sudhakar U, et al. Double lateral sliding bridge flap for the treatment of multiple gingival recessions: Two case reports. *Perio* 2008;5(1):29-33.
12. Gupta V, Bains VK, et al. Bridge flap technique as a single step solution to mucogingival problems: A case series. *Contemporary Clin Dent* 2011;2:110-14.

ABOUT THE AUTHORS

SVVS Musalaiah

Head, Department of Periodontics, St Joseph Dental College and Hospital, Eluru, Andhra Pradesh, India

V Satya Krishna (Corresponding Author)

Department of Periodontics, St Joseph Dental College and Hospital Duggirala, Eluru, Andhra Pradesh, India, Phone: 09848353002 e-mail: satyakrishna.bds25@gmail.com

P Aravind Kumar

Associate Professor, Department of Periodontics, St Joseph Dental College and Hospital, Eluru, Andhra Pradesh, India

M Nagasree

Professor, Department of Periodontics, St Joseph Dental College and Hospital, Eluru, Andhra Pradesh, India