

Orthodontic treatment of transposition of bilateral maxillary canine and 1st premolar by maintaining the transposed position: A case report

Monika Mahajan

From, Assistant Professor, Department of Orthodontics & Dentofacial Orthopedics, Himachal Pradesh Government Dental College and Hospital, Shimla, H.P. India.

Correspondence to: Dr. Monika Mahajan, Department of Orthodontics and Dentofacial Orthopedics, Himachal Pradesh Government Dental College and Hospital, Shimla, H.P. India. Email: monika.hemender@gmail.com

Received - 15 February 2019

Initial Review – 5 March 2019

Accepted – 20 March 2019

ABSTRACT

Bilateral tooth transposition between maxillary canine and 1st premolar is a rare finding and poses a challenge to any orthodontist to treat. In definitive treatment plan, one of the treatment alternatives can be finishing the case with alignment of involved teeth in their transposed position whereas the other option is to correct the transposition orthodontically and establishing the natural tooth order. Here a case is presented where transposed positions were maintained with the philosophy to treat by minimizing the negative factors.

Keywords:- *bilateral transposition , orthodontic treatment*

Tooth transposition is a developmental alteration resulting in a deviation in tooth position, clinically identified as the interchange of two adjacent teeth, that alters the natural order of the dental arch [1-3]. Tooth transposition can be complete, when both the tooth crown and the root are transposed, or incomplete when only the clinical crown is transposed but the root apex remains in relatively normal position [4]. The 5 types of tooth transpositions observed in upper jaw are classified by Peck and Peck according to the teeth involved as: (1) Canine to 1st premolar; (2) Canine to Lateral Incisor; (3) Canine to 1st Molar position; (4) Lateral Incisor to Central Incisor; (5) Canine to Central Incisor position [2]. Transpositions mostly involve the upper arch and unilateral transposition is more common than bilateral transpositions with the left side being more often involved [3-5].

The canine is one of the most commonly involved teeth in the transposition phenomenon, changing its eruptive place with the lateral incisor or the 1st premolar in most cases [5-7]. Canine transposition has a maxillary

predilection and is generally associated with other anomalies such as agenesis (40%), deciduous canine retention (50%) and peg shaped maxillary lateral incisor (25%) [1,6,8]. Unilateral canine transposition happens more frequently (79%) and the left side is more frequently affected (69%) [1,9]. Bilateral transposition has been reported in 5% of cases [2]. Transposition between canine and maxillary 1st premolar occurs in 0.135% to 0.510% of the population [4,10]. In Japan, the incidence ranges from 0.065% in general population to 0.660% in orthodontic patients [10,11]. Elsewhere occurrence ranges from 0.380% in a Turkish population to 0.510% in Africa [10,12].

Tooth transposition can hinder esthetic and functional aspects of dentition. Postulated causes of tooth transposition include inversion of the tooth buds during development, alteration of the tooth eruption pattern, the presence of deciduous teeth beyond the maximum time limit for the development of the permanent teeth and any dental trauma during childhood. A genetic origin also has

been reported as the main etiologic factor thus supporting a theory of multifactorial heredity in transposition of teeth. Maxillary canine and 1st premolar transposition is currently considered a tooth position anomaly caused by genetic factors along with a multifactorial inheritance pattern. According to Peck and Peck various observations corroborate the polygenic inheritance theory such as the high prevalence of dental anomalies related to maxillary canine -1st premolar transposition, its bilateral occurrence, familial occurrence with significant differences in prevalence among males and females [3-5,13-18]. We hereby present a case to demonstrate complete bilateral transposition of maxillary canine to 1st premolar along with the treatment option selected.

CASE REPORT

The patient, a girl aged 13 years, reported to the Department of Orthodontics, with the chief complaint of mild crowding along with tooth malposition in upper arch. An extraoral examination showed a pleasing face with facial symmetry and a straight profile (Fig 1). An intraoral examination revealed that she had all her permanent teeth erupted except maxillary left canine which had not erupted. There were bilateral retained deciduous maxillary canines present.

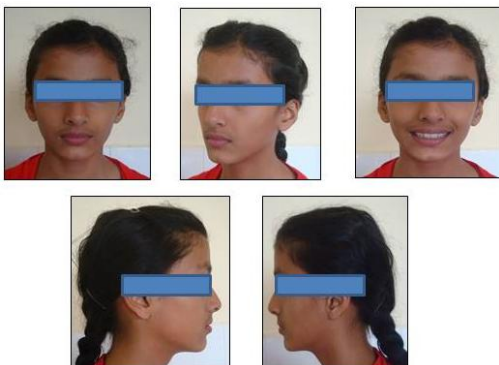

Figure 1: Pre-treatment extra-oral photographs

The clinical examination revealed Angle's molar relationship as class I on the left side and end on the right side. There was a complete transposition of maxillary canine and 1st premolar on the right side clinically. The maxillary right 1st premolar was rotated mesiopalatally and maxillary canine was placed buccally distal to 1st premolar. The left maxillary canine was unerupted (Fig 2). The panoramic radiograph showed that all permanent teeth

including the 3rd molars were present with complete bilateral transposition of maxillary canines and 1st premolars (Fig 3).

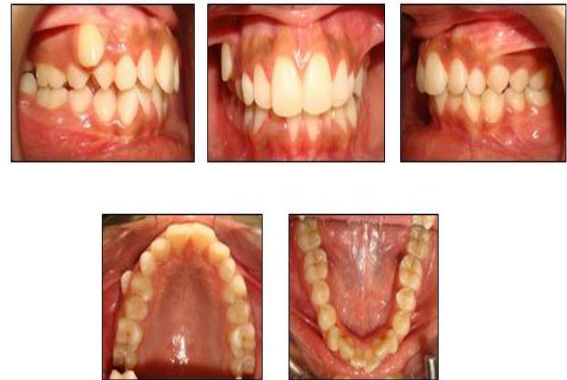

Figure 2: Pre-treatment intra-oral photographs

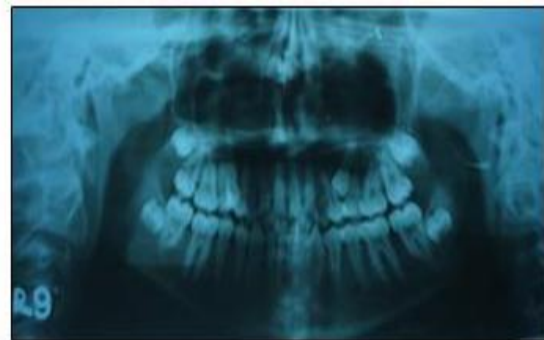

Figure 3: OPG showing complete bilateral maxillary transposition between canine & 1st premolar

Treatment objectives were based on multidisciplinary approach to improve esthetics, establish oral health and function as well as to attain stability forms. The patient was referred for the required orthodontic treatment with the aim of achieving treatment objectives mentioned below:

- To relieve the crowding of upper and lower anterior teeth.
- To establish a functional class I molar and canine relationship.
- To correct the transposition and establishing the natural tooth order if possible.

Orthodontic treatment was initiated by bonding upper lower arches with pre torqued and pre angulated brackets with a 0.022 inch slot of MBT prescription. Tooth

movement was started with light forces. Both retained deciduous canines were extracted. The 1st premolars were moved mesially and the canines were moved distally to 1st premolar position bilaterally. Fixed appliances were removed after 28 months of orthodontic treatment and removable Hawleys retainers were placed in both mandible and maxilla to maintain orthodontic correction. The patient was suggested to get bilateral odontoplasty of the tip of the cusp of canines to mimic the anatomy of premolar but she did not feel the need and hence declined but was advised to undergo it in near future.

The post-treatment results showed the patient with a very pleasant face and smile (Fig 4). Intraorally the patient attained correction of crowding of teeth with maintaining Angles class I molar relationship with an ideal overjet and overbite (Fig 5).

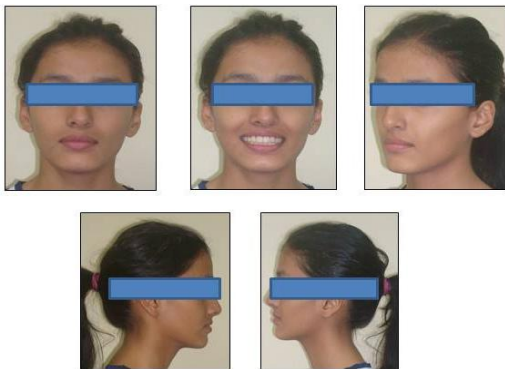


Figure 4: Post-treatment extra-oral photographs

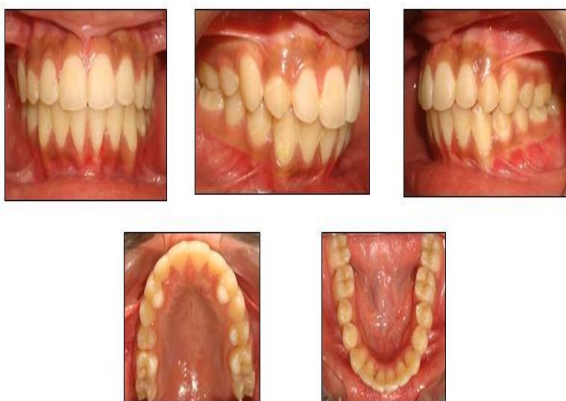

Figure 5: Post-treatment intraoral photographs

The challenge of correcting a transposition is to accomplish it while maintaining periodontal health. The

post treatment lateral cephalogram shows maintenance of skeletal class I bases (Fig 6). The panoramic radiographic view demonstrated normal alveolar contours and no sign of root resorption or any other damage to canine or premolar was seen (Fig 7).

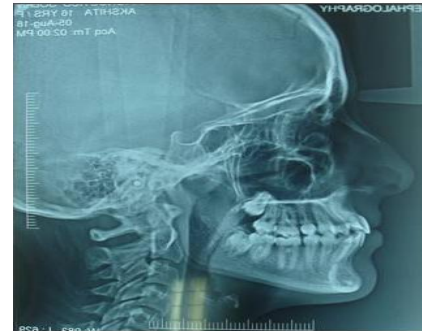

Figure 6: Post-treatment lateral cephalogram showing class I skeletal bases

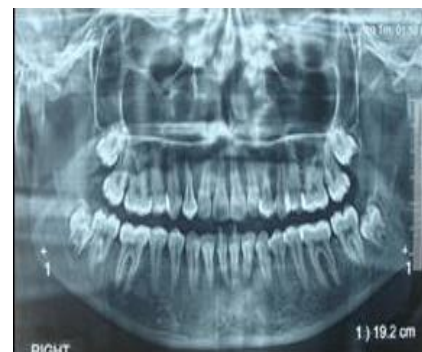

Figure 7: Post-treatment OPG shows finishing in transposed position

DISCUSSION

The maxillary canine to 1st premolar transposition is clearly the most frequently reported maxillary transposition type [5,7]. The treatment of transposition can be classified as interceptive or definitive depending on when the transposition is diagnosed. Interceptive treatment is performed on patients at the age of 6 and 8 years after OPG and intra oral examination reveals presence of tooth transposition at the initial stage. Interceptive treatment can be adapted before transposition is complete, which normally occurs around 10 years of age. Hence thereafter a definitive treatment approach should be adapted [3,19]. In definitive treatment, one of the treatment alternatives can be finishing the case, with alignment of involved teeth in their transposed position. The other option is to correct the

transposition orthodontically and establishing the natural tooth order. Extraction approach is preferred when a severe arch deficiency persists. It is not advised to correct transposed teeth in permanent dentition because of potential risk of damaging the teeth or supporting structures. Therefore alignment of the involved teeth in their transposed position seems to be the best alternative with the positioning of teeth in the new sequence [6,15].

In our case, a non-extraction approach was considered. Thereafter keeping the transposed order of the teeth or recreating the natural tooth order was presented as two treatment alternatives to the patient. If it is opted to keep the natural tooth order, treatment becomes longer and more difficult. However, if it is opted to keep the transposed tooth order, different variables such as different root prominence, different height of gingival scallops as well as the shape and size of the transposed premolar has to be considered [20]. Esthetic and occlusal considerations suggest that aligning the transposed teeth while keeping their transposed positions would be unacceptable but, as a general rule it is not advisable to correct a transposed tooth order due to insufficient buccopalatal width of bone support for the movement of two adjacent teeth in different directions, especially after eruption [17]. Many reports showed recession at the gingival margins of the repositioned canines because of long journey of canines through the dense buccal compact bone [17,20].

We treated this case with the philosophy to minimize the negative factors. The key to success is to diagnose the case early and begin the treatment, thereby minimizing the possibilities of injuring the surrounding tissues [2,9,13]. One must take into consideration the esthetic factors, occlusion, canine root apex position, periodontal support, patients age along with treatment duration, patient cooperation when correcting the transposed teeth.

CONCLUSION

Transposition is an anomaly of tooth position which is a challenge for an orthodontist. When correcting it different factors should be taken into consideration such as age of patient, esthetics, occlusion, treatment time, patient comfort and periodontal support. The treatment allowed us to place the teeth in their transposed order. Our patient was satisfied with the esthetic results obtained and has good oral health.

REFERENCES

1. Chatopadhyay A. Transposition of teeth and genetic etiology. *Angle Orthod.* 1998;66:147-152.
2. Peck S, Peck L. Classification of maxillary transpositions. *Am J Orthod Dentofacial Orthop.* 1995;107:505-507.
3. Peck S, Peck L, Kataja M. Mandibular lateral incisor-canine transposition, concomitant dental anomalies, and genetic control. *Angle Orthod.* 1997;68:455-466.
4. Shapira Y, Kuftinec MM. Maxillary tooth transpositions: Characteristic features and accompanying dental anomalies. *Am J Orthod Dentofacial Orthop.* 2001;119:127-134.
5. Joshi MR, Bhatt NA. Canine transposition. *Oral Surg Oral Med Oral Pathol.* 1971;31:49-54.
6. Shapira Y, Kuftinec MM. Tooth transpositions- a review of the literature and treatment considerations. *Angle Orthod.* 1989;59:271-276.
7. Joshi MR, Gaitonde SS. Canine transposition of extensive degree: a case report. *Br Dent J.* 1966;121:221-222.
8. Newman GV. Transposition: orthodontic treatment. *J Am Dent Assoc.* 1977;94:554-557.
9. Shapira Y, Kuftinec MM. Maxillary canine – lateral transposition-orthodontic management. *Am J Orthod Dentofacial Orthop.* 1989;95:439-444.
10. Tseng YC, Chang HP, Chou TM. Canine Transposition. *Kaohsiung J Med Sci.* 2005;21:441-7
11. Sato K, Yokozeki M, Takagi T, Moriyama K. An orthodontic case of transposition of the upper right canine and first premolar. *Angle Orthod.* 2002;72:275-8.
12. Burnett SE. Prevalence of maxillary canine- first premolar transposition in a composite African sample. *Angle Orthod.* 1999;69:187-9.
13. Parker WS. Transposed premolars, canines, and lateral incisors. *Am J Orthod Dentofacial Orthop.* 1990;97:431-48.
14. Gholston LR, Williams PR. Bilateral transposition of maxillary canines and lateral incisors: a rare condition. *J Dent Child.* 1984;51:58-63.
15. Laptok T, Silling G. Canine transposition- approaches to treatment. *J Am Dent Assoc.* 1983;107:746-748.
16. Dayal PK, Shodhan KH, Dave CJ. Transposition of canine with traumatic etiology. *J Indian Dent Assoc.* 1983;55:283-5.
17. Peck L, Peck S, Attia Y. Maxillary canine- first premolar transposition, associated dental anomalies and genetic basis. *Angle Orthod.* 1993;63:99-109.

18. Lai HH, Chang HF. Analysis of tooth transposition. J Taiwan Assoc Orthod.2004;16:38-43.
19. Plunkett DJ, Dysart PS, Kardos TB, Herbison GP. A study of transposed canines in a sample of orthodontic patients. Br J Orthod.1998;25:203-8.
20. Kuroda S, Kuroda Y. Non extraction treatment of upper canine –premolar transposition in an adult patient. Angle Orthod. 2005;75:472-477.

How to cite this article: Mahajan M. Orthodontic treatment of transposition of bilateral maxillary canine and 1st premolar by maintaining the transposed position: A case report. J Orofac Res. 2019;8(1):8-12.

Funding: None; Conflict of Interest: None Stated.