

Personalized Denture...Let's make a difference!! -A clinical case report on characterized denture.

Dr. Brijesh Shetty*, Dr. Pranav V Mody**, Dr. Manish Kumar***, Dr. Girish Kumar***,
Dr. Kalpesh K. Revankar Bhat***

Abstract:

Despite the fact that solutions to functional and comfort problems are often available, successfully restoring the appearance of an edentulous patient remains a challenge. Esthetics pertains to the sense of the beautiful or the science which deduces from nature and taste the rules and principles of art. Esthetics has always exerted a profound influence in history. Because it has always been a prime concern of individuals, having the effect of exciting emotions of approval or disapproval. This case report differentiates a method of restoring esthetics for a 54 year-old male patient with completely edentulous maxillary and mandibular arches. Patient was treated with removable maxillary and mandibular conventional complete denture and characterized removable maxillary and mandibular complete denture. The results were significant with use of characterized denture compared to conventional denture were improvements in facial esthetics and more rapid social integration of this patient.

Key Words: Characterization, prosthesis, conventional denture prosthesis, teeth arrangement, balanced articulation, denture esthetics.

Introduction:

The glossary of prosthodontic term defines esthetics is the branch of philosophy dealing with beauty, especially with the components thereof, viz., color and form; and the qualities involved in the appearance of a given restoration. Treatment challenges for completely edentulous patient have traditionally been described as a combination of esthetics, function and comfort. Some studies regarding predictors of complete denture success failed to show esthetics as more important than function or comfort ¹. In contrast to these studies, Carlsson et al found that esthetics was the factor most responsible for complete denture success ². Vig agreed with the importance of esthetics in denture success, stating that, 'Good appearance is so related psychologically to comfort that the 2 cannot be separated ³. A survey by Vallittu et al found that patients wearing removable dentures considered the appearance to be the most important property of the teeth ⁴. Conventional dentures are normally set up in a

uniform manner and gum work can be smooth and featureless, that's why denture wearers get artificial, sometimes ugly appearance. Restoring smile in edentulous patients may be considered as an achievement because smile is an integral part of the face and, more generally of the whole person; it expresses beauty, age, personality and youth⁵. The principal aim was to restore missing teeth to establish normal vertical dimension and provide support for the facial soft tissues, thereby providing the patient with optimal esthetics and function which would raise patient's self confidence and quality of life. Denture characterization is modification of the form and color of the denture base and teeth to produce a more lifelike appearance. Realism – tooth arrangement, gum imitation: especially with features such as muscle attachments, stippling, root details and, coloring of the denture base was used to provide the patient with a 'true-to life' prosthesis.

Case report:

A 54 year old male patient presented to department of Prosthodontics, KVG Dental College Sullia (D.K), India for prosthetic rehabilitation with a chief complaint of difficulty in chewing and unpleasant smile (Fig-1). Intraoral examination revealed patient were completely edentulous in maxillary and mandibular arches. The objectives of treatment regarding the dental condition were the preservation of bone, development of normal mechanisms of chewing, speaking and swallowing; the establishment of normal

* M.D.S., Reader, Dept of Prosthodontics, K.V.G. Dental College and Hospital, Sullia, Karnataka, ** M.D.S., Professor and Head, Dept of Prosthodontics, K.V.G. Dental College and Hospital, Sullia, Karnataka, ***, Post graduate student, Dept of Prosthodontics, K.V.G. Dental College and Hospital, Sullia, Karnataka

Correspondence address:

Dr. Manish Kumar,
Post graduate student, Dept. of Prosthodontics including crown & bridge, and Implantology,
K.V.G. Dental College and Hospital,
Sullia, Karnataka State, India. 574327
Mobile: 09742985680
E-mail: cooldrmanish@gmail.com

facial characteristics and smile; and development of normal emotional and psychologic profile; and the fitting of a functional prosthesis with adequate retention, stability, and support. To fulfill these criteria a set of complete denture with characterization as the treatment option was discussed with patient. In characterized denture, denture esthetics has to be matched with the facial feature of the patient and the dentogenic concept. The treatment plan was designed to fabricate conventional and characterized maxillary and mandibular complete denture with bilaterally balanced articulation. Both the dentures were fabricated in a usual manner till jaw relation record stage. Primary Impressions were made using irreversible hydrocolloid impression material (Zelgan 2002; Dentsply DeTrey GmbH, Konstanz, Germany). Border molding was done using low fusing compound (DPI pinnacle tracing sticks, Dental Products of India) and final impressions were made in Zinc oxide Eugenol impression paste (DPI impression paste, Dental Products of India). Master casts were obtained in type 3 dental stone (Kalabhai, Mumbai, India). Casts were mounted on semi adjustable articulators (Hanau Wide Vue, No 183,) using a facebow (Hanau Spring Bow, Teledyne Water Pik, Fort Collins, Colorado, USA) and centric bite record (Ramitec, ESPE, Germany). The articulator was programmed using protrusive bite record made up of polyether (Ramitec, ESPE, Germany). In conventional denture teeth arrangement and processing was done in usual manner. (Fig-2)



Fig 1-Preoperative view of the patient

In order to improve facial characteristics and smile of patient the dentures were characterized.

- 1) Characterization of denture base- to mimic the natural gingiva, acrylic colours were added while packing. Three colour shades were

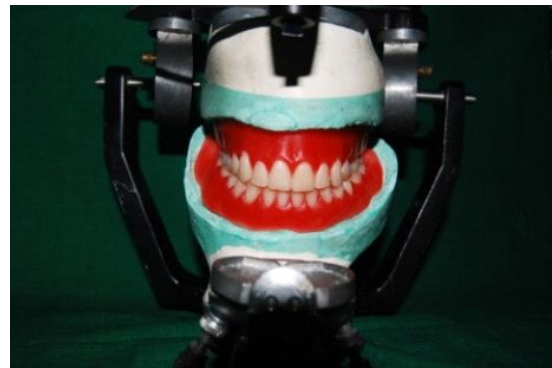

Fig 2-Teeth arrangement for conventional denture on semi adjustable articulator.

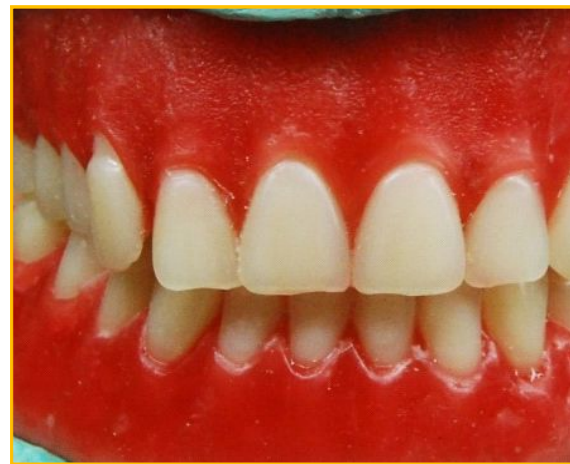


Fig 3-Denture characteristics as stippling, root carving, spacing, overlapping and attrition was given.

obtained for marginal gingiva, attached gingiva and denture base by adding acrylic colour in heat cure acrylic monomer. packing were done in three step, first light pink colour acrylic only around the neck of teeth, then dark color to mimic attached gingiva, followed by normal pink for base. Flask was closed and denture was processed in normal manner.

- 2) Characterization in teeth arrangement- The anterior teeth were arranged with slight overlapping, mild chipping and little bit of irregularities although maintaining the balanced articulation and phonetics (Fig-3).

The dentures were inserted with minor adjustments and the occlusion was checked intraorally (Fig-4a & 4b). Written oral hygiene instructions were given and explained to the patient. Patient was highly satisfied with the characterized denture appearance compared with conventional denture (Fig-5). Patient was recalled after 24 hours and 1 week for post insertion care. The patient was then asked to follow a 3-month regular recall schedule.

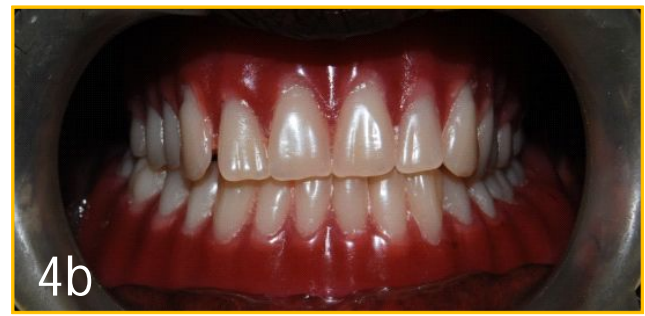
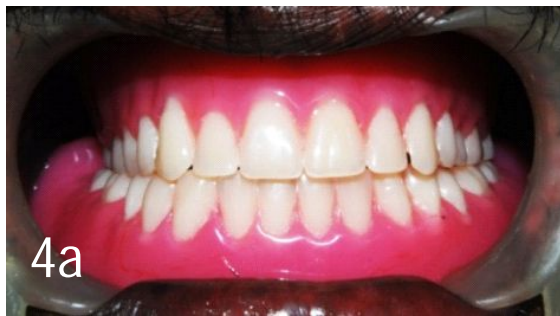
Fig-4a and 4b comparison between conventional and characterized denture.



Fig-5 functionally, esthetically and psychologically satisfied patient with characterized denture.

Discussion:

The prosthodontic management of completely edentulous patient with characterized denture prosthesis requires a broad base of knowledge to produce a more lifelike appearance compared with conventional denture that produces artificial look. This case report described method for fabrication of conventional and characterized complete denture prosthesis for a completely edentulous male patient. Frush and Fischer wrote that gender, personality, and age could be used as guidelines for tooth selection, arrangement, and characterization to enhance the natural appearance of the individual⁶. The primary guideline is to attempt dynamic unity, also called unity with variety. The entire dental composition should be complimentary to the face and to itself. At the same time, it should not be mechanically straight or without uniqueness. Proportion, line, dominance, balance, and color are some of the specifically applied principles⁷. The article is important because of its scientific approach to the artistic nature of denture construction.

The main objectives of complete denture prostheses in edentulous patient are to improve the esthetics, phonetics, and masticatory function. A characterized denture was the treatment of choice for

this patient, because the objectives were to restore function, and esthetics, moreover patient insisted to his natural appearance. The involvement of the patient in treatment decisions is clearly a major determinant of treatment success for complete dentures⁸. The literature on the psychological response of patients to complete denture therapy confirms that losing the teeth often creates an acute awareness of dental appearance. Characterization of denture base is done by incorporating rugosa areas, gingival sulcus, interdental papillae etc., & by incorporating the colors & shades of the natural oral tissues. Esthetics has become a respectable term in dentistry. In the past, the importance of esthetics was discounted in favor of terms such as function, structure, and biology. However, if a treatment plan does not begin with a clear view of its esthetic impact on the patient, then the outcome could be disastrous. In today's dental world, treatment planning must begin with well-defined esthetic objectives. By beginning with esthetics, and taking into consideration the impact on function, structure, and biology, the clinician can use the various skills in dentistry to deliver the highest level of dental care to each patient⁹. The dynesthetic and dentogenic concept along with unity with variety when applied provides a more natural, harmonious prosthesis, which not only is desired by patients, but also is a quality of care they deserve. Outstanding esthetics can be achieved by simple guidelines; using tooth molds specifically sculpted for males and females, arranging prosthetic teeth to correspond the sex, personality and age and sculpting the matrix (visible denture base) with more natural contours.

Conclusion:

The treatment with characterized complete denture prosthesis can produce a more lifelike or natural appearance compared with conventional

denture that produces artificial look in edentulous patients. Prosthodontic therapy with use of characterized complete denture prosthesis compare to conventional denture prosthesis aids the patient in developing proper speech, enhanced esthetics and may have dramatic social and psychological benefits for these patients.

References:

1. Yoshizumi DT. An evaluation of factors pertinent to the success of complete denture service. *J Prosthet Dent* 1964; 14:866-78.
2. Carlsson GE, Otterland A, Wennstrom A, Odont D. Patient factors in appreciation of complete dentures. *J Prosthet Dent* 1967; 17:322-8.
3. Vig RG. The denture look. *J Prosthet Dent* 1961:9-15.
4. Vallittu PK, Vallittu ASJ, Lassila VP. Dental aesthetics – a survey of attitudes in different groups of patients. *J Dent* 1996; 24:335-8.
5. Ruel-Kellermann M. What are the psychological factors involved in motivating individuals to retain their teeth? Dreams and facts. *Int Dent J* 1984;34:105-109.
6. Frush JP, Fisher RD. Introduction to dentogenic restorations. *J Prosthet Dent* 1955; 5:586-95.
7. Waliszewski M. Restoring dentate appearance: A literature review for modern complete denture esthetics *J Prosthet Dent* 2005; 93:386-94.
8. Hirsch B, Levin B, Tiber N. Effects of patient involvement and esthetic preference on denture acceptance. *J Prosthet Dent* 1972; 28:127-32.
9. Spear FM, Kokich VG. A Multidisciplinary Approach to Esthetic Dentistry. *Dent Clin North Am* 2007; 51:487–505.