

A rare case of presence of unusual foreign body in rectum in homosexual male

Vaibhav Vishal¹, Naresh Meena², Manish Mahendra³

From ¹Senior Resident, Department of Urology, Calicut Medical College, Kozhikode, Kerala, ²Assistant Professor, Department of General surgery, Bikaner Medical College, Bikaner, Rajasthan, ³Senior Resident, Department of Neuro surgery, Dr. Baba Sahib Ambedkar Hospital, New Delhi, India

Correspondence to: Vaibhav Vishal, S/O Dr. D K Shrivastava, Global Hospital, Mount Abu - 307 501, Rajasthan, India.
E-mail: drvvs123@gmail.com

Received – 09 April 2018

Initial Review – 29 April 2018

Published Online – 21 June 2018

ABSTRACT

Foreign body in the rectum is rare yet potentially life-threatening condition; fear of social embarrassment causes the patient to delay to seek treatment and even hide the actual history and replace imaging reports, which leads to incorrect diagnosis and eventually the treatment. In this article, we report the case of a 30 years hepatitis B positive, homosexual male who presented to the department with a chief complaint of pain in the lower abdomen and was diagnosed to have foreign body (pestle) in rectum, which was inserted as a part of sexual adventure and deliberate attempt was made by the patient to replace X-ray films with other patients to mislead the treating doctor. Finally, the foreign body was removed surgically and was followed by psychiatric evaluation of the patient.

Key words: *Foreign body, Rectum, Sexual misadventure, X-ray films*

The presence of foreign body in the rectum is rare yet potentially life-threatening condition and its incidence has been on the rise in the past decade. Studies predict that such incidence may continue to increase with the use of the varied object for sexual fantasy or criminal intent [1]. Around three-quarter of the cases of impacted foreign bodies presenting to the hospital are due to object used for sexual adventures [2]. Fear of social embracement may cause the patient to delay medical consultation and treatment causing diagnostic and management challenge [3]. Incidences of patient misguiding the treating doctor with fabricated history are not uncommon. The patient may even replace imaging films with films of other patients to hide the truth which leads to incorrect diagnosis and eventually delay in the treatment. Thus, in this case report, we highlight the importance of a high degree of suspicion and proper and detailed evaluation followed by tailored approach for the patient.

We present a case report of a retained foreign body in the rectum, inserted as a part of the sexual adventure, where patient made deliberate attempt to conceal the history and replaced his X-ray films to avoid the humiliation of correct diagnosis.

CASE REPORT

A 30-year-old male came to the department with a chief complaint of pain in the lower abdomen for past 2 weeks. The patient had occasional colicky abdominal pain, mainly confined to the left lower abdomen, with no aggravating or relieving factors or diurnal variation. The patient had no history prior medical consultation or medication. The patient did not have any other features such as vomiting, diarrhea, fever, or any bladder or bowel complaints.

On clinical examination, vital signs were within the normal range. On per abdomen examination, the abdomen was soft and non-distended. He had mild tenderness in the left iliac fossa with no features of peritonitis. Rest of the systemic examination was normal.

The patient was advised to undergo a routine blood test, ultrasonography (USG) abdomen, and X-ray chest on the erect abdomen. The patient was diagnosed with hepatitis B positive in blood serology while rest of the routine blood tests were within the normal limits.

During USG, there was mild probe tenderness in the left iliac fossa and X-ray abdomen was found to be normal, but later on, it was found that the patient had exchanged the X-ray with another patient to hide his disease and to avoid embarrassment.

As clinician was unable to reach the final diagnosis and due to suspicious behavior of the patient, clinician ordered for a contrast-enhanced computed tomography (CECT) abdomen and pelvis and to everyone surprise, CECT was suggestive of 20 cm long rod-shaped metallic foreign body in rectosigmoid junction with lower end around 15 cm above anal verge (Fig. 1).

On strict questioning, after the CT report, the patient admitted inserting a metallic rod 2 weeks back per rectally as part of “sexual experiment” which later he was unable to extract out.

To avoid the social humiliation, he was hiding these facts and even exchanged his X-ray abdomen film with another patient. Later on, he returned the original X-ray abdomen, which showed a 20 cm long metallic foreign body in the rectum (Fig. 2).

The patient was posted for sigmoidoscopy for evaluation and extraction of the rectal foreign body. Sigmoidoscopy revealed evidence of large metallic foreign body in rectum, but despite best

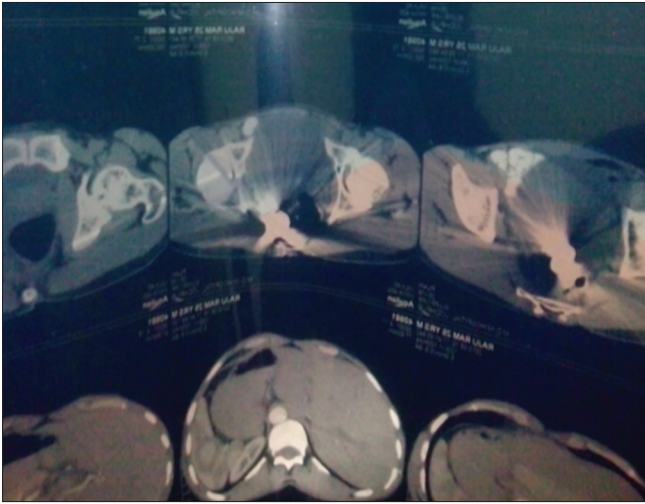


Figure 1: Metallic foreign body seen in contrast-enhanced computed tomography pelvis

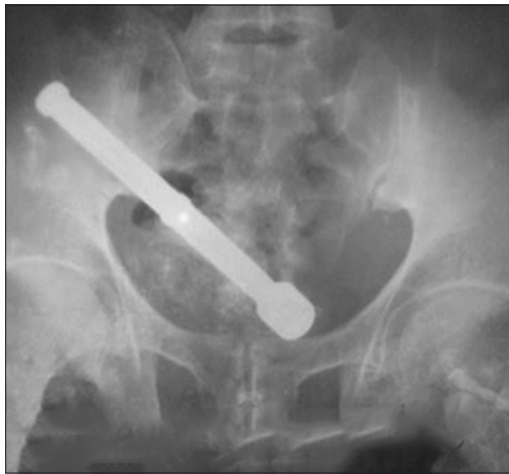

Figure 2: X-ray pelvis with metallic foreign body

efforts removal was not possible. After pre-operative intravenous antibiotics, the patient was brought to the operating room, where he was given general anesthesia and intubated, and placed in the supine position. Laparotomy was done and peritoneal cavity was reached. Hard metallic object could be palpated in rectum and sigmoid colon with no features of perforation. An enterotomy was made on anterolateral wall of sigmoid colon and a 20 cm metallic rod was removed (Figs. 3 and 4). Enterotomy was primarily closed in double layer after extraction of foreign body. Abdominal drain was placed and laparotomy was closed. Post-operative period was uneventful. Drain was removed on postoperatively day 2, and the patient was referred to psychiatrist after being discharged.

DISCUSSION

Cases of insertion of the foreign body either as a part of sexual misadventure or drug trafficking are on rise and many incidences of per rectal insertion of various materials ranging from fruits, batteries, sex toys, and deodorant bottle [4] have come to light from various parts of world [5,6]. If done as a part of the sexual adventure, most of the patient will have a history of serial insertion

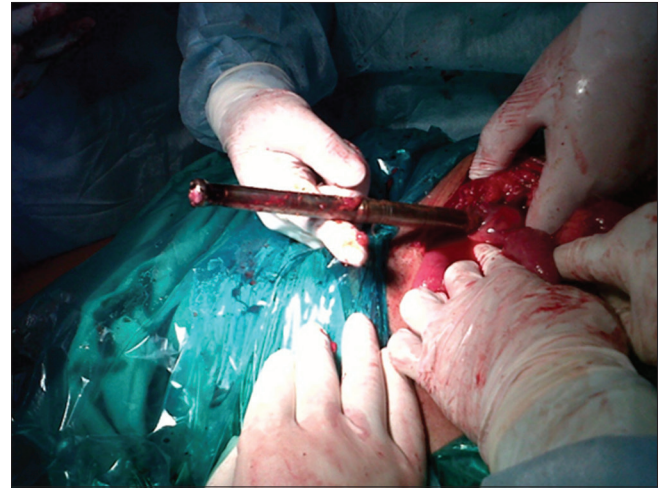


Figure 3: Operative removal of metallic pestle after enterotomy



Figure 4: Metallic pestle postoperatively

of the foreign body which will lead to the lax rectal sphincter. According to Danielson and Holmes [7], 8% of adolescent youths suffer from sexual abuse.

Medical treatment is generally sought by the patient if the inserted foreign material could not be successfully removed or if it caused discomfort, severe pain, and bleeding per rectum. According to previous literature, men have the higher incidence compared to women of insertion of the foreign body in the rectum. Rectum and sigmoid colon are the most common sites for the lower gastrointestinal tract foreign bodies [8].

Most of the patients will try to conceal the history of insertion of foreign body and will present with a history of anal pain, lower abdominal pain, and bleeding [9]. As a clinician, it is very important to have a high degree of suspicion when confronted with suspicious history and clinical finding. A thorough per abdomen examination and per rectal examination should be done to rule out peritonitis, evaluate the tone of rectal sphincter. X-rays of abdomen and pelvis are the initial investigation for diagnosis of the presence, number, shape, size, and location of the inserted material, if the inserted object is not metallic or not picked up in X-ray, CT scan must be done.

Care should be taken that X-ray and CT scan film are marked with the correct name and age of the patient. As in the above case,

the patient may try to exchange X-ray films with that of other patients for avoiding the embracement of clinical diagnosis of a foreign body in the rectum.

According to Eftaiha *et al.* classification [10], objects lying above the rectosigmoid junction are considered as high lying and are difficult to remove per-rectally even with the proctosigmoidoscope, as in the above-described case. Gentle attempt to remove the object should be made during sigmoidoscopy but the use of force or repeated attempt should be avoided as it might cause further injury. If transanal and endoscopic approaches fail to retrieve the foreign object or peritoneal signs are present, the patient needs to be taken for surgery.

Lake *et al.* suggested predictors for surgical intervention which respectively included foreign bodies which are larger than 10 cm, hard or sharp, or located in the proximal rectum or distal sigmoid [11].

During laparotomy for the removal of the object, a gentle attempt of milking out of the foreign body through natural anal opening can be tried as it would avoid enterotomy. The patient with perforation, peritonitis, or major injury of the rectum, a diverting colostomy should be made after removal of the foreign body [10]. The use of minimally invasive techniques for the removal of smooth foreign bodies has been described [12]. It avoids the need for laparotomy and decreases hospital stay for the patient. All patients should also undergo the psychological evaluation to avoid similar episodes in the future.

CONCLUSION

High index of suspicion with prompt diagnostic workup including marking of the X-ray films with proper name and age of patient should be mandatory in cases of suspicious history and clinical examination. The treatment protocol should be individualized depending on size, shape, presence or absence of peritonitis, or

rectal injury. Treatment option of manual extraction of foreign body, sigmoidoscopic removal, or laparotomy removal should be considered. Proper psychiatric evolution should be done after surgical treatment.

REFERENCES

1. Ayantunde AA, Unluer Z. Increasing trend in retained rectal foreign bodies. *World J Gastrointest Surg* 2016;8:679-84.
2. Cohen JS, Sackier JM. Management of colorectal foreign bodies. *J R Coll Surg Edinb* 1996;41:312-5.
3. Ayantunde AA. Approach to the diagnosis and management of retained rectal foreign bodies: Clinical update. *Tech Coloproctol* 2013;17:13.
4. Ozbilgin M, Arslan B, Yakut MC, Aksoy SO, Terzi MC. Five years with a rectal foreign body: A case report. *Int J Surg Case Rep* 2015;6:210-3.
5. Goldberg JE, Steele SR. Rectal foreign bodies. *Surg Clin North Am* 2010;90:173-84.
6. Kurer MA, Davey C, Khan S, Chintapatla S. Colorectal foreign bodies: A systematic review. *Colorectal Dis* 2010;12:851-61.
7. Danielson CK, Holmes MM. Adolescent sexual assault: An update of the literature. *Curr Opin Obstet Gynecol* 2004;16:383-8.
8. Iu VB, Volkov OV, An VK, Dodina AN. Treatment of patients with foreign bodies in rectum. *Khirurgiia (Mosk)* 2000;7:41-3.
9. Busch DB, Starling JR. Rectal foreign bodies: Case reports and a comprehensive review of the world's literature. *Surg* 1986;1003:512-9.
10. Eftaiha M, Hambrick E, Abcarian H. Principles of management of colorectal foreign bodies. *Arch Surg* 1977;112:691-5.
11. Lake P, Essani J, Petrone R, Kaiser P, Asensio A, Beart J, Robert. Management of Retained Colorectal Foreign Bodies: Predictors of Operative Intervention. *Diseases of the colon and rectum*. 2004;47:1694-8. DOI: 10.1007/s10350-004-0676-4.
12. Han HJ, Joung SY, Park SH, Min BW, UM JW. Transrectal rectal foreign body removal using SILS post. *Surg Laparosc Endosc Percutan Tech* 2012;22:e157-8.

Funding: None; Conflict of Interest: None Stated.

How to cite this article: Vishal V, Meena N, Mahendra M. A rare case of presence of unusual foreign body in rectum in homosexual male. *Indian J Case Reports*. 2018;4(3):236-238.