

## Broken sewing needle in the middle finger; a sewing mishap: Management

Mukta Verma<sup>1</sup>, Arun K Singh<sup>2</sup>, Manish Singh<sup>3</sup>

<sup>1</sup>Senior Resident in Department of Plastic Surgery, <sup>2</sup>Head of Department of Plastic Surgery, King George's Medical University, Lucknow, Uttar Pradesh, India, <sup>3</sup>Ex Senior Resident in Department of Pathology, All India Institute of Medical Sciences, New Delhi, India

**Correspondence to:** Mukta Verma, Department of Plastic Surgery, King George's Medical University, Lucknow, Uttar Pradesh, India.  
E-mail: drmukta23@gmail.com

Received – 29 March 2018

Initial Review – 29 April 2018

Published Online – 23 June 2018

### ABSTRACT

Accidental penetrating injuries to the finger are common and their improper assessment can result in missed foreign bodies. These can result in a wide range of complications. Removal of retained foreign bodies is really challenging. We report the case of a male tailor who came to the department with a chief complaint of accidental injury with sewing machine needle and the broken piece of needle got stuck in his finger. This case report highlights the management of deeply embedded broken needle without the use of any expensive investigation. Even preoperative plain X-ray with a radio-opaque marker can localize the missed radio-opaque foreign body accurately. A comprehensive approach results in a successful removal of the foreign body and improved quality of life.

**Key words:** *Finger, Foreign body, Penetrating injury, Sewing needle*

Accidental penetration of needles in the finger is a common practice, particularly among tailors and medical health-care professionals. Most of the times, these are superficial injuries which heal on its own without any sequelae [1]. However, severe penetrating needle injury might leave the broken tip inside the finger; if missed initially, it may get retained in the tissues and remain dormant or else result in a wide range of complications such as pyogenic granuloma, neurovascular deficit, and chronic pain [2-4]. Here, we report a case of a young male tailor who presented with asymptomatic broken sewing machine needle tip in his middle finger for the last 1 month.

### CASE REPORT

A 25-year-old male presented to the outpatient department (OPD) with the complaint of a broken needle inside the right middle finger. There was no other complaint. He was a tailor and, according to him, he sustained sewing machine needle injury to his right middle finger 1 month back while sewing the shirt. The sewing needle penetrated the fingertip from the radial side and came out from the ulnar side. He rushed to the nearby hospital immediately with the needle in the finger. The doctor tried to pull the needle out of the finger but the needle was broken and he could not remove the whole needle. The patient did not give consent for surgical exploration and returned to his home. His puncture wound healed in due course of time and he resumed his daily activities from the next day. There was no pain in the right middle finger but he was worried about the broken needle inside the fingertip. After 1 month, he presented to the plastic surgery OPD for the removal of the broken needle tip.

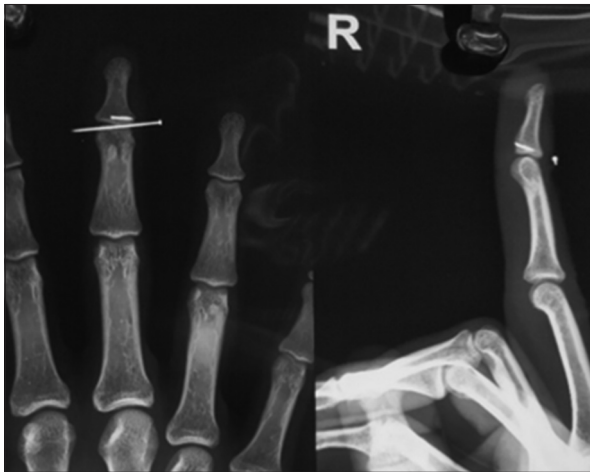
On clinical examination, there was no tenderness and deformity of the fingertip. The fingertip was absolutely normal. A pre-operative plain radiograph (anteroposterior and lateral views) of the middle finger with a pin (radio-opaque marker) over the dorsum fixed with a tape was advised to locate the exact site of the broken needle (Fig. 1).

The patient was taken to the operating room for the exploration and removal of the retained broken needle tip. Digital block with 1% xylocaine (lignocaine) was given, a finger tourniquet was applied, and an incision was given in the distal phalanx (Fig. 2). The broken needle tip was completely embedded in the bone. On careful exploration over the ulnar border of the distal phalanx, the broken needle was localized and removed with the help of an artery forceps without damaging any surrounding neurovascular structures and soft tissue (Fig. 3).

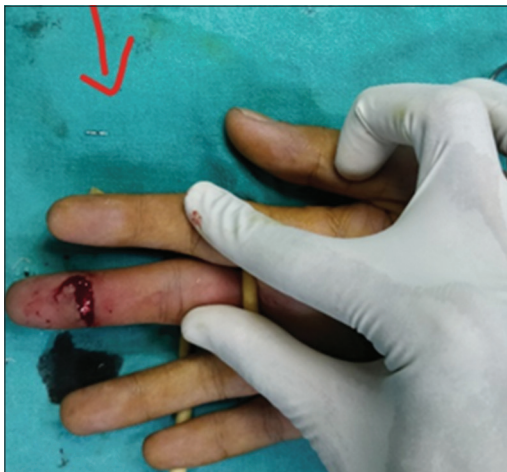The tourniquet was removed and hemostasis was achieved with bipolar electrocautery. An incision was closed with nylon 4-0 and the patient was discharged about 2 h of surgery with the advice of effective elevation of the hand to reduce post-operative edema and pain. The wound healed without any complications and sutures were removed on postoperative day 10. Pre-operative localization of the broken needle with plain radiographs was very helpful for the successful removal of the deeply embedded needle in this case.

### DISCUSSION

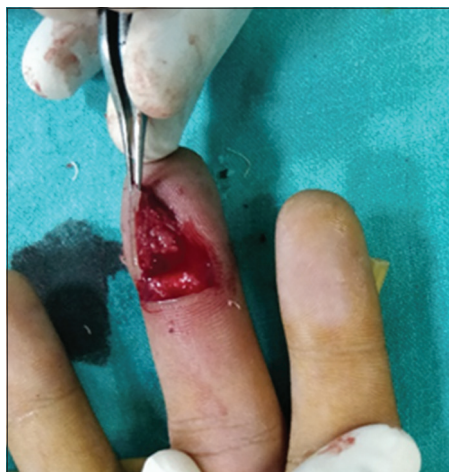Retained foreign bodies most commonly result in pain, delayed wound healing, localized and systemic infection, and further trauma during attempts at removal. Assessment of a patient with a



**Figure 1:** Anteroposterior and lateral views of the middle finger showing the radio-opaque broken needle tip, deeply embedded into the distal phalanx along with radio-opaque marker over dorsum of the fingertip



**Figure 2:** Surgical exploration under digital block with tourniquet (rubber catheter) control; broken sewing machine needle tip lying by the side of finger



**Figure 3:** Careful exploration and successful removal of the retained broken needle tip

suspected foreign body begins with a careful history and physical examination [1-3,5]. History should include the exact mechanism of injury, specific timing and nature of the injury, and the level

of wound contamination. Patient's occupation and previous hand injuries should be inquired for the diagnosis of missed foreign bodies. Hence, the correct diagnosis depends both on imaging and clinical assessment [2,6,7].

Plain radiographs with radio-opaque markers are of great value for localization of radio-opaque foreign bodies [4,8]. Digital plain radiographs are a cost-effective diagnostic tool for the perioperative localization of radio-opaque foreign bodies. This radiological diagnostic facility is easily available everywhere and should be used whenever possible to support the clinical diagnosis. X-ray facility is easily available at primary health centers as well, and intelligent use of preoperative X-ray with a radio-opaque marker can avoid unnecessary referrals of retained foreign bodies as, by using the available imaging facilities, in most of the cases, the exploration can be done on an outpatient basis under local anesthesia [6,9,10].

High-resolution ultrasonography (USG) is an important tool to localize the nonradio-opaque foreign bodies (wood and glass pieces). Intraoperative use of USG has been recommended in the literature as an aid in real-time localization of foreign bodies [7,9-14]. Computed tomography and magnetic resonance imaging if available can, however, provide additional information regarding the location and relationship of a retained foreign body with adjacent tendons, neurovascular bundles, and muscle groups, and thereby guide in the selection of surgical approach and extent of exploration [9,12].

Accurate localization enables surgeons to make smaller and cosmetically acceptable incisions and remove foreign bodies with a minimum amount of dissection and operation time [7,9,10,15]. Salati and Rather also conducted a study on missed foreign bodies in hand in Kashmir and advocated the comprehensive approach of careful history, examination, and radiological investigations for the removal of retained foreign bodies in hand [6]. Literature also supports the use of magnetic forces to remove the missing metallic foreign bodies. It is not always necessary to remove the deeply embedded asymptomatic foreign body, especially if its removal can cause any neurovascular deficit or significant surrounding soft-tissue injury.

## CONCLUSION

Foreign bodies should be suspected and ruled out in all cases of penetrating injuries of fingers. Missed foreign bodies should be removed after proper localization by imaging. In missed foreign bodies, management comprises accurate localization by proper imaging, followed by surgical exploration and removal.

## REFERENCES

1. Anderson MA, Newmeyer WL, Kilgore ES. Diagnosis and treatment of retained foreign bodies in the hand. *Am J Surg* 1982;144:63-7.
2. Boyse TD, Fessell DP, Jacobson JA. US of soft-tissue foreign bodies and associated complications with surgical correlation. *Radio Graph* 2001;21:1251-6.
3. Azzopardi EA, Xuereb CB, Iyer S. Pyogenic granuloma as a surrogate indicator of deep seated foreign bodies: A case report. *Cases J* 2009;2:7354.

4. James W, Robert A, Suzanne M. Vascular complications of a foreign body in the hand of an asymptomatic patient. *Ann Plast Surg* 1995;34:92-4.
5. Veselko M, Trobec R. Intraoperative localization of retained metallic fragments in missile wounds. *J Trauma* 2000;49:1052-8.
6. Salati SA, Rather A. Missed foreign bodies in the hand: An experience from a center in Kashmir. *Libyan J Med* 2010;5:5083.
7. Gilbert FJ, Campbell RS, Bayliss AP. The role of ultrasound in the detection of non-radiopaque foreign bodies. *Clin Radiol* 1990;41:109-12.
8. Ginsburg MJ, Ellis GL, Flom LL. Detection of soft-tissue foreign bodies by plain radiography, xerography, computed tomography and ultrasonography. *Ann Emerg Med* 1990;19:701-3.
9. Mizel MS, Steinmetz ND, Trepman E. Detection of wooden foreign bodies in muscle tissue: Experimental comparison of computed tomography, magnetic resonance imaging, and ultrasonography. *Foot Ankle Int* 1994;15:437-43.
10. McGeorge DD, McGeorge S. Diagnostic medical ultrasound in the management of hand injuries. *J Hand Surg* 1990;2:256-61.
11. Shiels WE, Babcock DS, Wilson JL, Burch RA. Localization and guided removal of soft-tissue foreign bodies with sonography. *Am J Roentgenol* 1990;155:1277-81.
12. Bodne D, Quinn S, Cochran SF. Imaging foreign glass and wooden bodies of the extremities with CT and MR. *J Comput Assist Tomogr* 1988;12:608-11.
13. Coombs CJ, Mutimer KL, Slattery PG, Wise AG. Hide and seek: Preoperative ultrasonic localization of non-radiopaque foreign bodies. *ANZ J Surg* 1990;60:989-91.
14. Schlager D, Saunders AB, Wiggins D, Boren W. Ultrasound for detection of foreign bodies. *Ann Emerg Med* 1991;20:189-91.
15. Gooding GA, Hardiman T, Summers M, Stess R, Graf P, Grunfeld C. Sonography of the hand and foot in foreign body detection. *J Ultrasound Med* 1987;6:441-7.

*Funding: None; Conflict of Interest: None Stated.*

**How to cite this article:** Verma M, Singh AK, Singh M. Broken sewing needle in the middle finger, a sewing mishap: Management. *Indian J Case Reports*. 2018;4(3):224-226.