

Composite conchal loss from Bluetooth headset device: An interesting case report

Mukta Verma¹, Brijesh Mishra², Dekid Palmo³, Shilpi Karmaker⁴

From ¹Department of Plastic and Reconstructive Surgery, King George's Medical University, Lucknow, Uttar Pradesh, India, ²Department of Plastic Surgery, King George's Medical University, Lucknow, Uttar Pradesh, India

Correspondence to: Mukta Verma, 8/189, Jankipuram Extension, Near Bitholi Crossing 226031, Lucknow, Uttar Pradesh, India.

E-mail: drmukta23@gmail.com

Received - 08 March 2018

Initial Review - 13 April 2018

Published Online - 27 May 2018

ABSTRACT

It is a well-known fact that talking on the phone while driving increases the risk of an accident. Bluetooth headset provides simple and uncomplicated route to hands-free communication. While driving, the use of hands-free phone devices such as earpieces and Bluetooth headset is equally as dangerous as talking on a cell phone normally. Here, we are reporting a very unique case of a 25-year-old male who sustained severe ear injury (full-thickness conchal defect of the size of earpiece of Bluetooth headset device; a very unusual mechanism of injury) in a road traffic accident while wearing a Bluetooth headset device. Two-stage repair was done using a retroauricular flap for full-thickness conchal defect. The post-operative cosmetic outcome achieved by this technique was satisfactory.

Key words: Bluetooth headset device, Conchal defect, Flap reconstruction, Retroauricular flap, Road traffic accident

Any trauma to the side of the head can cause injury to the ear due to its prominent position. In our clinical practice, we encounter most of the ear injuries due to road traffic accidents and assaults (slap and human bite) [1,2]. Chances of injuries are more increased due to distraction caused by talking while driving a vehicle. Nowadays, trend is toward using the hands-free devices such as Bluetooth headset devices and earpieces while driving a vehicle. They have been invented to decrease the accidents and increasing the convenience. Someone has rightly said that "prevention is always better than cure." We want to emphasize that these modern inventions can also harm us if not handled with care. Here, we are discussing a case who sustained through and through conchal perforation due to the use of Bluetooth headset device while driving a motorcycle.

CASE REPORT

A 25-year-old male presented in our emergency surgery department with a history of a road traffic accident. He was driving a motorcycle and talking to his friend using Bluetooth headset device, suddenly a cow crossed the road and he lost his balance and fell down from his motorcycle. He presented to us with bleeding and pain in the right ear. There was no injury to any other body part, and there was no history of any difficulty in hearing. On examination, he was oriented to time, place, and person. There was a full-thickness circular conchal defect mainly involving the concha cavum having the skin and cartilage loss in the right ear (Fig. 1). Due to high velocity trauma, the earpiece

of the Bluetooth device perforated the concha cavum completely. Bluetooth device was broken in the accident and the patient left the device at the accident site. For the better understanding of the mechanism of injury, we have shown here another Bluetooth device (Fig. 2a and b).

The external ear was washed thoroughly with normal saline to remove any foreign body. The patient was taken to the emergency operation theater for repair under local anesthesia with 1% lidocaine with epinephrine 1:100,000. Debridement of necrotic tissue was done and conchal defect was covered with local superiorly based retroauricular flap (Figs. 3-5). Donor site was closed primarily without any donor site morbidity. The patient was discharged 2 h after surgery and was advised to follow-up after 24 h. Flap was detached after 3 weeks and in setting was done. With regular dressings and antiseptic precautions, wound healed well with good cosmesis (Fig. 6).

DISCUSSION

On extensive research of literature, we were not able to find any such injury to the ear reported earlier. Chukuezi and Nwosu conducted a study to review the presentation, types, and etiology of ear trauma in 41 patients. Majority (65%) of the patients sustained ear injury due to slaps/blows, 29% due to road traffic accidents and only 2.4% due to foreign body. In this study, no injury was reported due to the usage of Bluetooth device [1]. Another recent study (105 patients) conducted by Colodzynski *et al.* concluded that the main cause of ear injury in their study

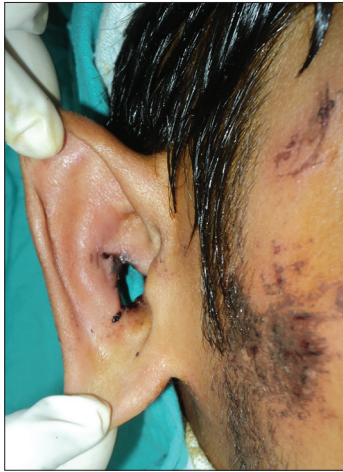

Figure 1: Bluetooth device injury induced full thickness conchal defect

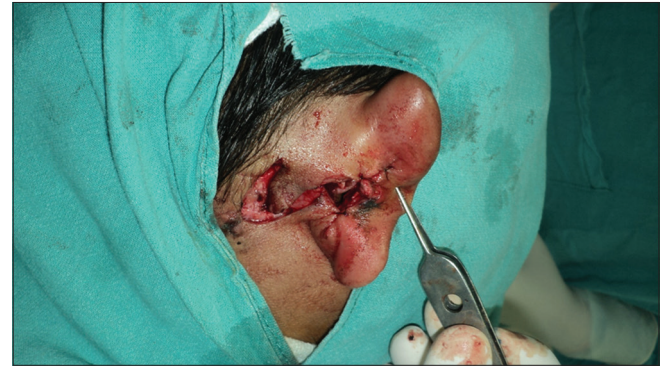

Figure 4: Conchal reconstruction with superiorly based retroauricular flap [posterior view]; Flap elevation

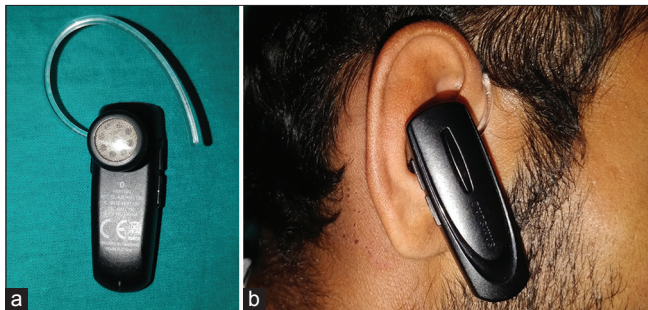


Figure 2: (a and b) Bluetooth device; hard earpiece knob resting in concha cavum

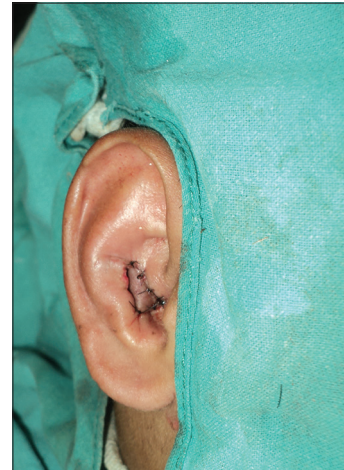

Figure 5: Conchal reconstruction with good aesthetic outcome [anterior view]

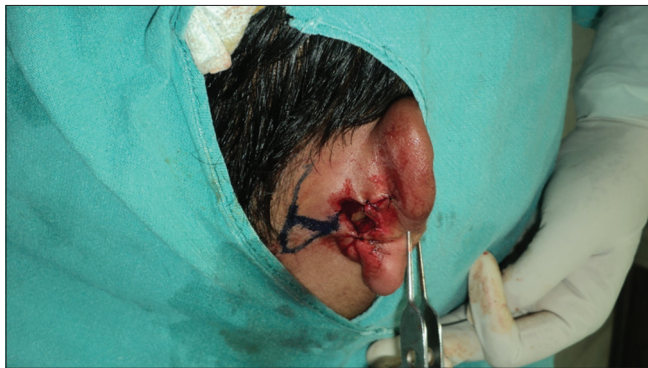

Figure 3: Conchal reconstruction with superiorly based retroauricular flap [posterior view]; Flap marking

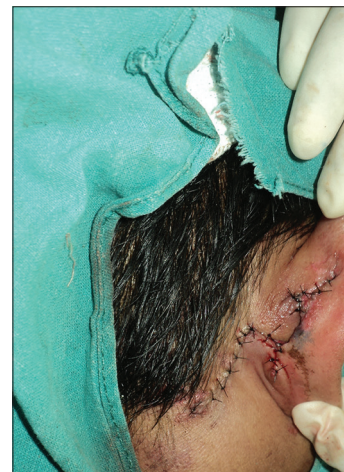

Figure 6: After flap inset post operative [posterior view]

group was bite injuries (22%) followed by traffic accidents (17%) and burns (9.5%). In this study as well, Bluetooth device injury was not the etiology of ear injury [2].

Ear is susceptible to injuries due to its position on face. Lacerations and abrasions are the most common ear injuries. For achieving good esthetic and functional outcome, the golden rule is to do minimal debridement with maximal tissue preservation [3]. Successful reconstruction of auricular deformities requires appropriate restoration of the cartilaginous and soft tissue support. Small defects of the medial surface can be closed primarily. Defects of the lateral skin, however, can rarely be closed given the lack of subcutaneous tissue [4].

Concha serves as a common cartilage donor site for the composite grafts. It has two parts; concha cymba and concha

cavum. It retains the earpiece of the Bluetooth device (Fig. 2). The conchal bowl is a portion of the auricle that is not structurally essential for support; therefore, it allows for some flexibility in the choice of techniques used for the repair of such defects. For defects of the skin with intact perichondrium, the defect can be skin grafted. If the perichondrium is lost, the cartilage should be excised and a full-thickness skin graft should be placed. The skin graft receives its blood supply from the medial subcutaneous tissue. Bolster dressing must be applied to the skin grafts [5-7]. Healing by secondary intention is another viable option for such defects [5,7].

For full-thickness defects, a post-auricular subcutaneous pedicled advancement flap can be utilized to repair the defect. The flap receives its blood supply from the branches of the post-auricular artery. The flap is then tunneled under the medial auricular skin and used to repair the lateral conchal skin defect. The medial skin can be skin grafted or closed depending on the defect. If sufficient flap is mobilized, the flap can be used to repair both the lateral and medial skin surfaces [5,7-10]. It is also important to stress the important role of dressing and good wound care to obtain a better cosmetic outcome [3].

CONCLUSION

This case report shows a unique mechanism of Bluetooth headset device injury to the ear and also good cosmetic results without any donor site morbidity could be obtained by managing the composite conchal defect with retroauricular skin flap.

REFERENCES

1. Chukuezi AB, Nwosu JN. Ear trauma in Orlu, Nigeria: A five year review. *Indian J Otolaryngol Head Neck Surg* 2012;64:42-5.
2. Colodzynski MN, Kon M, Egger S, Breugem CC. Mechanisms of ear

trauma and reconstructive techniques in 105 consecutive patients. *Eur Arch Otorhinolaryngol* 2017;274:723-8.

3. Havlik RJ, Sadove AM. Repositioning the malpositioned ear. *Oper Tech Plast Reconstr Surg* 1997;4:141-5.
4. Armin BB, Ruder RO, Azizadeh B. Ear reconstruction: Partial auricular reconstruction. *Semin Plastic Surg* 2011;25:249-56.
5. Cheney ML, Hadlock TA, Quatela VC. Reconstruction of the auricle. In: Baker SR, editor. *Local Flaps in Facial Reconstruction*. Edinburgh: Elsevier Mosby; 2007. p. 581-624.
6. Elshahy NI. Acquired ear defects. *Clin Plast Surg* 2002;29:175-86, v-vi.
7. Park SS, Hood RJ. Auricular reconstruction. *Otolaryngol Clin North Am* 2001;34:713-38, v-vi.
8. Stucker FJ, Sanders KW. A method to repair auricular defects after perichondrial cutaneous grafting. *Laryngoscope* 2002;112:1384-6.
9. Patterson AR, Brady G, Walker PD, Telfer MR. The perichondrial cutaneous graft and "flip-flop" flap in facial reconstruction: A series of 41 cases. *Br J Oral Maxillofac Surg* 2008;46:114-8.
10. Dessy LA, Figus A, Fioramonti P, Mazzocchi M, Scuderi N. Reconstruction of anterior auricular conchal defect after malignancy excision: Revolving-door flap versus full-thickness skin graft. *J Plast Reconstr Aesthet Surg* 2010;63:746-52.

Funding: None; Conflict of Interest: None Stated.

How to cite this article: Verma M, Mishra B, Palmo D, Karmaker S. Composite conchal loss from Bluetooth headset device: An interesting case report. *Indian J Case Reports*. 2018;4(2):159-161.