

## Meleney's gangrene with superadded aspergillosis: Case report of a rare but fatal surgical complication

Chisel Bhatia, Satish Dalal, Jagat Pal Beniwal, Jitendra Singh Malwal

From Department of General Surgery, Pandit Bhagwat Dayal Sharma Post Graduate Institute of Medical Sciences (P.G.I.M.S.), Rohtak, Haryana, India

**Correspondence to:** Dr. Chisel Bhatia, Room no 354, Doctors' Hostel, Pandit Bhagwat Dayal Sharma Post Graduate Institute of Medical Sciences, Rohtak - 124001, Haryana, India. Phone: +91-8685867197. E-mail: chiselbhatia@gmail.com

Received - 26 January 2018

Initial Review - 14 February 2018

Published Online - 18 March 2018

### ABSTRACT

Meleney's ulcer or post-operative synergistic bacterial gangrene is a rare form of necrotizing infection of the abdominal wall which develops following intra-abdominal surgery. If not promptly identified and treated, it can lead to extensive gangrene leading to fatal complications. We report a case of Meleney's gangrene with superadded aspergillosis which rapidly progressed to gangrene of a large area of the anterior abdominal wall leading to mortality of the patient. We also discuss the difficulties in the management of such cases highlighting the need of early and aggressive debridement besides other measures.

**Key words:** Blunt abdominal trauma, Meleney's gangrene, necrotizing fasciitis

**N**ecrotizing fasciitis is a rapidly progressive, deep-seated bacterial infection of the subcutaneous soft tissue that can involve any area of the body. Most necrotizing soft tissue infections occur in the extremities, abdomen, groin, and perineum. Various terms have been used to describe necrotizing soft tissue infections. Meleney's synergistic gangrene is a type of necrotizing infection of the anterior abdominal wall which usually occurs after a surgical procedure with *Staphylococcus aureus* and microaerophilic *Streptococci* as the etiological agents. If not detected and treated at an early stage, it can progress rapidly to lead high rates of morbidity and mortality. Differentiation from cellulitis and abscesses is important but difficult in the early phase because of a paucity of early signs, and this condition is usually diagnosed because the disease continues to progress in spite of therapy. Here, we discuss a case of Meleney's gangrene with superadded aspergillosis with difficulties encountered in the management of such cases.

### CASE REPORT

A 40-year-old female with no comorbidities presented to the surgical emergency department with a history of blunt trauma abdomen. On inspection, there were multiple abrasions on the anterior abdominal wall. The abdomen was tender with guarding and rigidity. The patient was hemodynamically stabilized and underwent a contrast-enhanced computed tomography scan of the abdomen which revealed pneumoperitoneum, with the presence of free fluid in the peritoneal cavity and Grade-II injury to the left kidney. The patient underwent an emergency exploratory laparotomy with intraoperative findings revealing a

perforation of size 1.5×1 cm in the anterior wall of the stomach and retroperitoneal hematoma around the left kidney. Repair of the stomach perforation with peritoneal lavage was performed. The retroperitoneal hematoma was not explored since it was not expanding and the vitals of the patient were within normal limits. The patient was doing well in the immediate post-operative period, but on post-operative day 6, she developed black discoloration on the lower end of the midline laparotomy incision with local rise of temperature. Her pulse rate was 104 beats/min, temperature was 100.4°C, and blood pressure was 100/76 mm of Hg. On investigating, total leukocyte count was 22,000/mm<sup>3</sup>, with neutrophilia. The sutures at the involved site were opened, and gangrenous changes in the subcutaneous plane were seen. Bedside debridement was done under local anesthesia for 2 consecutive days which revealed necrosis localized around the incision site, but the infection continued to spread with gangrenous changes of the skin, subcutaneous tissue, and facial planes (Fig. 1). The antibiotic was ascended from intravenous ceftriaxone, amikacin, and metronidazole to intravenous meropenem 1 g Q6h on 7<sup>th</sup> post-operative day. In view of extensive necrosis, the patient was taken to the operating room on the 8<sup>th</sup> post-operative day and the gangrenous changes were found to be penetrating deep up to the posterior rectus sheath and extending up to xiphoid process superiorly, pubic symphysis inferiorly, and the anterior axillary lines bilaterally. The affected area was aggressively debrided (Fig. 2). Bogota bag was applied for closure of the wound (Fig. 3), and the patient was transferred to the Intensive Care Unit for post-operative care. 2 days later (10<sup>th</sup> post-operative day), there was a growth of fungal colonies on the wound (Fig. 4). Intravenous voriconazole was added in the treatment. The cultures from the

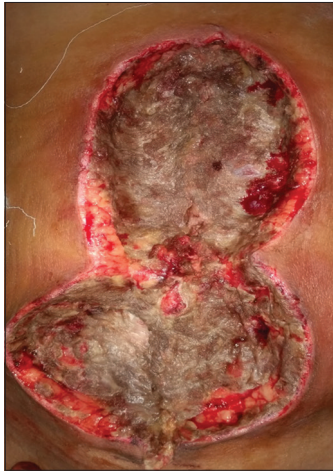

Figure 1: Gangrenous changes in the subcutaneous tissue and rectus sheath

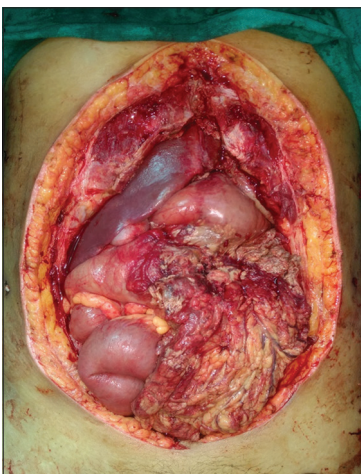


Figure 2: Photograph showing the extent of resection done for anterior abdominal wall gangrene

wound and tissue biopsy revealed the growth of *S. aureus* and invasive *Aspergillosis*. Despite aggressive surgical and medical management, infection could not be controlled and the patient expired on 11<sup>th</sup> post-operative day due to septicemia.

## DISCUSSION

Necrotizing fasciitis is a rare disease with an incidence reported to be between 500 and 1500 cases per year in the United States. It is a life-threatening, soft-tissue infection characterized by rapidly spreading inflammation and necrosis of the skin, involving the subcutaneous tissues and fascia due to the spread of the bacteria among and inside the skin surface [1]. Historically, necrotizing infections were classified according to anatomical sites. Fournier's gangrene (involving the scrotum and perineum) and Ludwig's angina (involving submandibular and sublingual spaces) and Meleney's synergistic gangrene (involving abdominal wall) are examples. These infections were named after the physicians who first described them [2]. In 1952, the term "necrotizing fasciitis" was proposed by Wilson, as a more accurate description of this disease [3].

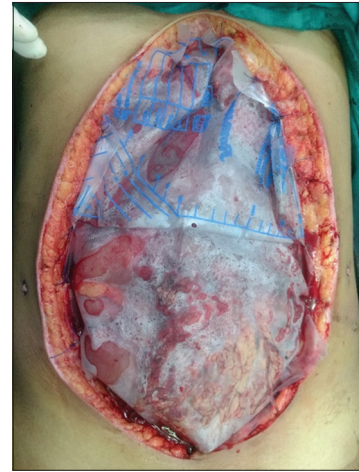

Figure 3: Bogota bag applied for wound closure

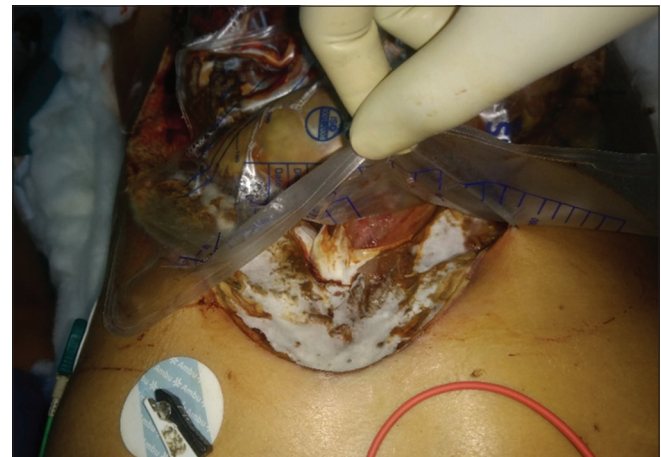

Figure 4: Photograph showing growth of fungal colonies on the debrided wound

Meleney's ulcer or post-operative synergistic bacterial gangrene is the term given to a rare form of necrotizing infection of the abdominal wall which develops following intra-abdominal surgery in the immediate vicinity of the surgical wound. It is caused by synergistic interaction between microaerophilic non-hemolytic *Streptococcus* and hemolytic aerobic *S. aureus* [4].

The disease was first described by Meleney and Brewer in 1926. It is a deadly infection with a mortality rate of 34% and has been tagged as "Meleney's Minefield"[5]. Most patients with post-operative synergistic gangrene have pre-existing immunosuppressive condition such as diabetes mellitus, chronic renal failure, and HIV or are the elderly or obese. Our patient was a healthy middle-aged female with only identifiable risk factor being surgery for blunt trauma abdomen.

Diagnosing post-operative synergistic gangrene is difficult due to the paucity of early cutaneous signs and is frequently misdiagnosed as cellulitis or abscess. Hence, it is of utmost importance to be able to identify the signs such as characteristic bullae in the anterior abdominal wall with subsequent full thickness skin and facial necrosis. Any delay in diagnosis can lead to fatal consequences. Freischlag *et al.*, in 1985, found that Meleney's gangrene if treated after 24 h of recognition had mortality rates as high as 70% as compared to 35% if treated within 24 h [6].

The management of post-operative synergistic gangrene is aggressive resuscitation, surgical debridement with excision of all dead tissues, and targeted elaboration of broad-spectrum antibiotics. Serial debridements are usually necessary to completely remove the dead devitalized tissue. Hyperbaric oxygen therapy can be used as an adjunct to this which allows large amounts of oxygen to be dissolved into the blood and tissues, allowing for the revitalization of tissues with poor circulation [7]. Once a healthy granulating wound is achieved, skin grafts/flaps are recommended to cover the extensive defects resulting from debridement. The use of negative pressure wound therapy in the management of these patients has been reported to improve survival and shorten treatment times [5].

Patients with Meleney's gangrene usually have a long hospital stay with multiple debridements and stress of multiple surgeries. Sepsis is a life-threatening complication which leads to high rates of morbidity and mortality. During their stay in the hospital, the patients are exposed to the risk of hospital-acquired infections which poses further difficulties in wound management.

Superadded fungal infections following necrotizing fasciitis are rare with very few cases reported in literature and mostly seen in immune-compromised patients. In 1989, Falsey *et al.* reported rapidly progressive, fatal *Aspergillus fumigatus* infection of a wound following debridement for necrotizing fasciitis [8]. In 2004, Daniel Brown reported *Candida* as the sole organism in a case of post-operative necrotizing fasciitis of the thigh and scrotum [9]. Our patient developed superadded aspergillosis on the debrided wound which further worsened the prognosis. The disease in our patient progressed so rapidly within a short period of time that the extent of debridement was excessive and wound management in such patients poses a great difficulty. Even with broad-spectrum antibiotics and antifungal drugs, the gangrene continued to progress leading to septicemia and mortality of the patient.

## CONCLUSION

Post-operative synergistic gangrene is a deadly condition which progresses rapidly and is commonly misdiagnosed as cellulitis or abscess which leads to delay in treatment. A high index of suspicion is required in patients who develop wound infections postoperatively to make the diagnosis of this entity. A bulla or blistering of skin with gangrenous changes in the subcutaneous tissue should be dealt with aggressive resuscitation and adequate surgical debridement.

## REFERENCES

1. Carbonetti F, Cremona A, Guidi M, Carusi V. A case of postsurgical necrotizing fasciitis invading the rectus abdominis muscle and review of the literature. *Case Rep Med* 2014;2014:479057.
2. Vijayakumar A, Pullagura R, Thimmappa D. Necrotizing fasciitis: Diagnostic challenges and current practices. *Infect Dis* 2014;2014:Article ID: 208072, 8.
3. Misiakos EP, Bagias G, Patapis P, Sotiropoulos D, Kanavidis P, Machairas A, *et al.* Current concepts in the management of necrotizing fasciitis. *Front Surg* 2014;1:36.
4. Waweru JM. Meleney's ulcer; a rare but fatal abdominal wall disease complicating laparotomy. *Ann Afr Surg* 2014;11:1.
5. Akhator A. Postoperative synergistic gangrene on the anterior abdominal wall- report of a case. *Cont J Trop Med* 2010;4:23-6.
6. Freischlag JA, Ajalat G, Busuttill RW. Treatment of necrotizing soft tissue infections; The need for a new approach. *Am J Surg* 1985;149:751-5.
7. Gupta A, Gupta G, Sharma A. Meleney's Gangrene: Simple debridement and antiseptic dressings can save a patient's life. *J Med Sci Clin Res* 2017;5:17153-6.
8. Falsey AR, Goldsticker RD, Ahern MJ. Fatal subcutaneous aspergillosis following necrotizing fasciitis: A case report. *Yale J Biol Med* 1990;63:9-13.
9. Eisen DB, Brown E. Necrotizing fasciitis following a motor vehicle accident with *Candida* species as the sole organisms. *Can J Plast Surg* 2004;12:43-4.

*Funding: None; Conflict of Interest: None Stated.*

**How to cite this article:** Bhatia C, Dalal S, Beniwal JP, Malwal JS. Meleney's gangrene with superadded aspergillosis: Case report of a rare but fatal surgical complication. *Indian J Case Reports*. 2018;4(2):95-97.