

Primary transitional cell carcinoma of bulbar urethra

Krishnendu Maiti, Siddharth Saraf, Chhanda Datta, Dilip Kumar Pal

From Department of Urology, Institute of Post Graduate Medical Education and Research, Kolkata, West Bengal, India

Correspondence to: Dilip Kumar Pal, Department of Urology, Institute of Post Graduate Medical Education and Research, 244, AJC Bose Road, Kolkata – 700 020, West Bengal, India. Phone: 0091-033-22041388. E-mail: urologyipgmer@gmail.com

Received - 23 December 2017

Initial Review - 21 January 2018

Published Online - 02 March 2018

ABSTRACT

Primary urethral carcinoma (UC) is a rare entity, and bulbar UCs of transitional cell origin are even rarer. Primary presentation as a scrotal abscess and urethrocutaneous fistula is rarely documented in UC patients. We present a case of a 66-year-old male presenting to emergency department with a scrotal abscess. Following blind incision and drainage, the urethral injury was suspected, and biopsy of suspicious lesion was taken from scrotum which came out to be invasive transitional cell carcinoma. A wide local excision of the tumor was done after workup. Hence, all patients with scrotal abscess and urethrocutaneous fistula should be investigated before performing any blind procedure.

Key words: *Transitional cell carcinoma, urethral carcinoma, urethrocutaneous fistula*

Primary urethral carcinoma (UC) is considered to be rare cancer, accounting for <1% of all malignancies [1]. Carcinomas of the bulbomembranous urethra are of squamous cell origin in 80%, transitional cell origin in 10%, and adenocarcinoma or undifferentiated in 10% [2]. At initial presentation visible hematuria or bloody urethral discharge is reported in up to 62% of the cases, however, symptoms of locally advanced disease include an extra urethral mass (52%), bladder outlet obstruction (48%), pelvic pain (33%), urethrocutaneous fistula (10%), abscess formation (5%), or dyspareunia [3]. Here, we present a case of a primary bulbar UC of transitional cell origin which presented as a scrotal abscess subsequently causing a diagnostic dilemma.

CASE REPORT

A 66-year-old man presented to the emergency surgical department with swelling, pain, and pus discharge from the scrotum in midline since 5 days. The patient underwent an incision and drainage on clinical suspicion and urethra was breached during the procedure. Suprapubic cystostomy (SPC) and biopsy from the suspicious region were taken. Histopathology was suggestive of infiltrating transitional cell carcinoma of urethra (Fig. 1). On further questioning, the patient revealed the history of voiding lower urinary tract symptoms and per urethral bleeding on and off. The patient was a known case of diabetes mellitus and hypertension from 5 years. He was a chronic smoker from past 25 years.

General physical examination of the patient was unremarkable. On local examination, external urethral meatus was narrow; urethrocutaneous fistula was present at the scrotum in midline with pus discharge and induration along the previous incision

(Fig. 2). Inguinal lymph nodes were not palpable. Digital rectal examination was within normal limits. Routine blood investigations were within normal limits except total leukocyte count which was 13,000 and serum creatinine which was 2.4 mg/dl initially but later decreased to 1.2 mg/dl 2 weeks after SPC. The patient presented to us with a pre-operative retrograde urethrogram (Fig. 3a) and micturating cystourethrogram (Fig. 3b) which was suggestive of a long stricture of the penile urethra with extravasation of contrast at bulbar urethra into a large collection in the scrotum and diverticula in the urinary bladder. The posterior urethra was normal.

A contrast enhanced computed tomography was done to evaluate the upper urinary tract, chest, and abdomen which were normal. Antegrade cystoscopy of the patient revealed a normal posterior urethra. To further characterize the lesion, magnetic resonance imaging (MRI) of pelvis was done which revealed a large space occupying lesion (56 mm × 51 mm × 64 mm) in bulbar part of urethra involving corporal bodies without lymph node enlargement (Fig. 4). Total penectomy with anterior urethrectomy with left orchiectomy was done. Intraoperatively, the growth was found confined to bulbar urethra. Posterior urethra was found to be normal. Prostatomembranous junction was taken as the posterior margin. Left scrotum found to be indurated. The specimen was sent for histopathology. The patient was stable in the post-operative period and was discharged with SPC *in situ*. On histopathology, microscopy suggested invasive urothelial carcinoma. All the margins were free from tumor. The patient is in close follow-up in the department of urology as well as medical oncology. A follow-up ultrasonography of whole abdomen was done which revealed mild prostatomegaly and no evidence of any lymph nodes.

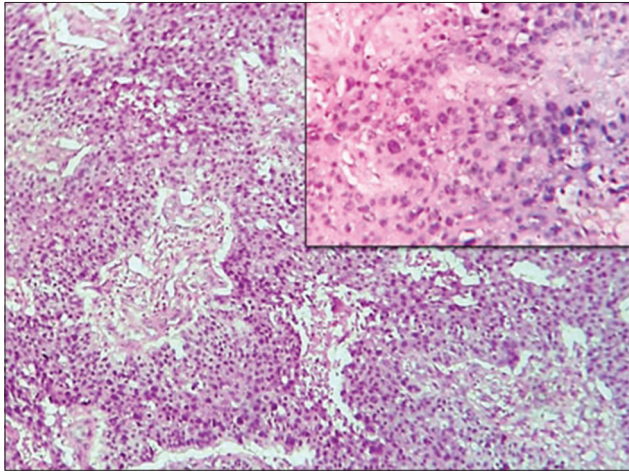


Fig. 1 Disorganised papillae showing high grade nuclear features (H and E original magnification 100×) Inset: (400× magnification). Nuclear pleomorphism with clumped chromatin, prominent nucleoli, and irregular nuclear membranes

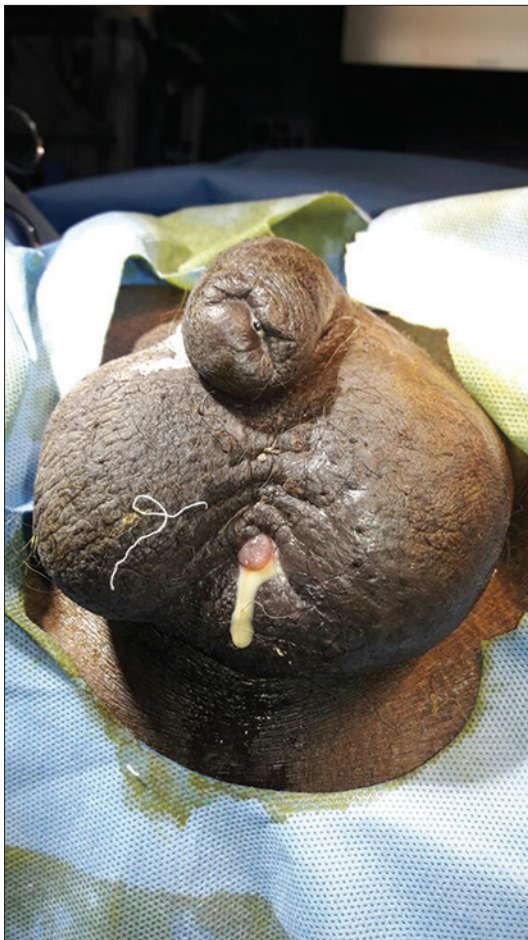

Fig. 2 Local Examination showing urethra-cutaneous fistula and pus discharge.

DISCUSSION

Primary UC is considered to be a rare cancer. According to surveillance, epidemiology, and end results database, the incidence of primary UC was majorly in the 75 years and above age group [4]. For male primary UC, various predisposing factors have been reported,

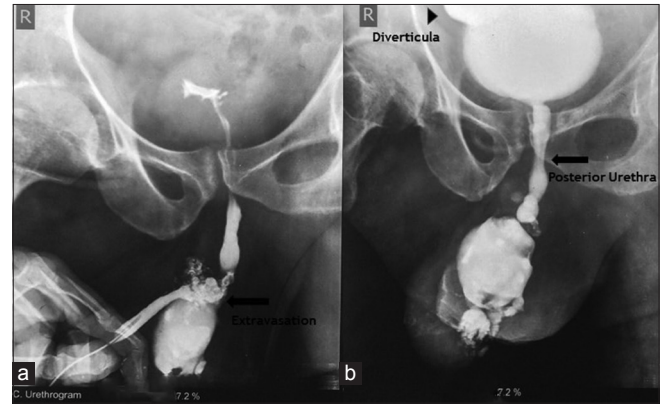


Fig. 3: (a) Retrograde urethrogram showing long stricture of the penile urethra with extravasation of contrast (arrow) into a large collection in the scrotum. (b) Micturating cystourethrogram showing obstructive changes with diverticula (arrow head) in the urinary bladder and normal posterior urethra (arrow)

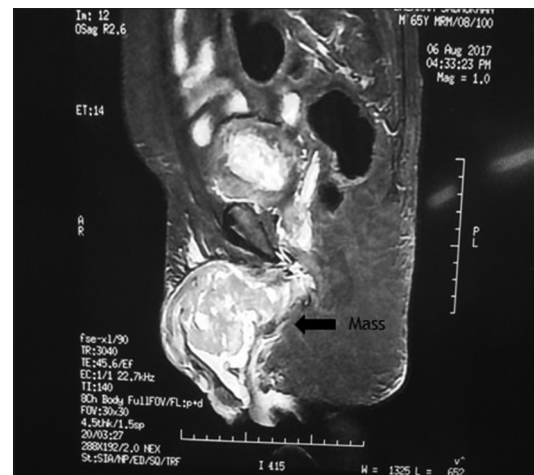

Fig. 4: A large mass (56 mm × 51 mm × 64 mm) seen in bulbar part of urethra (arrow) involving corpora cavernosa and spongiosa

including urethral strictures, chronic irritation after intermittent catheterization, urethroplasty, radiation therapy, and chronic urethral inflammation following sexually transmitted diseases. In female UC, urethral diverticula and recurrent urinary tract infections have been associated with primary UC [5]. The bulbomembranous urethra is involved most frequently, accounting for 60% of tumors, followed by the penile urethra (30%) and prostatic urethra (10%).

The histologic subtype of urethral cancer varies by anatomic location. Carcinomas of the prostatic urethra are of transitional cell origin in 90% and squamous cell origin in 10%; carcinomas of the penile urethra are of squamous cell origin in 90% and transitional cell origin in 10%; carcinomas of the bulbomembranous urethra are of squamous cell origin in 80%, transitional cell origin in 10%, and adenocarcinoma or undifferentiated in 10%. Hematuria or bloody urethral discharge is reported in up to 62% of the cases. Symptoms of locally advanced disease include extra urethral mass (52%), bladder outlet obstruction (48%), pelvic pain (33%), urethrocutaneous fistula (10%), and abscess formation (5%) [3].

For local staging and monitoring tumor response to neoadjuvant chemoradiotherapy, MRI is an accurate tool before

surgery [6]. CT of the thorax and abdomen should be considered for metastatic workup in all patients with invasive disease [7]. Prophylactic bilateral inguinal and/or pelvic lymphadenectomy is still under scrutiny. However, in patients with clinically enlarged inguinal/pelvic lymph nodes or invasive tumors, regional lymphadenectomy should be considered for initial treatment in limited disease [8]. Partial penectomy with a 2-cm negative margin remains the traditional treatment for tumors infiltrating the corpus spongiosum and localized to the distal half of the penis. Excellent local control after this procedure has been documented [9]. If invasive disease extends to or involves the proximal penile urethra, total penectomy is required to obtain an adequate margin of excision.

A local recurrence rate of 13% has been reported after this procedure. Primary radiation therapy has been reserved for patients, which presents with early stage lesions of the anterior urethra and refuses surgery. Chemoradiation with mitomycin-c and 5-FU along with concurrent external beam radiation therapy has been reported as a treatment modality for patients with invasive anterior urethral cancer with the intent of genital preservation [10]. Further studies are needed to validate this modality.

CONCLUSION

Primary UC is a rare entity. Although rare, a patient presenting with scrotal abscess and urethra-cutaneous fistula may harbour a urethral carcinoma underneath and cause diagnostic dilemma. Therefore, adequate imaging should be considered before any surgical procedure. Given the low incidence of primary urethral cancer, follow-up has not been investigated systematically so far.

Urinary cytology, urethroscopy, and cross-sectional imaging should be considered despite the lack of sufficient data.

REFERENCES

1. Gatta G, van der Zwan J, Casali P, Siesling S, Dei Tos A, Kunkler I, *et al.* Rare cancers are not so rare: The rare cancer burden in Europe. *Eur J Cancer* 2011;47:2493-511.
2. Grigsby PW, Herr HW. Urethral tumors. In: Vogelzang N, Scardino PT, Shipley WU, Coffey DS, editors. *Comprehensive Textbook of Genitourinary Oncology*. 2nd ed. Baltimore: Williams & Wilkins; 2000. p. 1133-40.
3. Gheiler EL, Tefilli MV, Tiguert R, de Oliveira JG, Pontes JE, Wood DP Jr, *et al.* Management of primary urethral cancer. *Urology* 1998;52:487-93.
4. Swartz MA, Porter MP, Lin DW, Weiss NS. Incidence of primary urethral carcinoma in the united states. *Urology* 2006;68:1164-8.
5. Chung DE, Purohit RS, Girshman J, Blaivas JG. Urethral diverticula in women: Discrepancies between magnetic resonance imaging and surgical findings. *J Urol* 2010;183:2265-9.
6. Gourtsoyianni S, Hudolin T, Sala E, Goldman D, Bochner B, Hricak H. MRI at the completion of chemo radiotherapy can accurately evaluate the extent of disease in women with advanced urethral carcinoma undergoing anterior pelvic exenteration. *Clin Radiol* 2011;66:1072-78.
7. Stewart SB, Leder RA, Inman BA. Imaging tumors of the penis and urethra. *Urol Clin North Am* 2010;37:353-67.
8. Karnes RJ, Breau RH, Lightner DJ. Surgery for urethral cancer. *Urol Clin North Am* 2010;37:445-57.
9. Kaplan G, Bulkley G, Grayhack J. Carcinoma of the male urethra. *J Urol* 1967;98:365-71.
10. Cohen M, Triaca V, Billmeyer B, Hanley R, Girshovich L, Shuster T, *et al.* Coordinated chemoradiation therapy with genital preservation for the treatment of primary invasive carcinoma of the male urethra. *J Urol* 2008;179:536-41.

Funding: None; Conflict of Interest: None Stated.

How to cite this article: Maiti K, Saraf S, Datta C, Pal DK. Primary transitional cell carcinoma of bulbar urethra. *Indian J Case Reports*. 2018;4(1):40-42.