

## Xanthogranulomatous pyelonephritis in a child: A rare entity

Shobha Sharma, Nidhi Chopra, Nidhi Sugandhi, Kailash Chandra Agarwal

From Department of Paediatrics, Vardhman Mahavir Medical College and Safdarjung Hospital, New Delhi, Tamil Nadu, India

**Correspondence to:** Shobha Sharma, Department of Paediatrics, 1228, Type IV (Special), Ground Floor, R K Puram Sector-12, New Delhi, India. Phone: +91-8527165677. E-mail: [oum.shobha76@gmail.com](mailto:oum.shobha76@gmail.com)

Received - 08 June 2017

Initial Review - 23 June 2017

Published Online - 15 July 2017

### ABSTRACT

Xanthogranulomatous pyelonephritis (XGP) is chronic pyelonephritis uncommonly described in adults and is rare in children. It is characterized by the replacement of renal parenchymal tissue by lipomatous cells making it nonfunctional and may be mistaken for pyonephrosis, cystic or solid tumor, and the most commonly, Wilms tumor. It often presents as abdominal mass in children and more commonly involves left kidney. Imaging by computed tomography (CT) scan is characteristic, and histology is diagnostic. We are reporting a case of a child who presented with prolonged febrile illness and documented urinary tract infection with nephrolithiasis without any abdominal lump and received antibiotics for multiple times without any improvement. Ultrasonography was suggestive of pyonephrosis and multiple abscesses. However, on CT scan, was diagnosed as XGP of the right kidney which was confirmed on histology. After documenting, no function in affected kidney with other being normal, unilateral nephrectomy was done resulting in rapid symptomatic improvement.

**Key words:** *Chronic pyelonephritis, Children, Xanthogranulomatous pyelonephritis*

Xanthogranulomatous pyelonephritis (XGP) is an unusual type of chronic infective pyelonephritis, in which yellow lobulated masses diffusely replace the normal renal parenchyma making it non-functional in most of the cases. XGP is an uncommon disease; predominantly, affecting middle-aged women, and rarely children. The disease is characterized by an accumulation of foamy histiocytes, macrophages with mature adipocytes, and occasional giant cells. There is often diagnostic delay and also confusion with other renal pathologies such as tumour, cystic mass, and tuberculosis. Its etiology remains unclear although as many as 6 causes have been proposed: (1) Urinary obstruction, (2) urinary tract infection, (3) abnormal lipid metabolism, (4) lymphatic obstruction, (5) altered immune response, and (6) vascular occlusion [1]. Historically, most of the XGP cases were diagnosed by histopathology after nephrectomy, because the clinical and radiologic features are difficult to describe [2]. Early diagnosis is important as surgical excision, usually partial or complete unilateral nephrectomy is treatment of choice and leads to rapid symptomatic improvement.

### CASE REPORT

A 7-year-old male child presented with a complaint of fever for 4 months. His history was significant with recurrent history of fever for the last 2 years and was diagnosed as having right-sided nephrolithiasis. He had pus cells in urine documented multiple times and was treated with antibiotics on and off basis from some

local hospital. The child also had history of developmental delay with failure to gain weight and height. The child was operated for bilateral cataract at 2½ years of age. He had history of polyuria since infancy. The child belonged family from rural area in Uttar Pradesh. There was history of two male sibling deaths at 4.5 and 11 years, respectively with a similar history of polyuria, failure to thrive, and bilateral cataract for which they were never worked up for cause.

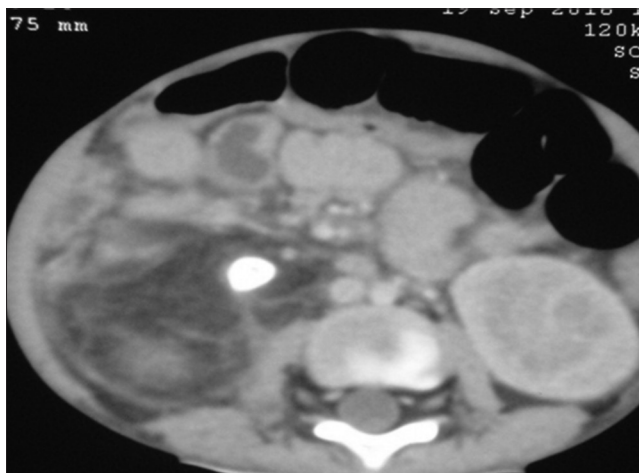On presentation, child was thin built with microcephaly (weight - 9 kg, height - 92 cm and head circumference - 42 cm, body mass index of 10.7 kg/m<sup>2</sup>. His blood pressure was 100/58 mm-Hg, and he was not interested in surroundings, irritable, and febrile. On investigations, he had Hb of 7.0 g/dl, total leukocyte of 11,800/mm<sup>3</sup>, and platelet count of 676,000/mm<sup>3</sup>. Serum calcium was 9.6 mg/dl, and serum phosphate was 4.7 mg/dl. Significant hypokalemia with serum K between 2.6 and 2.5 mEq/l documented three times. Venous blood gas showed compensated non-anion-gap metabolic acidosis with pH of 7.35, serum HCO<sub>3</sub> of 14 mEq/l, and serum chloride of 119 mEq/l. Kidney function tests were normal (blood urea of 22 mg/dl, serum creatinine 0.2 mg/dl). Urine routine microscopy had proteinuria, significant number of pus cells and urine culture showing significant growth of *Escherichia coli*.

Ultrasonography (USG) abdomen showed normal size left kidney with mild hydronephrosis and enlarged right kidney with multiple small calculi on the upper, middle, lower pole largest at lower pole - 6 mm and a staghorn calculus. Contrast-enhanced

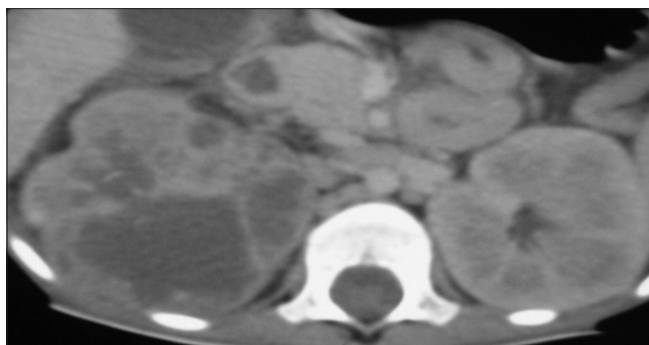
computed tomography (CECT) abdomen showed proximal ureteric calculus in the right kidney causing gross hydronephrosis with multiple abscesses in the upper pole (Figs 1-3). Marked fat proliferation and inflammatory changes were suggestive of XGP. diethylenetriaminepentacetic acid (Tc99m-DTPA) scan showed no function in the right kidney with normal functioning left kidney. Dimercaptosuccinic acid (Tc99m-DMSA) scan showed non-visualized right kidney with impaired cortical function without any evidence of cortical defect in the left kidney (Figs 4 and 5).

In view of failure to thrive, bilateral congenital cataract, positive family history, non anion-gap metabolic acidosis, nephrolithiasis, and hypokalemia suspicion of hereditary proximal tubular disorder (Lowe syndrome) was kept. On further evaluation, there was no hypercalciuria or glycosuria. However, 24 h beta 2 microglobulin in urine was highly increased (12000 µg/ml) with generalized aminoaciduria. Echocardiography and brainstem evoked response audiometry (BERA) for hearing assessment were normal while MRI brain revealed mild diffuse cerebral atrophy. Genetic analysis for confirmation of Lowe's syndrome was planned but could not be performed due its unavailability in our setup and cost constraints.

Due to non-functional kidney with increasing mass effect on the right side pediatric surgery, consultation was taken and



**Figure 1:** Contrast-enhanced computed tomography abdomen showing staghorn calculus in proximal ureter of the right kidney with surrounding hypodense area suggestive of abscess. Left kidney normal

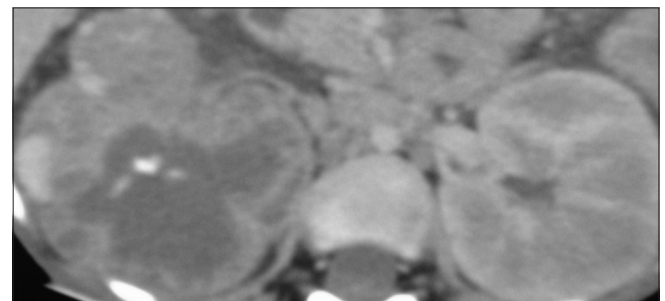


**Figure 2:** Contrast-enhanced computed tomography abdomen showing gross hydronephrosis of right kidney with multiple hypodense areas suggestive of abscesses. Mild hydronephrosis of the left kidney

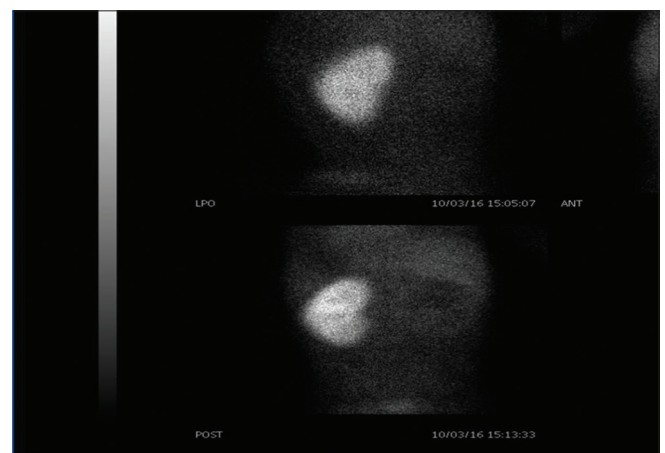
right nephrectomy was done. Peroperatively, grossly entire right kidney was replaced by small cysts with cheesy material and fat. Histological examination revealed complete loss of glomerular and tubular architecture with lipid-laden foam cells on light microscopy (Figure 6). Postnephrectomy course uneventful with rapid recovery and resolution of long-standing fever, maintenance of good urine output, improvement in appetite, and general well-being of the child.

## DISCUSSION

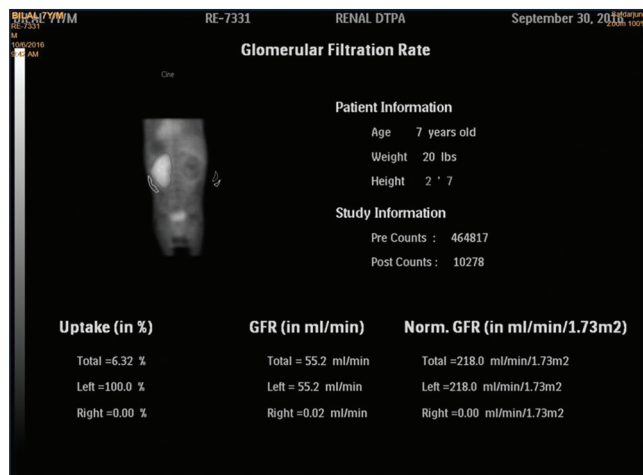
XGP is an unusual variant of chronic pyelonephritis and occurs usually after prolonged obstruction due to infected renal stones, mainly reported in adults [1-6]. Although exact incidence is not known, each year 1.4 cases per 100,000 occur worldwide [3]. XGP is a rare entity in children, and approximately, 82 cases reported till date in literature [7]. Most of the cases diagnosed histopathologically after nephrectomy, which is the treatment of choice in diffuse forms. Affected patients usually have massive destruction of the kidney due to granulomatous tissue containing lipid-laden macrophages. It is a rare disorder. Presenting symptoms in the children include flank and abdominal pain, fever, and growth and weight retardation. Approximately 50% of the children have a palpable abdominal mass. Bacteriuria and pyuria are found in 50-70% of cases with *Proteus* (60%) and *E. coli* being the most common causative organisms [8].



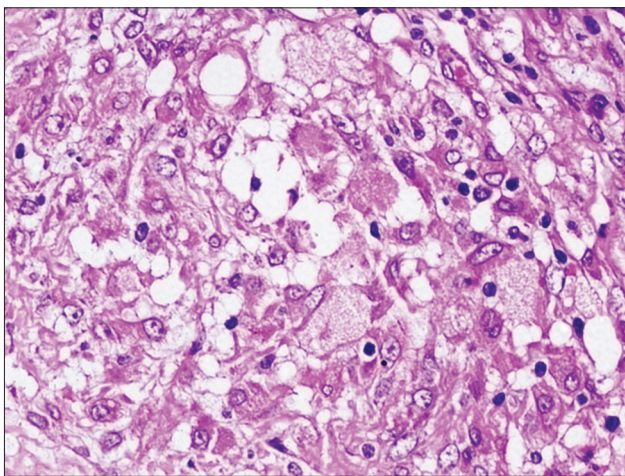
**Figure 3:** Contrast-enhanced computed tomography abdomen showing gross hydronephrosis with distorted outline of right kidney with "bear-paw" sign



**Figure 4:** Renal dimercaptosuccinic acid scan showing unilateral uptake of radioisotope in the left kidney



**Figure 5:** Renal diethylenetriaminepentacetic acid (Tc99m-DTPA) scan showing relative glomerular filtration rate in both kidneys



**Figure 6:** Light microscopy showing lipid-laden foam cells

Two forms of XGP have been described: Diffuse (83-90%) and focal (10-17%). Focal variety is often misdiagnosed as renal mass confusing with complex cysts, renal malignancy, or inflammatory pseudotumor [9,10]. Malek and Elder proposed a staging system for XGP: Stage I, the lesion is confined to the kidney; stage II, there is an infiltration of the Gerota space; and stage III, XGP extends to the perinephric space and other retroperitoneal structures [4]. USG is the initial imaging modality and may show a generalized renal enlargement with multiple hypoechoic areas representing calyceal or pelvicalyceal dilatation and parenchymal destruction, hyperechoic foci with clean posterior acoustic shadowing representing renal calculi or a staghorn stone, and debris in the hydronephrosis.

CT, which is considered the imaging modality of choice and characteristic features in diffuse form is renal enlargement, thickening of the Gerota fascia, and thick enhancing septa in the hypodense areas of the renal parenchyma with areas of water density representing dilated calyces and abscess cavities with pus and debris described as the “bear paw sign” [11]. Stones (frequently of staghorn proportions) are associated in 80% of the patients with XGP. Its usually unilateral and more commonly reported on the left side [12,13]. A very atypical feature in our child was evidence

of proximal tubulopathy with associated positive family history suggestive of Lowe syndrome although we could not get genetic confirmation. We did not get any similar association in literature. One explanation could be the presence of chronic nephrolithiasis due to Lowe’s syndrome and subsequent development of chronic pyelonephritis. Management is primarily surgical, and nephrectomy is the treatment modality of choice in diffuse forms as was done in our child leading to symptomatic improvement; however, long-term follow-up is needed to observe the course of tubular involvement.

## CONCLUSION

Although a rare condition in children, XGP has important therapeutic and prognostic implications as early diagnosis is difficult due to confusion with pediatric renal tumors, cystic lesions, tuberculosis and renal abscess. Early diagnosis is important to promote better survival and clinical outcomes.

## REFERENCES

1. Yousof A, Aldhilan A, Alamer A, Fahad A. Renal squamous cell carcinoma presented with bone metastasis and coexistence with xanthogranulomatous pyelonephritis: A case report. *Urol Case Rep.* 2014;2(2):35-7.
2. Nam JK, Park SW, Lee SD, Chung MK. Xanthogranulomatous pyelonephritis in Korean children. *Yonsei Med J.* 2012;53(6):1159-64.
3. Parsons MA, Harris SC, Longstaff AJ, Grainger RG. Xanthogranulomatous pyelonephritis: A pathological, clinical and aetiological analysis of 87 cases. *Diagn Histopathol.* 1983;6(3-4):203-19.
4. Chuang CK, Lai MK, Chang PL, Huang MH, Chu SH, Wu CJ, et al. Xanthogranulomatous pyelonephritis: Experience in 36 cases. *J Urol.* 1992;147(2):333-6.
5. Oosterhof GO, Delaere KP. Xanthogranulomatous pyelonephritis. A review with 2 case reports. *Urol Int.* 1986;41(3):180-6.
6. Malek RS, Elder JS. Xanthogranulomatous pyelonephritis: A critical analysis of 26 cases and of the literature. *J Urol.* 1978;119(5):589-93.
7. Nandedkar SS, Malukani K, Sakhi P. Xanthogranulomatous pyelonephritis masquerading as a tumor in an infant. *Indian J Urol.* 2014;30(3):354-6.
8. Case records of the Massachusetts General Hospital. Weekly clinicopathological exercises case 2-1995. A 71-year-old man with masses in the pancreas, presacral region, and left kidney. *N Engl J Med.* 1995;332:174-9.
9. Goodman M, Curry T, Russell T. Xanthogranulomatous pyelonephritis (XGP): A local disease with systemic manifestations. Report of 23 patients and review of the literature. *Medicine (Baltimore).* 1979;58(2):171-81.
10. Møller JC, Kristensen IB. Xanthogranulomatous pyelonephritis. A clinicopathological study with special reference to pathogenesis. *Acta Pathol Microbiol Scand A.* 1980;88:89.
11. Arrighi N, Antonelli A, Zani D, Zanotelli T, Corti S, Cunico SC, et al. Renal mass with caval thrombus as atypical presentation of xanthogranulomatous pyelonephritis. A case report and literature review. *Urologia.* 2013;80 Suppl 22:44-7.
12. Shinde S, Kandpal DK, Chowdhary SK. Focal xanthogranulomatous pyelonephritis presenting as renal tumor. *Indian J Nephrol.* 2013;23:76-7.
13. Quinn FM, Dick AC, Corbally MT, McDermott MB, Guiney EJ. Xanthogranulomatous pyelonephritis in childhood. *Arch Dis Child.* 1999;81(6):483-6.

*Funding: None; Conflict of Interest: None Stated.*

**How to cite this article:** Sharma S, Chopra N, Sugandhi N, Agarwal KC. Xanthogranulomatous pyelonephritis in a child: A rare entity. *Indian J Case Reports.* 2017;3(3):142-144.