

Fundus flavimaculatus: Clinical images and review of literature

Rajiv Kumar¹, Shilpa Singh², Anurag Narula², Manish Kumar¹

From ¹Department of Ophthalmology, Vardhman Mahavir Medical College, Safdarjung Hospital, ²Department of Ophthalmology, Attar Sain Jain Eye and General Hospital Govt. of National Capital Territory, New Delhi, India

Correspondence to: Dr. Anurag Narula. Attar Sain Jain Eye and General Hospital Govt. of National Capital Territory, New Delhi, India. E-mail: ananuragnarula@rediffmail.com. Phone: 9990770479

Received - 14 August 2017

Initial Review - 15 September 2017

Published Online - 01 January 2018

ABSTRACT

Stargardt disease (STGD) or fundus flavimaculatus is a progressive form of juvenile macular degeneration with considerable clinical and genetic heterogeneity. It may be considered a syndromal cone-rod dystrophy due to overlapping clinical features such as loss of color vision and photophobia in some patients. Here, we report a case of fundus flavimaculatus in a 32-year-old female and discuss the literature pertaining to it. Clinical data including medical history, findings on physical examination and local examination were suggestive of fundus flavimaculatus. Best-corrected visual acuity of the patient remained constant at 6/12 for 1 year with the patient being on 3-month follow-up. No particular or specific treatment is available for this fundus dystrophy and frequent follow-ups may help diagnose and manage associated choroidal neovascular membrane at the earliest. The only modality is available in the form of low vision aids for advanced disease.

Key words: *Dystrophy, Fundus flavimaculatus, Stargardt, retina*

Stargardt disease (STGD) or fundus flavimaculatus is a progressive form of juvenile macular degeneration with considerable clinical and genetic heterogeneity. It may be considered a syndromal cone-rod dystrophy due to overlapping clinical features such as loss of color vision and photophobia in some patients. The most common symptom of STGD is variable, often slow loss of central vision in both eyes. Some people also develop color blindness later in the disease. The progression of symptoms in STGD is different for each person. People with an earlier onset of disease tend to have more rapid vision loss. Vision loss may decrease slowly at first, and then worsen rapidly until it levels off.

Mutations in a gene called ABCA4 are the most common cause of STGD [1,2]. This gene makes a protein that normally clears away Vitamin A byproducts inside the photoreceptors. Cells that lack the ABCA4 protein accumulate clumps of lipofuscin, a fatty substance that forms yellowish flecks. As the clumps of lipofuscin increase in and around the macula, central vision becomes impaired. Eventually, these fatty deposits lead to the death of photoreceptors and vision becomes further impaired. Mutations in the ABCA4 gene are also associated with other retinal dystrophies including cone dystrophy, cone-rod dystrophy, and retinitis pigmentosa, a severe form of retinal degeneration. Furthermore, mutations in at least four genes are responsible for similar clinical characteristics. Due to the lack of diagnostic distinctions and the wide range of nonspecific clinical manifestations, STGD and fundus flavimaculatus are discussed here as a single entity. The incidence of this disease is about 1 in 10,000, and hence, we are reporting a case of this rare disease.

CASE REPORT

A 32-year-old female presented to us with progressive vision deterioration since last 18 months to the present status of vision being 6/12 (best corrected in both eyes). General physical examination and systemic examination was unremarkable. On examination, the best-corrected visual acuity was 6/12 in both eyes, with normal anterior segment examination. On fundus examination, the posterior pole had yellowish pisciform, round, and linear sub-retinal lipofuscin deposits which extending to equator more in the left than in the right eye. Retinal vessel calibre was normal (Figs. 1 and 2).

Fluorescein angiography revealed window in the macula where the retinal pigment epithelium (RPE) is atrophied. The flecks were hyperfluorescent. Patches of angiographically dark choroid in the posterior pole were seen (Figs. 3 and 4). Provisional diagnosis of fundus flavimaculatus was made. As no definitive treatment is available, the patient was called for regular follow-up to cater for low vision aids if required in the future and for earlier diagnosis and management of choroidal neovascular membrane at the earliest. The best-corrected visual acuity remained constant at 6/12 for 1 year with the patient being on 3-month follow-up.

DISCUSSION

STGD or fundus flavimaculatus is a group of fundus dystrophy characterized by onset of vision loss late in the first decade of life usually with rapid progression in Stargardt and much later third decade or so, or even into the fifth decade in fundus

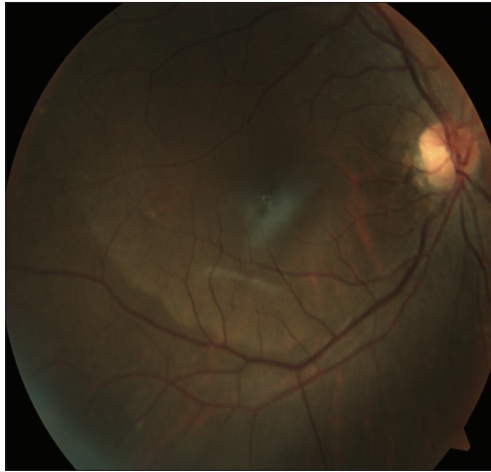


Figure 1: Fundus photo of the left eye

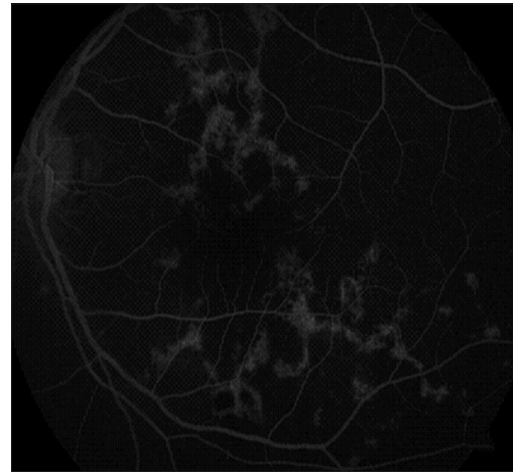


Figure 3: Fundus fluorescein angiography of the left eye

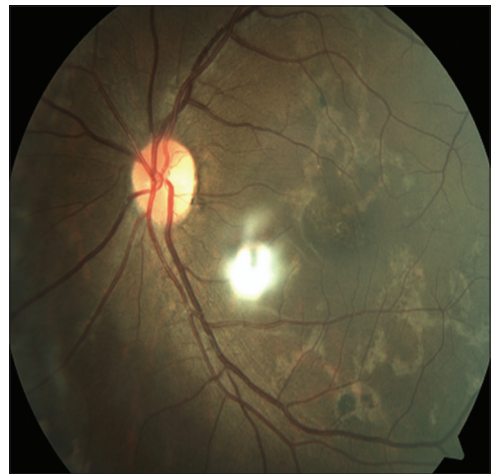

Figure 2: Fundus photo of the right eye

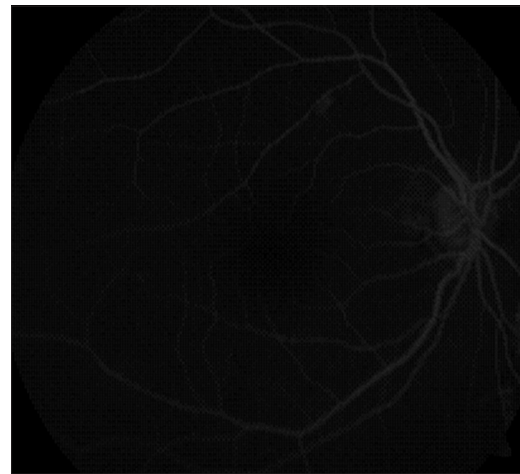


Figure 4: Fundus fluorescein angiography of the right eye

flavimaculatus [3]. There is evidence that patients with an early onset have a worse prognosis compared to those with a later onset. Nevertheless, large series of patients contain at least 23% with 20/40 or better acuity, about 20% with 20/50–20/100, and 55% have 20/200–20/400, and a small number have vision <20/400³.

Some color discrimination is lost and photophobia may be a complaint. Dark adaptation is prolonged but night blindness does not usually occur and peripheral visual fields are normal. The posterior pole characteristically has yellowish pisciform, round, and linear sub-retinal lipofuscin deposits which often extend to the equator. These may be present before clinical symptoms are present. Histopathology reveals accumulations of this material in RPE cells. Atrophy of the RPE in the same region is often visible as well, but these changes may be subtle initially. Some patients have peripheral pigment clumping which may resemble the bone spicule configuration seen in retinitis pigmentosa. However, retinal vessel caliber is normal in STGD. Extensive macular disease can be associated with temporal pallor of the optic nerve. The ERG shows reduced photonic responses with normal or near normal scotopic tracings. Fluorescein angiography often reveals more extensive disease than seen on fundoscopy. Window defects are common in the macula where the RPE is atrophied. The flecks may be hypofluorescent or hyperfluorescent. Over 50%

of patients have patches of angiographically dark choroid in the posterior pole which is thought to be secondary to transmission blockage by lipofuscin accumulations in the RPE.

This group of disorders may be caused by mutations in at least four genes. These are STGD1 (248200) caused by mutations in the ABCA4 gene located at 1p22.1, or in CNGB3 (262300) (8q21-q22) which also is mutant in achromatopsia 3, STGD3 (605512) caused by mutations in the ELOVL4 gene at 6q14, and STGD4 (603786) caused by a mutation in PROM1 on chromosome 4p. STGD4 and STGD3 diseases have been found in pedigrees consistent with autosomal dominant inheritance, but STGD1 disease seems to be inherited in an autosomal recessive pattern [3].

There is considerable diagnostic confusion regarding the clinical phenotypes and the classification of many patients. In particular, areolar macular dystrophy, retinitis pigmentosa, juvenile macular degeneration, and cone dystrophies have been reported in association with several of these mutations and reports have also associated STGD with mutations in RDS. Recent evidence suggests that gene-retinal phenotype correlations in this disorder are especially variable and inconsistent adding to the diagnostic confusion [4,5]. Low vision aids are useful for patients with advanced disease and patients are advised to avoid sunlight to prevent buildup of lipofuscin [4].

CONCLUSION

Currently, there is no treatment for STGD. Some ophthalmologists encourage people with STGD to wear dark glasses and hats when out in bright light to reduce the buildup of lipofuscin. Cigarette smoking and secondhand smoke should be avoided. We just advised a regular follow-up and an yearly checkup to the patient.

REFERENCES

1. Heath field L, Lacerda M, Nossek C, Roberts L, Ramesar RS. Stargardt disease: Towards developing a model to predict phenotype. *Eur J Hum Genet.* 2013 May 22. doi: 10.1038/ejhg.2013.92.
2. Zahid S, Jayasundera T, Rhoades W, Branham K, Khan N, Niziol LM, Musch DC, Heckenlively JR. Clinical Phenotypes and Prognostic Full-Field

- Electroretinographic Findings in Stargardt Disease. *Am J Ophthalmol.* 2012 Dec 4. [Epub ahead of print] PubMed PMID: 23219216.
3. Rotenstreich Y, Fishman GA, Anderson RJ. Visual acuity loss and clinical observations in a large series of patients with Stargardt disease. *Ophthalmology.* 2003 Jun; 110(6):1151-8.
4. Sparrow JR. Therapy for macular degeneration: insights from acne. *Proc Natl Acad Sci U S A.* 2003 Apr 15; 100(8):4353-4.
5. Weleber RG, Carr RE, Murphy WH, Sheffield VC, Stone EM. Phenotypic variation including retinitis pigmentosa, pattern dystrophy, and fundus flavimaculatus in a single family with a deletion of codon 153 or 154 of the periphery/RDS gene. *Arch Ophthalmol.* 1993 Nov; 111(11):1531-42.

Funding: None; Conflict of Interest: None Stated.

How to cite this article: Kumar R, Singh S, Narula A, Kumar M. Fundus flavimaculatus: Clinical images and review of literature. *Indian J Case Reports.* 2018;4(1):67-69.