

Clinico-radiological correlation of Primary Multifocal Osseous NHL

Jilowa S¹, Sharma S², Sharma S³ Atwal SS¹, Bhardwaj A¹, Sharma BB¹

From 1Department of Radio diagnosis and 2 Department of ENT and Head & Neck Surgery, Post Graduate Institute of Medical Education and Research & Dr. Ram Manohar Lohia hospital, New Delhi, India and 3Department Anaesthesia, SGT Medical, Gurgaon, Haryana, India.

Correspondence to: Dr Sarita Jilowa, Associate Professor, Department of Radio-diagnosis, PGIMER & Dr RML Hospital, New Delhi, Email: saritajilowa@gmail.com.

Received: 08 December 2015 Initial Review: 02 January 2015 Accepted: 13 March 2015 Published online: 23 March 2015

ABSTRACT

Multifocal skeletal involvement in primary non-Hodgkin's Lymphoma (NHL) is very rare as compared to the focal one. These findings of multifocal nature are more common in children than in adults. We present 52 years old male patient who presented with slow growing multiple tender swellings on the left side of mandible and on the medial end of right first rib. We present the clinico-radiological aspects of the disease which lead to suspicion of the NHL and later proved to be primary non-Hodgkin's Lymphoma on fine needle aspiration cytology.

Key words: FNAC, Multifocal, Non-Hodgkin's Lymphoma, Osseous

PPrimary bone lymphoma is often challenging for the radiologists to diagnose and for the physicians to manage it. Though, the secondary bone marrow involvement in non-Hodgkin's lymphoma (NHL) is quite common but the primary osseous manifestation is very rare. This can manifest as monostotic or polyostotic in its presentation. The commonest sites of involvement are long bones followed by vertebral column and pelvis. The femur is the most common long bone to be involved.

In normal healthy bone marrow, stem cells give origin to all three cell lines i.e. red blood cells, white blood cells and platelets. However in bone lymphomas, accumulation of lymphoma cells in bone marrow leads to suppression of other two cell lines which manifests as anemia and thrombocytopenia. In addition to these changes, they can also present with nodal, visceral or bony manifestations. These can exclusively be the bony swellings at various places which may be the presenting feature as it was in our case.

CASE REPORT

A 52 years old male presented with painful swellings at left side of the face and right upper chest region. These have increased in size slowly over the past two years. There is dull type of pain at the sites of the swellings. The patient reported to the dental department for the loose tooth and from there he was referred to ENT department. Swelling was not associated with fever, cough, or any bleeding manifestations. There was no history of blood transfusion, trauma or contact with tuberculosis.

On examination, patient was afebrile, conscious and well oriented with normal vital parameters. He was pale without any rash, bone tenderness or significant lymphadenopathy. There was a firm and slightly tender swelling over angle of the mandible on left side (18×12 mm) and on the medial end of right first rib (15×10 mm). Abdominal examination revealed no organomegaly. Rest of the systemic examination was also normal.

On laboratory workup, patient was anemic with hemoglobin level of 10 g/dL with raised ESR, leukocytosis and normal platelets. His sputum for AFB was negative. LDH level was 285 U/l and ALP level was 145 U/l. Plain radiograph has shown some lytic lesion with soft tissue swelling at the ramus of left side of the mandible with loss of fat planes. The patient was advised Computerized Tomography (CT) scan.

Contrast enhanced CT scan showed lytic destructive lesion with surrounding soft tissue component at the angle of mandible on left side. There was mild enhancement of

the soft tissue (Figure 1a and 1b). The bone window has also shown the destructive lesion with corresponding loose teeth (Figure 1c). CECT at the level of right first rib has shown similar lesion with the adjoining soft tissue component (Figure 2a and 2b).

The Fine Needle Aspiration Cytology (FNAC) confirmed the diagnosis as non-Hodgkin's Lymphoma. The patient has been advised the combination of radiotherapy and chemotherapy with subsequent follow up.

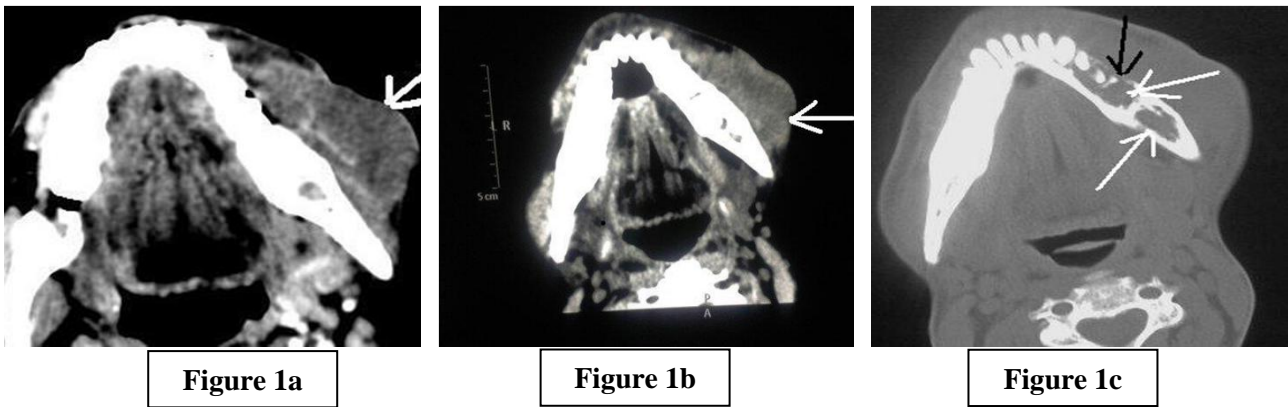


Figure 1: Contrast enhanced CT scan axial section of mandibular region. Figure 1a and 1b - soft tissue swelling in soft tissue window shows the underlying pathology of heterogeneous density with mild enhancement on left side (white arrows). Figure 1c - Bone window shows lytic destructive lesion (white arrows) and loosening of corresponding teeth (black arrow).

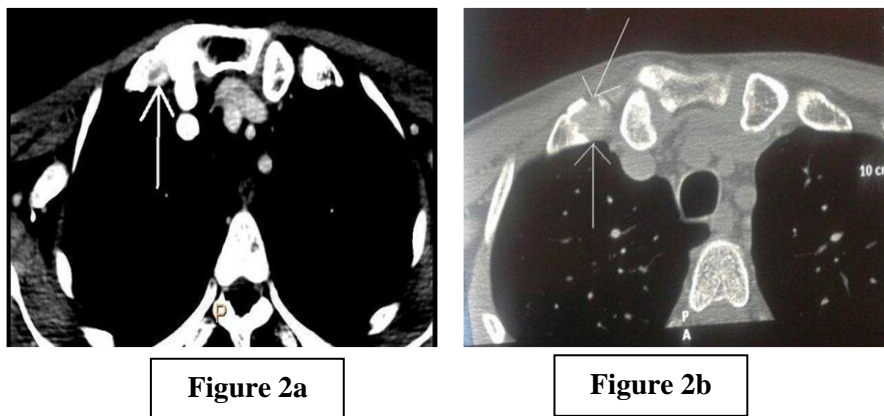


Figure 2: Contrast enhanced CT scan axial section at the level of right first rib adjoining sterno-clavicular joint. Figure 2a - Mediastinal window shows destruction of the anterior end of the first rib of the right side (white arrow) with the soft tissue involvement. Figure 2b - Bone window of the same region showing lytic lesion with destruction (white arrows).

DISCUSSION

Most of the primary bone lymphomas are non-Hodgkin Lymphomas (NHL) which further comes in subtype of Diffuse Large B-cell lymphomas (DLBCL). Primary lymphomas of bone (PLB) constitute 3% of all malignant bone tumors and predominantly seen in male in 4th and 5th decade [1]. Though, the exact etiology is not known but the underlying viral infection is considered to be the most common factor. These can have different types of progression and grading and response to treatment can vary accordingly.

Malignant lymphomas constitute 10% of the malignancies in pediatric age group where skeletal involvement is uncommon. Ivins and Dahlin introduced the term primary bone lymphoma first in 1963. The osseous involvement varies from 6.8% to 13.6% in different series. Multifocal osseous involvement is seen more commonly in children (47 – 64 %) than in adults [2]. The adjacent soft tissue swellings is seen with most (37.5%) of these lesions [3,4]. WHO has categorized lymphomas in the following four groups on the basis of osseous involvement– 1) Single primary bone site without regional nodes 2) Multiple bone sites without any visceral involvement 3) Bone sites with multiple visceral or nodes involvement and 4) Soft tissue lymphoma with proved bone involvement [5]. Our case falls in group two as there was no visceral involvement.

Plain radiography and cross sectional imaging alone cannot diagnose the entity and the aspiration cytology is required. CT scan reveals features of lytic lesion (74%) with soft tissue mass (80-100 %) in majority of the cases [6]. These can resemble with other types of similar entities like osteomyelitis and malignant Hodgkin's lymphoma because there is no internal production of the matrix. The confirmation by histopathological examination is essential for its differentiation. The management of non-Hodgkin's bone lymphoma varies from case to case but the combination of radiotherapy and chemotherapy is required in most of the cases. The treatment poses the problem as the etiology of these tumors is not definite.

CONCLUSION

Multifocal skeletal involvement by NHL in adults is rare and can be misdiagnosed as other inflammatory or malignant conditions. Radiological examination by CT scan and histopathological examination play an important role in evaluation of these cases.

REFERENCES

1. Power DG, McVey GP, Korpanty G, Treacy A, Dervan P, O'keane C, et al. Primary bone lymphoma single institution case series. *Ir J Med Sci.* 2008;177(3):247-51.
2. Iotzbecker MP, Kersun LS, Choi JK, Wills BP, Schaffer AA, Dormans JP. Primary non-Hodgkin's lymphoma of bone in children. *J Bone Joint Surg Am.* 2006;88:583-94.
3. Zinzani PL, Carrillo G, Ascani S, Barbieri E, Tani M, Paulli M, et al. Primary bone lymphoma: experience with 52 patients. *Haematologica.* 2003;88:280-5.
4. Beal K, Allen L, Yahalom J. Primary bone lymphoma: treatment results and prognostic factors with long-term follow-up of 82 patients. *Cancer.* 2006;106:2652-6.
5. Swerdlow SH, Campo E, Harris NL, Jaffe ES, Pileri SA, Stein H, et al, eds. WHO Classification of Tumours of Haematopoietic and Lymphoid Tissues. 4th ed. Geneva, Switzerland: IARC Press; 2008.
6. Stein ME, Kuten A, Gez E, Rosenblatt KE, Drumea K, Ben-Shachar M, et al. Primary lymphoma of bone - a retrospective study; Experience at the Northern Israel Oncology Centre (1979-2000). *Oncology.* 2003;64(4):322-7.

How to cite this article: Jilowa S, Sharma S, Sharma S, Atwal SS, Bhardwaj A, Sharma BB. Clinico-radiological correlation of Primary Multifocal Osseous NHL. *Indian J Case Reports.* 2015;1(1):28-30.

Conflict of interest: None stated, Funding: Nil
