

## Management of Community Acquired Respiratory Tract Infections with Co-morbidities

Santhalingam Balamurugan

From Department of Pulmonary & Critical Care Medicine, Chest Research Institute, Rakshith Hospital, Chennai, India.

**Correspondence to:** Dr. Santhalingam Balamurugan, Department of Pulmonary & Critical Care Medicine, Chest Research Institute, Rakshith Hospital, Valasaravakkam, Chennai India – 600087. Email: [dr.s.bala@gmail.com](mailto:dr.s.bala@gmail.com)

Received: 03 January 2015 Initial Review: 20 February 2015 Accepted: 21 March 2015 Published Online: 30 March 2015

### ABSTRACT

Community-acquired respiratory tract infections are one of the commonest infections seen in the clinical practice and an important cause of mortality and morbidity, especially in patients with immune-compromised states. Two cases of antibiotic resistant community-acquired lower respiratory tract infections in a 42-year-old male and a 68-year-old male are reported. Both had presented with lower respiratory tract symptoms, previously treated with antibiotics. The patients were immune-compromised and suffered from conditions such as Diabetes and COPD. Along with this, they had an infection caused by resistant bacteria. The clinical history, investigations and the appropriate line of treatment selected in order to resolve complications in the present cases are detailed here.

*Keywords: Antibiotic, Community, Co-morbidities, Diabetes, Respiratory, Resistance*

Today, antibiotic resistance has become a serious public health problem with economic and social implications, including higher rates of hospitalization, longer hospital stay and increase in the cost of treatment. In our country, the bacterial disease burden is the highest, with infections such as pneumonia leading to 410,000 deaths annually [1]. In both inpatients and outpatients, the most common pathogens associated with community-acquired pneumonia (CAP) include *Streptococcus pneumoniae*, *Haemophilus influenzae*; group A streptococci and *Moraxella catarrhalis* [2]. They are known to produce different types of beta-lactamases that confer drug resistance.

A collaborative study from eight Asian countries, including India, has revealed that 35.1% of the total resistance is to *S. pneumoniae* [3]. There are similar other reports showing multidrug resistance to *H. influenzae*, ranging from 24 to 36.6%; for *M. catarrhalis*, it is at 86.2

to 96.8%. [4]. Increase in the rates of resistance has contributed to an increase in patient mortality. Many of these deaths also occur because the patients cannot afford the cost of healthcare facilities and do not have access to life saving medicines when they are needed most [5]. The two cases presented here are examples of situations in which the patient doesn't want to get hospitalized because of his economic status but is suffering from multiple disorders along with infection that was caused by a resistant bacterium.

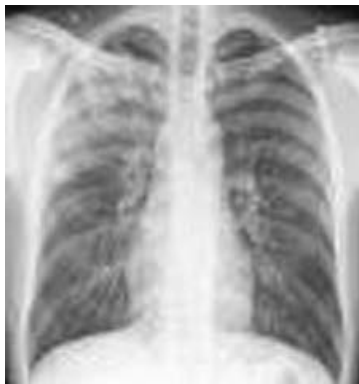### CASE REPORTS

#### Case 1

A 42-year-old male had presented with complaints of cough with yellowish expectoration of sputum for the past one week along with high grade intermittent fever. Patient belonged to a middle class working family. There was

history of diabetes mellitus (type II) for the past 4 years and for which he was taking on oral hypoglycemic drugs (glimiperide and metformin). He was a regular smoker with a family h/o coronary artery disease). There was also a history of allergy to macrolides. He was treated by a local physician with oral levofloxacin (500mg/day for 5 days) without much relief. So, he approached to a pulmonary physician who advised a chest X-ray and sputum examination.

On examination, his vitals were within normal limits (pulse rate - 95/min, blood pressure - 132/86 mmHg and respiratory rate - 25/min, SpO<sub>2</sub> - 90% on room air). There was no pallor, icterus, clubbing, edema or lymphadenopathy. Respiratory system examination showed rales in right mammary and axillary areas. Rest of systemic examination revealed no significant abnormality. His fasting blood sugar was 121 mg% and post-prandial sugar was 179 mg%, HbA1c was 8.1%. His total leukocyte counts were 12,300 cells/mm<sup>3</sup> (82% were polymorphs) and normal platelet counts. Chest X-ray was suggestive of right upper lobe pneumonia (Fig 1).



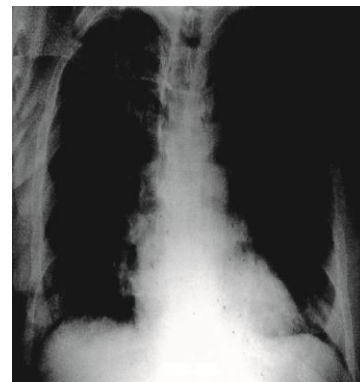
**Figure 1 - Chest X-ray suggestive of Right Upper Lobe Pneumonia**

The sputum had a heavy growth of *Streptococcus*, which was resistant to most antibiotics, including amoxicillin, levofloxacin, ciprofloxacin, ofloxacin and cephalexin. It was susceptible only to carbapenems and third-generation cephalosporins. As patient was not ready for admission so he was started with oral penem (Faropenem 200 mg thrice a day) along with cough expectorants and bronchodilators. His symptoms improved after 5 days of therapy with decreased intensity of cough and fever both.

## Case 2

A 68-year-old male with moderate chronic obstructive pulmonary disease (COPD) presented with increased sputum volume and purulence for the past 6 days associated with more shortness of breath (mMRC Grade II). He also complained of lethargy and feverishness. He was a hypertensive and diabetic, being on oral hypoglycemic agents (OHAs) for the past 2 years. He had a smoking history of 20 pack-years, which he had quit on the physician's advice 5 years back. He had a history of contact with pulmonary tuberculosis in the household; though, he had no history of taking anti-tubercular drugs for himself. The patient had three exacerbations of shortness of breath in the past 2 months, which was treated with oral antibiotics comprising of co-amoxycylav, cefuroxime and gemifloxacin.

On examination, he was afebrile with heart rate of 78/min and respiratory rate of 28/min; however, SPO<sub>2</sub> at room air was 92%. Blood pressure was 160/90 mmHg, there was no dependent edema. Examination of the respiratory system revealed prolonged expiration with polyphonic rhonchi. A clinical diagnosis of acute exacerbations of COPD (AE-COPD) was made. Rest of the systemic examination was normal.



**Figure 2 - Chest X-ray showing a hyper lucent lung fields**

On laboratory investigations, his total leukocyte count was 10,000/mm<sup>3</sup> with neutrophilia (80% neutrophils), and elevated CRP levels (70 mg/l) and serum creatinine was 1.02 mg%. Sputum examination by Gram's staining and culture was non-contributory and it grew only commensal organisms. Chest X-ray showed no evidence of

consolidation, but showed a hyperlucent lung (Fig 2). His fasting blood sugar was 130 mg/dl and random blood sugar was 168 mg/dl with HbA1c of 7.5%. Arterial Blood Gas analysis showed pH - 7.36, PaO<sub>2</sub> - 70 mmHg, and PaCO<sub>2</sub> - 50 mmHg at room air.

Taking into account the history of three exacerbations in past two months with worsening of symptoms; the patient was put on inhaled bronchodilators with regular inhaled corticosteroids. The inhalation technique was rechecked. Oral corticosteroids were started at 1 mg/kg body weight for 2 weeks along with a broad spectrum antibiotic which was not prescribed earlier. He was prescribed faropenem 200 mg thrice daily for 7 days. Good diabetic control along with a diet, OHAs and anti-hypertensives was suggested. A revisit was scheduled after 7 days and the patient was found to be much better, with stable vitals and diminished breathlessness.

## DISCUSSION

Antibiotic resistance has become a serious public health concern with economic and social implication throughout the world. Drugs used clinically in the empirical treatment of community-acquired respiratory tract infections currently include beta-lactams, macrolides and respiratory quinolones [6]. But, growing resistance rates to these antibiotics had reduced the therapeutic options for the treatment of intractable infections. [7]

These two cases demonstrated the management of patients with CAP and AE-COPD with various co-morbidities. In case 1, the patient's pre-existing conditions or "co-morbidities" such as diabetes (HbA1C - 8.1%) and chronic smoking aggravated his condition and increase the risk of serious infections [8]. The patient's sputum had grown "Streptococcus", resistant to most of the drugs (fluroquinolones and beta-lactams). In view of the co-morbid and drug resistance of the organism, treatment was started with oral faropenem for 1 week as he did not want to get hospitalized. By end of the second day, he was symptomatically better and by end of the fifth day, he was completely asymptomatic.

The clinical efficacy of faropenem is previously studied in certain trials on upper and lower respiratory tract infections, which attest its potential. Though, the trials are limited; current usage is based on *in vitro*

assessments and clinical expertise. Currently faropenem is registered for use only in Japan and India, it is not US FDA approved [9] [10].

In case 2, culture report was indecisive; however, patient was apprised of severity and was advised hospitalization but he declined hospitalization and opted for home care. Taking into account the history of three exacerbations in past two months with worsening of symptoms, patient was put on broad spectrum oral antibiotic faropenem. It's a recognized fact that evaluation of bacterial infection in exacerbation is challenging, as airways of COPD patients are usually colonized by *H. influenzae*, *S.pneumoniae*, and *M. catarrhalis*. However, bacteria are the primary cause of exacerbation; and they may also act as a secondary invader after acute viral or mycoplasma infections, hence the therapeutic options for management of AE-COPD includes antibiotics along with corticosteroids, inhaled bronchodilators and oxygen therapy [6, 11].

Patients with co-morbidities are at increased risk of respiratory tract infections. Such cases are routinely treated either with a fluroquinolones or beta lactam plus macrolides, but the increasing resistance trends have made the choice of antibiotic difficult over the period of time. The antimicrobial class of penems are said to have the potential to address most of the relevant resistance issues associated with beta-lactam antibiotics. They have a very good intrinsic stability against hydrolytic attack by many beta-lactamases, including ESBL and AmpC enzymes [12, 13].

Being a new molecule, faropenem could help in tackling the resistance issue at present, but it should be cautiously used, considering the severity parameters. This molecule has a good *in-vitro* and *in-vivo* efficacy as reported in few articles, but more randomized trials are warranted in the Indian populations.

## CONCLUSION

Current cases are the examples of infections caused by resistant bacteria in patients with various co-morbidities, where the first line of treatment with antibiotics had failed and patients were prescribed an oral penem. However, it should be strictly reserved as a second line treatment only for resistant cases based on the susceptibility outcomes.

**Acknowledgement**

Medical writing support for the preparation of this article was provided by Ms. Gurmeet Kaur, Medical Services Division of Cipla Ltd

**REFERENCES**

1. Ganguly NK, Arora NK, Chandy SJ, Fairuze MN, Gill JP, Gupta U, et al. Rationalizing antibiotic use to limit antibiotic resistance in India. *Indian J Med Res.* 2011;134:281–94.
2. Ramirez JA, Anzueto AR. Changing needs of community-acquired pneumonia. *J Antimicrob Chemother.* 2011;66 (Suppl 3):iii3–9.
3. Song JH, Oh WS, Kang CI, Chung DR, Peck KR, Ko KS, et al. Epidemiology and clinical outcomes of community-acquired pneumonia in adult patients in Asian countries: a prospective study by the Asian network for surveillance of resistant pathogens. *Int J Antimicrob Agents.* 2008; 31(2):107–14.
4. Holzman D. Community-Acquired Pneumonia Drug Resistance Patterns Prove Puzzling. *ASM News.* 2004;70 (12):Y 571–74.
5. Maragakis LL, Perencevich EN, Cosgrove SE. Clinical and economic burden of antimicrobial resistance. *Expert Rev Anti Infect Ther.* 2008;6(5):751–63.
6. Woodhead M, Blasi F, Ewig S, Garau J, Huchon G, Ieven M, et al. Guidelines for the management of adult lower respiratory tract infections--full version. *Clin Microbiol Infect.* 2011;17(Suppl. 6):E1–E59.
7. Kumar SG, Adithan C, Harish BN, Sujatha S, Roy G, Malini A. Antimicrobial resistance in India: A review. *J Nat Sci Biol Med.* 2013;4(2):286–91.
8. Ljubic S, Balachandran A, Renar IP, Barada A, Metelko Z. Pulmonary Infection in Diabetes Mellitus. *Diabetologia Croatica.* 2004;33–4.
9. Schurek KN, Wiebe R, Karlowsky JA, Rubinstein E, Hoban DJ, Zhanel GG. Faropenem: review of a new oral penem. *Expert Rev Anti Infect Ther.* 2007; 5(2):185–98.
10. Kanwar MS. Efficacy and tolerability of faropenem 200 milligram tablets t.i.d in the community acquired pneumonia (CAP). *The Ind. Pract.* 2007; 60(4):225–231.
11. Barnes PN, Drazen JM, Rennard SI, Thomson NC. Basic Mechanisms and Clinical Management. In *Asthma and COPD.* 2<sup>nd</sup> ed. Elsevier. 2009. p 575.
12. Dalhoff A, Janjic N, Echols R. Redefining penems. *Biochem Pharmacol.* 2006;30;71(7):1085–95.
13. Schurek KN, Wiebe R, Karlowsky JA, Rubinstein E, Hoban DJ, Zhanel GG. Faropenem: review of a new oral penem. *Expert Rev Anti Infect Ther.* 2007;5:185–98.

---

**How to cite this article:** Balamurugan S. Management of Community Acquired Respiratory Tract Infections with Co-morbidities. *Indian J Case Reports.* 2015;1(1):24-27.

*Conflict of interest: None stated, Funding: Nil*

---