

## Mayer-Rokitansky-Kuster-Hauser Type I Syndrome - A Case Report

Sharma BB<sup>1</sup>, Sharma S<sup>2</sup>, Singh Y<sup>1</sup>, Balesa J<sup>1</sup>

From 1Department of Radio diagnosis, Post Graduate Institute of Medical Education and Research & Dr. Ram Manohar Lohia hospital, New Delhi, India and 2Department Pediatrics, Army College of Medical Sciences & Base Hospital, New Delhi, India

**Correspondence to:** Dr Bharat Bhushan Sharma, B-32, Nivedita Kunj, Sector 10, R K Puram, New Delhi – 110022. E mail: [bbhushan986@gmail.com](mailto:bbhushan986@gmail.com). Tel No +91 11 26182700

Received: 14 January 2015 Initial Review: 20 February 2015 Accepted: 11 March 2015 Published online: 21 March 2015

### ABSTRACT

Mayer-Rokitansky-Kuster-Hauser (MRKH) Syndrome is not uncommon as this is a part of the Mullerian agenesis. This is usually diagnosed during adolescent period when signs and symptoms of the ongoing changes in female body type are delayed. We present 17 years old adolescent female who presented with primary amenorrhoea as the normal menstruation did not start at puberty. She was diagnosed as MRKH Type I Syndrome on the basis of radiological investigations.

**Key words:** MRKH Syndrome, Mullerian agenesis, amenorrhoea, MRI

The Mayer-Rokitansky-Küster-Hauser Syndrome is known by congenital aplasia of the uterus as well as the upper two-thirds of the vagina in women who have normal development of secondary sexual characteristics and normal 46 XX karyotyping. It was considered as sporadic earlier but now the theory of being autosomal dominant has been incorporated. The incidence is 1 out of 4500 women. Type I MRKH syndrome is usually isolated type while type II is associated with renal, vertebral, and, to a lesser extent, auditory and cardiac defects. The young females present with normal female type body with the normal functioning ovaries. The external genitalia do not show any abnormality as per the anatomical lay out. The patients usually have normal thelarche and adrenarche. This requires complete work up as it may overlap other similar types of syndromes.

### CASE REPORT

A 17 years old female, a child of army personnel, reported to the Adolescent OPD for not having started menstruation by the age of 16 years; though, all other puberty features were there as per the age. The external genitalia were

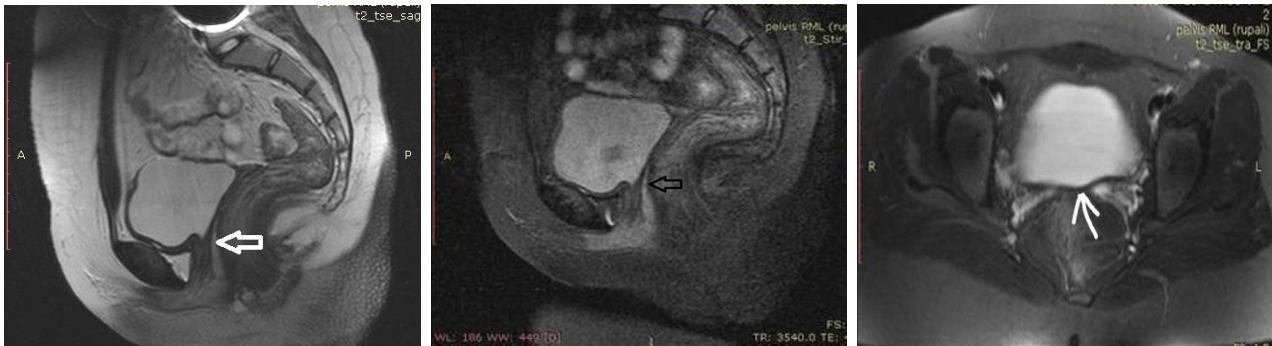normal in appearance. There was no past medical or family history related to the present entity. There was nothing abnormal related to the pre or perinatal history. There was no defect in external appearance of the perineum.

In view of primary amenorrhoea, Ultrasonography (US) examination of the whole abdomen was advised. There was non-visualisation of the uterus along with the partial absence of the upper part of the vagina. Bilateral ovaries were normal in appearance. There was no abnormality in the kidneys, liver, spleen and pancreas. Routine blood investigations were normal. The Luteinising hormone (LH) and Follicular Stimulating hormone (FSH) levels were normal. The testosterone level was as per the female body type. The karyotyping was normal (46 XX chromosomes). So, the child was subjected to MRI study.

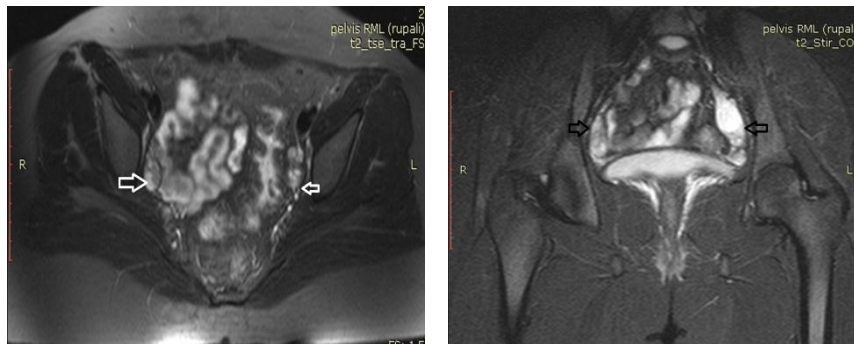
MR examination has shown the absence of uterus along with uterine cervix. The upper two thirds of the vagina was also absent with underdeveloped lower one third of it (Figures 1a, 1b and 2). Both the ovaries were normal in size, shape, and outline with normal maturing

follicles (Figure 3). No other abnormality was noticed in the pelvis. Counselling of the patient and parents were planned for further course of action because of the

underlying psychological stress. The option for vaginoplasty and its benefits were explained to the patient.



**Figures 1-2 – Fig 1(a): MR T2W sagittal image shows absent of uterus and upper 2/3 of vagina (white broad arrow), Fig 1(b): MR STIR sagittal image show absence of uterus (black broad arrow), Fig 2: MR T2W axial fat suppressed image shows absence of uterus (white arrow)**



**Figure 3 - 3a: MR T2W axial fat suppressed image shows both ovaries of normal size and in normal location (white arrows). 3b: MR STIR coronal image shows both ovaries of normal morphology. Dominant follicle is seen in left ovary (black wide arrows).**

## DISCUSSION

MRKH syndrome has got great clinical importance because of the various issues related to the underlying developmental abnormalities. The various anomalies that develop within the mullerian duct system continue to baffle the medical professionals dealing with adolescent females. The mullerian duct plays a crucial role in the female reproductive system and it differentiates to form the fallopian tubes, uterus, superior vagina as well as superior cervix. Mullerian ducts (paramesonephric ducts) are paired ducts of the embryo that run down lateral side of the urogenital ridge and terminate at the mullerian eminence in the primitive urogenital sinus. In the female they develop to form the fallopian tubes, uterus, cervix and upper two-third of vagina. In the male these are lost.

The female reproductive system is composed of Urogenital sinus and Mullerian ducts. Both these segments are conjoined at the mullerian tubercle. Contribution of Mullerian ducts to sex-based differences in the reproductive organs is based on the presence of Mullerian Inhibiting Factor (MIF) or anti-mullerian hormone. Any disturbance in the production of this hormone will lead to plethora of developmental anomalies, as has been observed in this case. Many types of anomalies can occur when the system is disrupted ranging from uterine and vaginal agenesis to the duplication of uterus and vagina.

MRKH syndrome consists of vaginal aplasia with other mullerian duct abnormalities [1]. Type 1 MRKH syndrome is characterised by an isolated absence of proximal two-third of the vagina whereas Type II is associated with other malformations [2]. Mullerian agenesis is a congenital

malformation characterised by a failure of the Mullerian duct development leading to various malformations. This is the third most common cause of amenorrhoea after pregnancy and gonadal failure [3]. An individual with this condition is hormonally normal i.e., they will enter puberty with development of secondary sexual characteristics (thelarche and adrenarche). Ovaries are normal and ovulation normally occurs. Our present case belongs to this category. The role of imaging like US and MRI plays a great role in delineating the underlying anatomical details.

The abdomino-pelvic MRI also highlights the relationship of the reproductive system with the adjacent organs [4,5]. The management depends upon the type and underlying abnormality. Non surgical option in some cases is Franck's technique or perineal dilatation. The surgical techniques include various options like McIndoe technique, William vaginoplasty, Rotational flap procedure, Intestinal neovagina and Vacchiotti technique. The procedure is selected as per the suitability of the underlying anomaly. It is possible for these females to have genetic offspring by in vitro fertilisation and surrogacy. The treatment by uterine transplantation is still in its infancy [6].

## CONCLUSION

The young normal looking adolescent female with normal secondary sexual characters does not rule out the underlying abnormality in the reproductive system.

The suspicion comes when there is complaint of not having started normal menstruation as per the age. Abdomino-pelvis MRI played a pivotal role in highlighting the exact anatomical details to decide about the management.

## REFERENCES

1. Sultan C, Biason-Lauber A, Philibert P, Mayer-Rokitansky-Kauser-Hauser syndrome: recent clinical and genetic findings. *Gynecol Endocrinol.* 2009;25(1):8-11.
2. Morcel K, Guerrier D, Wartin T, Pellerin I, Leveque J. The MRKH syndrome: clinical description and genetics. *J Gynecol Obstet Bio Reprod.* 2008;37(6):539-46.
3. Morcel K, Camborieux L, Guerrier D: Mayer-Rokitansky-Kuster-Hauser syndrome. *Orphanet J Rare Dis.* 2007;2(13):13.
4. Carrington BM, Hricak H, Nuruddin RN, Secaf E, Laros RK Jr., Hill EC. Mullerian duct anomalies: MR imaging evaluation. *Radiology.* 1990;176:715-720.
5. Troiano RN, McCarthy SM. Mullerian duct anomalies: imaging and clinical issues. *Radiology.* 2004;233:19-34.
6. Parikh R, Nakum K, Kadikar G, Gokhle A. Mullerian anomalies: A cause of primary amenorrhea. *International J Reproduction Contraception Obstet Gynaecol.* 2013;2(3):393.

---

**How to cite this article:** Sharma BB, Sharma S, Singh Y, Balesa J. Mayer-Rokitansky-Kuster-Hauser Type I Syndrome – A Case Report. *Indian J Case Reports.* 2015;1(1):8-10.

---

*Conflict of interest: None stated, Funding: Nil*

---