

Challenges in diagnosis and management of snake bites in resource poor settings: A case report of suspected Russell's viper envenomation

Thomas Lamb

From, Khristiya Seva Niketan, Sarenga, Bankura District, West Bengal, India

Correspondence to: Dr. Thomas Lamb MRCP, Honorary clinical fellow- University of Edinburgh, 6 Lymington Road, Wallasey, CH44 3EF, UK. Email -Mda04tl@gmail.com.

Received: 15 November 2015 Initial Review: 12 December 2015 Accepted: 20 December 2015 Published Online: 27 December 2015

ABSTRACT

Snake bite is a common and neglected problem resulting in a large global mortality and morbidity per year. In India alone, an estimated 45,900 deaths occur per annum. The outlined case of suspected Russell's Viper (*Daboia russelii*) envenomation occurred in rural West Bengal. The case was misdiagnosed on two occasions resulting in a substantial delay in antivenom therapy. The resultant delay contributed to a significant morbidity and prolonged hospital admission. The case report illustrates some practical difficulties faced by clinicians pertaining to diagnosis, complications and resource limitations. These areas are discussed with a view to improving awareness and management. Simple practical tools are included to assist a clinician faced with snake bites in South Asia.

Keywords: Snake-bite, Russell's Viper, diagnostic delay, complications

Snake bite is a common condition of great consequence to the rural tropics resulting in an estimated 125,000 deaths per annum with many more permanently disabled [1]. India has approximately 60 species of venomous snakes and is widely acknowledged as having the greatest number of snake bite fatalities per year with an estimated 45,900 deaths per annum [2-4]. Traditionally, the majority of snake related mortality and morbidity in India was thought to be related to the 'big 4' which refers to Russell's viper (*Daboia russelii*), common krait (*Bungarus caeruleus*), Indian cobra (*Naja naja*) and saw-scaled viper (*Echis carinatus*). However, there is now clear evidence that other snakes such as the hump nosed pit-viper (*Hypnale hypnale*) and Levantine viper (*Macrovipera lebetina*) are also responsible for medically significant envenomations in India [5,6]. Snake venom has an incredibly complex and varied composition. The venom from one bite can contain greater than 100 different toxic and non-toxic proteins and peptides. These proteins and peptides can result in a variety of pathophysiological processes [7].

Snake bite diagnosis can be challenging, particularly when the injury is unwitnessed or occurring at night. The following case outlines many of the difficulties faced by clinicians when dealing with snake bites in a resource poor setting.

CASE REPORT

A 45 year lady presented to a rural NGO hospital in West Bengal, India complaining of a painful and swollen left foot. She stated that, one hour previously, she had stepped on a thorn whilst collecting leaves in a nearby teak forest. The attending physician described the leg as having a 'toxic appearance' and commenced analgesia and antibiotics before discharging the patient.

Three hours later, she re-presented to the same hospital complaining of severe epigastric pain and vomiting. She was found to be haemodynamically stable with localized epigastric guarding. She was admitted and managed conservatively.

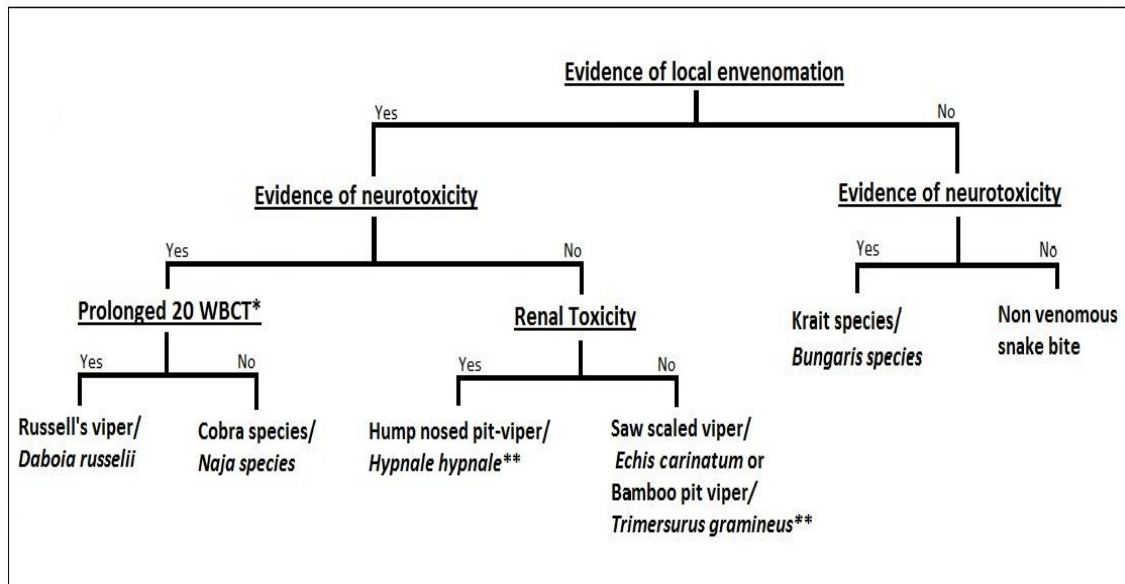


Figure 1: A guide to Indian snake species identification using clinical syndrome (* 20 minute whole blood clotting test , ** Envenomation by *Hypnale hypnale*, *Echis Carinatum* and *Trimersurus gramineus* can cause consumption coagulopathy). Please note that venomous bites of a particular species may not demonstrate all clinical manifestations.

Two hours after her admission, she was reviewed by a third doctor on a routine evening ward round. Neurological examination demonstrated bilateral ptosis after 30 seconds of upward gaze. Blood was taken for a 20 minute whole blood clotting test and the patient was placed under close observation. Her blood failed to clot after 20 minutes and over the following hour she developed a unilateral 6th cranial nerve palsy and altered conscious level (Glasgow Coma Score: 13). Using a syndromic approach (figure 1), a presumed diagnosis of Russell's viper (*Daboia russelii*) envenomation was made and eight vials of antivenom were administered. This was repeated after a further six hours. Her coagulopathy reversed and focal neurological signs gradually improved over the subsequent 12 hours.

The following day the patient was oliguric and hypotensive. Serum biochemistry revealed marked renal impairment. Her left leg was diffusely swollen but neurovascularly intact. She received aggressive fluid replacement and inotropic support on the medical ward as no intensive care facilities were available.

Her condition remained critical for a further 48 hours with difficulties balancing her fluid requirements in the presence of hypotension and pulmonary oedema. Her renal function plateaued on day six (eGFR 6) before gradually improvement. Her clinical condition finally stabilized and

inotropic support was weaned. She was discharged six days later.

DISCUSSION

Snake bite is predominantly a condition of the rural tropics with 97% of snake bite deaths in India occurring in rural areas [4]. Patients frequently present to snake charmers and quack doctors before seeking care from qualified medical professionals. In Bangladesh, only 3% of snake bite victims present directly to a registered physician [8]. Rural medical facilities often face personnel shortages with difficulties attracting postgraduate trained staff. Hospitals can lack suitable equipment necessary to implement life saving interventions such as invasive ventilation, haemodialysis and inotropic support. Additionally electricity supply, necessary for the storage of liquid antivenom, can be unreliable.

The case illustrates that the diagnosis of snake bite can be challenging and in some circumstances, may go unrecognized. This supports the theory that traditional methods of estimating incidence using medical records and verbal autopsies may underestimate snake bite disease burden. In cases of unwitnessed snake bite, the diagnosis relies on a large degree of clinical suspicion. Knowledge of the local snake fauna can facilitate a syndromic

approach to identify the responsible species (figure 1). Species recognition is not essential and should not delay antivenom administration in the presence of clinical or laboratory markers meeting the indication criteria (table 1) [9]. In the outlined case, recognition that abdominal pain is a common and early symptom of Russell's viper envenomation may well have resulted in earlier detection and a reduction in morbidity [10].

Table 1: Indications for antivenom treatment

1. Neurotoxicity (such as ophthalmoplegia, ptosis, neck muscle weakness)
2. Coagulopathy demonstrated by spontaneous bleeding or abnormal 20 minute whole blood clotting test
3. Acute kidney injury
4. Cardiac toxicity such as arrhythmia
5. Haemoglobinuria/myoglobinuria
6. Severe local envenomation with necrosis or oedema affecting > half of bitten limb

There have been some efforts to improve the understanding of current snake bite management amongst the public and medical community. An initiative in Bangladesh has made a concerted effort to promote community awareness, first aid and rapid transfer to tertiary level hospitals. These projects specifically target and engage village elders and allied health professions. This has been implemented alongside a formal government funded 'Learners guide' for physicians. More than 1000 doctors have now undergone this training and recruitment is ongoing [11].

In future, a low cost, bedside test may allow identification of systemic envenomation. Although not presently available, in vivo studies have shown good correlation between serum phospholipase A2 enzyme activity and systemic envenomation [12]. Whilst this would not replace current methodologies of snake bite diagnosis, it may be of use where diagnosis is unclear, particularly in cases of neurotoxic envenomation.

CONCLUSION

Timely administration of antivenom is a life saving intervention in tropical snake bite. Training of doctors in snake bite prone areas will empower clinicians to diagnose and treat effectively. Public health initiatives and community engagement is required for effective first aid techniques and speedy transfer to medical services.

REFERENCES

1. Chippaux JP. Snake-bites: appraisal of the global situation. Bull World Health Organ. 1998;76(5):515-24
2. Whitaker R, Captain A. Snakes of India: The Field Guide, 1st ed. Chennai: Draco Books; 2004.
3. Kasturiratne A, Wickremasinghe AR, de Silva N, Gunawardena NK, Pathmeswaran A, Premaratna R, et al. The Global Burden of Snakebite: A Literature Analysis and Modelling Based on Regional Estimates of Envenoming and Deaths. PLoS Medicine. 2008; 5(11): e218.
4. Mohapatra B, Warrell DA, Suraweera W, Bhatia P, Dhingra N, Jotkar RM, et al. Snakebite mortality in India: a nationally representative mortality survey. PLoS Negl Trop Dis. 2011; 5(4): e1018.
5. Simpson ID, Norris RL. Snakes of medical importance in India: is the concept of the 'Big 4' still relevant and useful? Wilderness Environ Med. 2007; 18(1): 2-9.
6. Sharma LR, Lal V, Simpson ID. Snakes of the medical significance in India: the first reported case of envenoming by the Levantine viper (*Macrovipera lebetina*). Wilderness Environ Med. 2008;19(3):195-8.
7. Warrell DA. Snake bite. Lancet. 2010;375(9708):77-88.
8. Rahman R, Faiz MA, Selim S, Rahman B, Basher A, Jones A et al. Annual Incidence of Snake Bite in Rural Bangladesh. PLoS Negl Trop Dis. 2010; 4(10): e860
9. Warrell DA. Guidelines for the management of snake-bites. World Health Organisation Regional Office for South-East Asia. 2010. Available from: http://apps.searo.who.int/PDS_DOCS/B4508.pdf
10. Kularatne SA, Silva A, Weerakoon K, Maduwage K, Walathara C, Paranagama R et al. Revisiting Russell's viper (*Daboia russelii*) bite in Sri Lanka: Is abdominal pain an early feature of systemic envenoming? PLoS One. 2014; 9(2): e90198.
11. Global Snakebite Initiative [Internet]. Ghose A: A summary of the problem in Bangladesh. Available from: http://www.snakebiteinitiative.org/?page_id=611
12. Maduwage K, O'Leary MA & Isbister GK. Diagnosis of snake envenomation using a simple phospholipase A2 assay. Science Reports. 2014; 4: 4827

How to cite this article: Lamb T. Challenges in diagnosis and management of snake bites in resource poor settings: A case report of suspected Russell's viper envenomation. Indian J Case Reports. 2015; 1(4): 74-76.

Conflict of interest: None stated, Funding: Nil