

## Postpartum bloody nipple discharge-rusty pipe syndrome: A case report

Ananya S Prasad<sup>1</sup>, Neena Ananthan<sup>2</sup>

From <sup>1</sup>Clinical Pharmacist, Department of Pharmacy, <sup>2</sup>Senior Consultant, Department of Obstetrics and Gynecology, Kinder Women's Hospital and Fertility Centre Cherthala, Alappuzha, Kerala, India

### ABSTRACT

In the early postpartum period, a primiparous woman who shows unilateral bloody nipple discharge ought to likely be evaluated for rusty pipe syndrome (RPS). It is rare and can be brought on by a physiological condition that mostly affects primiparous women who have enhanced ductal and alveolar vascularization as a result of lactation. Here, we report the case of a 34-year-old primigravida who presented with unilateral painless and bloody nipple discharge after delivery. Her breast examination showed no signs of infection or structural changes, and the breast ultrasound did not reveal any significant compliances. Five days after the onset of lactation, the bloody nipple discharge stopped and lactation continued on demand. Since traditional textbooks do not cover RPS, we felt that it would be appropriate to alert readers to this benign condition and to avoid unnecessary investigations.

**Key words:** Bloody nipple discharge, Postpartum period, Primiparous, Rusty pipe syndrome

Human milk is considered the gold standard for child feeding [1]. Nonetheless, a number of issues may arise during the lactation phase and jeopardize the rate of nursing. A bloody nipple discharge during pregnancy or lactation is an uncommon symptom in clinical practice that causes serious patient anxiety and necessitates medical assessment and treatment [2]. Rusty pipe syndrome (RPS) occurs due to elevated vascularization of fleetly developing alveoli that have a delicate network of capillaries. These capillaries are fluently traumatized, resulting in bleeding from the nipple [3,4].

### CASE PRESENTATION

A 34-year-old primigravida delivered a child with a birth weight of 2430 g through cesarean section at 35 weeks 4 days of gestation. The mother had a unilateral bloody nipple discharge when she started to express milk.

There were no physical examination findings of ulcers, cracks, pain, palpable millions, engorgement, or inflammation. Examination of the infant's mouth revealed no natal teeth.


A breast ultrasound revealed normal study-BI-RADS CATEGORY 1, no abnormality, such as mass, architectural distortion, thickening of skin, or macrocalcification. Cytological analysis of the milk showed singly scattered macrophages only (Fig. 1).

To prevent breast engorgement and encourage ongoing breastfeeding, the patient was instructed to pump milk from her breasts every 3 h. During hospitalization, the rusty milk's hue changed from dark brown to light brown without any medical assistance, and it eventually went away 5 days after giving birth, there is no recurrence. Informed consent was obtained from the patient for publication. Early diagnosis of this rare, self-limiting disease by obstetricians or neonatologists, followed by telling the mother that her infant would be unaffected by the small quantity of blood consumed, would be extremely beneficial in avoiding unneeded examinations and the discontinuation of exclusive breastfeeding.

### DISCUSSION

Bloody nipple discharge tends to coincide with characteristic dysfunction of the ductal system and the implicit presence of a subclinical malignancy in non-pregnant women [5]. The circumstance of blood-stained nipple discharge is rare during pregnancy, and its frequency is estimated to be roughly 0.1% [6].

Blood-stained milk may do as a result of physiological changes during late gestation and the early lactation period. One similar condition can be RPS, a tone-limiting condition that presents as effortless bloody or brown discharge in pregnant and postpartum women. Bloody nipple discharge correlates with the proliferation of the conduit epithelium. The capillary network around mammary tubes is fragile due to hormonal stimulants

Access this article online	
Received - 18 December 2024 Initial Review - 06 January 2025 Accepted - 08 March 2025	Quick Response code 
DOI: ***	

**Correspondence to:** Ananya S Prasad, Department of Pharmacy, Kinder Women's Hospital and Fertility Centre Cherthala, Alappuzha - 688539, Kerala, India. E-mail: ananyanu1423@gmail.com

© 2025 Creative Commons Attribution-NonCommercial 4.0 International License (CC BY-NC-ND 4.0).

Table 1: Summary of cases cited in the literature

Literature	Age	Weeks	Unilateral/ bilateral	Time of onset	Resolution of bleeding	Cytology
This paper	34	35 weeks +4 days	Unilateral	1 <sup>st</sup> h after delivery	5 day post natal	Singly scattered macrophages only
Thota <i>et al.</i> 2013 [4]	21	NA	Bilateral	12 h after delivery	5 day postnatal	NA
Tang <i>et al.</i> [9]	31	39	Bilateral	36 <sup>th</sup> week of pregnancy	6 day postnatal	inflammatory cells, polynuclear macrophages and epithelial cells
Katarzyna <i>et al.</i> 2022 [10]	29	40	Bilateral	Day 1 after delivery	5 day postnatal	amorphous acidophilous content, mononuclear macrophages, erythrocyte
Low <i>et al.</i> 2021 [11]	30	NA	Bilateral	1 <sup>st</sup> h after delivery	5 day post natal	NA
Kural and Sapmaz 2020 [12]	28	40	Bilateral	Day 2 after delivery	Within 72 h	NA
Kallesh <i>et al.</i> 2020 [13]	23	NA	Bilateral	1 <sup>st</sup> h after delivery	4 day post natal	NA
Mohamad <i>et al.</i> 2020 [14]	29	38	Bilateral	NA	6 day postnatal	Normal
Deboni <i>et al.</i> 2018 [3]	29	38	Bilateral	1 <sup>st</sup> h after delivery	Within 24 h	NA
Çintesun <i>et al.</i> 2017 [15]	28	33	Bilateral	1 <sup>st</sup> h after delivery	7 day post natal	Normal
Barco <i>et al.</i> 2014 [8]	26	40	Bilateral	32 <sup>nd</sup> week of pregnancy	10 day post natal	Red blood cells, histiocytes and foam cells
Silva <i>et al.</i> 2014 [16]	31	39	Bilateral	1 <sup>st</sup> h after delivery	4 day postnatal	Normal
Cizmeçi <i>et al.</i> 2013 [17]	28	40	Bilateral	Day 2 after delivery	Within 72 h	NA
Faridi <i>et al.</i> 2013 case 1 [18]	28	38	Bilateral	1 <sup>st</sup> h after delivery	7 day postnatal	NA
Faridi <i>et al.</i> 2013 case 2 [18]	27	37	Bilateral	7 month at gestation	7 day postnatal	Red blood cells
Guèye <i>et al.</i> 2013 [19]	22	40	Bilateral	26 week of gestation	4 day postnatal	normal
Virdi <i>et al.</i> 2001 [20]	26	NA	Bilateral	26 week at gestation	4 day postnatal	normal

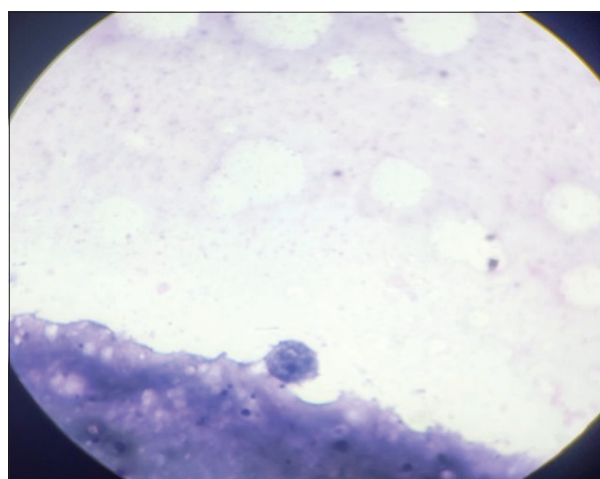


Figure 1: Cytological smear of nipple discharge showing mammary epithelial cells (Papanicolaou-stain)

(estrogen, progesterone, and oxytocin) and is fluently traumatized, performing in blood cells leaking into breast concealment [4,7,8].

To date, only 17 cases diagnosed with RPS have been reported (including one in this paper) [9]. A review of RPS cases, including clinical manifestations and auxiliary examinations, is summarized in Table 1, [3,4,8,9-20]. The abnormal discharge was bilateral in all patients except that our case was unilateral.

RPS can mimic more serious diseases, such as breast cancer. To minimize the rate of misdiagnosis, it is necessary to carefully assess and thoroughly understand the appearance of various benign and malignant breast lesions. A thorough physical examination may quickly differentiate conditions such as trauma,

broken nipple, and mastitis [9]. Wang *et al.* evaluated 142 patients with pregnancy-associated breast cancer, four of whom presented with papillary hemorrhagic discharge [21].

The first diagnosis of RPS is established by the history of the present illness and regular physical examination, followed by specific tests, similar to cytological analysis of the bloody discharge and breast ultrasonography, if necessary. The available literature offers a mixed opinion on whether obtaining a cytological smear is rigorously needed. The individual accuracy of nipple discharge fluid cytology for the detection of breast cancer is poor, while specificity and sensitivity data vary among published clinical studies. A meta-analysis from Jiwa *et al.* indicated that the sensitivity of nipple smear cytology was roughly 75% with a specificity of 87% [22]. In summary, “RPS” during gestation and lactation is an uncommon and harmless condition but can be intimidating to the mother, caregivers, and medical personnel [7].

## CONCLUSION

RPS is a self-limiting physiological condition. To properly treat this illness, prevent needless investigations, and ease the mothers’ concerns, medical and paramedical staff who work with nursing moms must be aware of this benign condition.

## REFERENCES

1. Bartick M, Hernández-Aguilar MT, Wight N, Mitchell KB, Simon L, Hanley L, *et al.* ABM clinical protocol #35: Supporting breastfeeding during maternal or child hospitalization. *Breastfeed Med* 2021;16:664-74.

2. Laffreniere R. Bloody nipple discharge during pregnancy: A rationale for conservative treatment. *J Surg Oncol* 1990;43:228-30.
3. Deboni FA, Moldenhauer M, Do-Nascimento MB. "Rusty pipe" syndrome: Benign and rare cause of bloody nipple discharge during breastfeeding - case report. *Residencia Pediatr* 2018;8:151-3.
4. Thota U, Machiraju VM, Jampana VR. Rusty pipe syndrome: A case report. *Health* 2013;5:157-8.
5. Chen L, Zhou WB, Zhao Y, Liu XA, Ding Q, Zha XM, *et al.* Bloody nipple discharge is a predictor of breast cancer risk: A meta-analysis. *Breast Cancer Res Treat* 2012;132:9-14.
6. Merlob P, Aloni R, Prager H, Mor N, Litwin A. Blood-stained maternal milk: Prevalence, characteristics and counselling. *Eur J Obstet Gynecol Reprod Biol* 1990;35:153-7.
7. Barco I, Vidal MC, Barco J, Badia A, Piqueras M, García A, *et al.* Blood-stained colostrum and human milk during pregnancy and early lactation. *J Hum Lact* 2014;30:413-5.
8. Sabate JM, Clotet M, Torrubia S, Gomez A, Guerrero R, De Las Heras P, *et al.* Radiologic evaluation of breast disorders related to pregnancy and lactation. *Radiographics* 2007;27(Suppl 1):S101-24.
9. Tang H, Zhu W, Chen J, Zhang D. Rusty pipe syndrome: A case report and review of the literature. *BMC Pregnancy Childbirth* 2022;22:770.
10. Katarzyna W, Malgorzata P, Agata WP, Wioletta M, Jan M, Katarzyna R, *et al.* Blood-stained colostrum: A rare phenomenon at an early lactation stage. *Children (Basel)* 2022;9:213.
11. Low JM, Amin Z, Ng YP. Early recognition of rusty pipe syndrome to avoid disruption of breast feeding. *Arch Dis Child Fetal Neonatal Ed* 2022;107:241.
12. Kural B, Sapmaz S. Rusty pipe syndrome and review of literature. *Breastfeed Med* 2020;15:595-7.
13. Kallesh A, Nangia S, Ambalakkuthan M, Teja R, Pal R. Rusty pipe syndrome: A benign cause of altered breast milk color in lactating mothers. *Acad J Ped Neonatol* 2020;8:555800.
14. Mohamad N, Sulaiman Z, Tengku Ismail TA, Ahmad S. Bloody nipple discharge post-delivery: A case of "rusty pipe syndrome". *Korean J Fam Med* 2021;42:339-41.
15. Çintesun E, Gül A, Akar S, Ezveci H, Çelik Ç. Rusty pipe syndrome. *Perinatal J* 2017;25:85-6.
16. Silva JR, Carvalho R, Maia C, Osório M, Barbosa M. Rusty pipe syndrome, a cause of bloody nipple discharge: Case report. *Breastfeed Med* 2014;9:411-2.
17. Cizmeci MN, Kanburoglu MK, Akelma AZ, Tatli MM. Rusty-pipe syndrome: A rare cause of change in the color of breastmilk. *Breastfeed Med* 2013;8:340-1.
18. Faridi MM, Dewan P, Batra P. Rusty pipe syndrome: Counselling a key intervention. *Breastfeed Rev* 2013;21:27-30.
19. Guèye M, Kane-Guèye SM, Mbaye M, Ndiaye-Guèye MD, Faye-Diémé ME, Diouf AA, *et al.* Rusty pipe syndrome in a 22-year-old primigravida at 26 week's gestation. *S Afr J Obstet Gynaecol* 2013;19:17-8.
20. Virdi VS, Goraya JS, Khadwal A. Rusty-pipe syndrome. *Indian Pediatr* 2001;38:931-2.
21. Wang B, Yang Y, Jiang Z, Zhao J, Mao Y, Liu J, *et al.* Clinicopathological characteristics, diagnosis, and prognosis of pregnancy-associated breast cancer. *Thorac Cancer* 2019;10:1060-8.
22. Jiwa N, Kumar S, Gandhewar R, Chauhan H, Nagarajan V, Wright C, *et al.* Diagnostic accuracy of nipple discharge fluid cytology: A meta-analysis and systematic review of the literature. *Ann Surg Oncol* 2022;29:1774-86.

*Funding: Nil; Conflicts of interest: Nil.*

**How to cite this article:** Prasad AS, Ananthan N. Postpartum bloody nipple discharge-rusty pipe syndrome: A case report. *Indian J Case Reports*. 2025; March 22 [Epub ahead of print].