

Giant Cranial Vault Frontal Haemangioma – A Case Report

Sharma BB¹, Sharma S², Sarin M¹, Jilowa S³, Kaur J³

From Department of 1Radio diagnosis, SGT Medical College, Gurgoan, 2ENT and Head & Neck and 3Radiodiagnosis, Post Graduate Institute of Medical Education and Research & Dr. Ram Manohar Lohia hospital, New Delhi, India.

Correspondence to: Dr Bharat Bhushan Sharma, C-35, First Floor, Anand Niketan, New Delhi – 110021, India. E mail: bbhushan986@gmail.com.

Received: 07 April 2016

Initial Review: 27 April 2016

Accepted: 01 May 2016

Published online: 03 May 2016

ABSTRACT

Cranial vault haemangiomas are benign vascular lesions having capillaries, venous and cavernous channels. Histopathologically, these are almost like soft tissue haemangiomas. These are slow growing tumors and very rarely bleed. Cranial vault is uncommon site for the occurrence as compared to the vertebral. Cross sectional imaging like Computerized Tomography (CT) and Magnetic Resonance Imaging (MRI) play an important role in delineation of the vault pathologies. We present a 38-years old male who presented with slow growing swelling over the frontal bone without any neurological symptoms. CT and MRI imaging clinched the diagnosis which was confirmed subsequently by histopathological examination.

Keywords: Cavernous, CT scan, Haemangioma, MRI, Neurological symptoms

Calvarial haemangioma are like common soft tissue haemangiomas with slow growing tendencies. These frequently occur at vertebral and facial locations but a few are found in calvarium. 1% cases are in multiple [1]. The outer table is affected by the lytic lesion but can affect the whole vault thickness if giant in size as in our case. These give the appearance of multiple disorganized veins or vascular spaces.

CASE REPORT

38-years old male had a slow growing swelling on the right frontal bone over two years. It was very small in the beginning but the size increased without much of the complaints. Now, he had vague pain in the head especially at the site of swelling. There was no history of seizures or trauma. On examination, the individual was of average built with unremarkable systemic examination. Locally superficial skin over the swelling was of normal coloration and there was no break in the surface. All the blood and biochemical parameters were within normal limits.

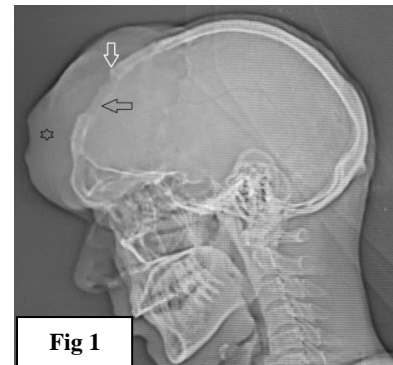


Figure 1 - Skull X-ray lateral view showing soft tissue swelling at frontoparietal region (black star) and causing destruction of the underlying bone (horizontal black arrow). Transition zone is well demarcated (vertical white arrow).

Plain X-ray has shown the frontal soft tissue mass with destruction of the underlying table (**Figure 1**). Patient underwent CT and MRI examination and the extent of the lesion was delineated. NCCT and CECT brain has shown the expansile mass in the right frontal region extending

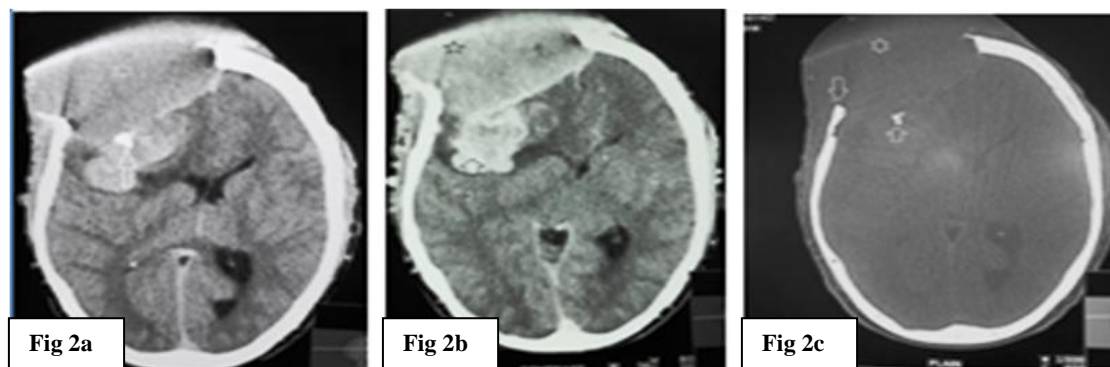


Figure 2 – CT Head 2a- Axial section NCCT shows soft tissue swelling on right fronto- parietal region with both extra and intra cranial extensions (white star) along with the patch of destroyed bone (white arrow). 2b - CECT shows mild enhancement of mass (black star) and avid enhancement of its small intracranial extension (vertical black arrow). 2c - Bone window shows extracranial mass (white star) and intracranial destroyed fragment of bone (vertical up arrow) with clear transition zone (vertical down arrow).

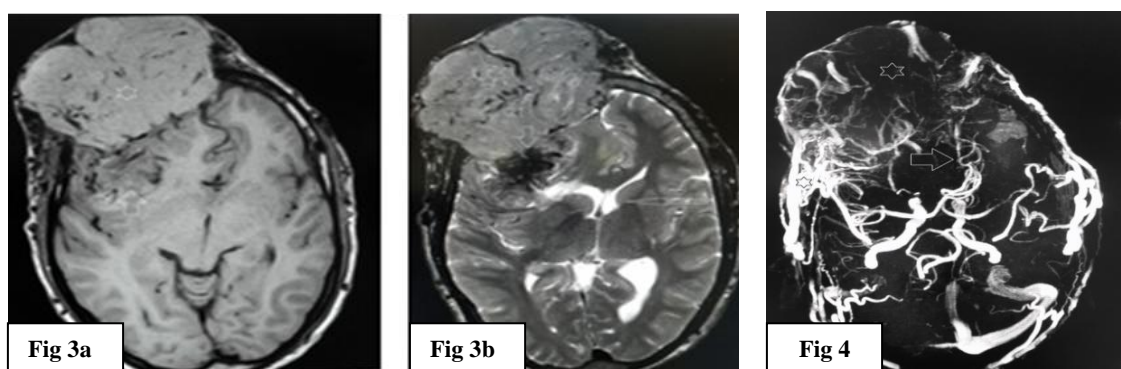


Figure 3 - MRI Head. 3a - T1W plain axial section shows extracranial non-homogenous iso-intense component (white star) with intracranial hypointense part (vertical up arrow) and many flow voids. 3b - T2W axial section shows iso to slight hyperintense mass (white star) with inhomogenous hypointense intracranial part (white down arrow). There is mass effect leading to midline shift (horizontal white arrow). **Figure 4 - TOF MR angiography** shows multiple draining veins at the interface of the mass (black star) and displacement of ACAs to the left side (white arrow).

towards left frontal side. This was of extra axial in nature. There was destruction of underlying table with intracranial extension. Transition zone was very well demarcated. No calcification or ossifying matrix was noticed in the lesion except the fragment of destroyed bone (**Figure 2 a, b, c**).

There was mild enhancement of the extra cranial component but intense enhancement of intracranial part leading to mild midline shift. MRI had further confirmed the contents almost resembling soft tissue. Post gadolinium enhancement was also noticed (**Figure 3a & b**). MR angiography showed extra cranial feeders with meshwork of draining veins (**Figure 4**). MR spectroscopy also has shown choline peak pointing towards the malignant nature (**Figure 5**). FNAC confirmed the diagnosis.

The patient has been planned for embolisation and excision.

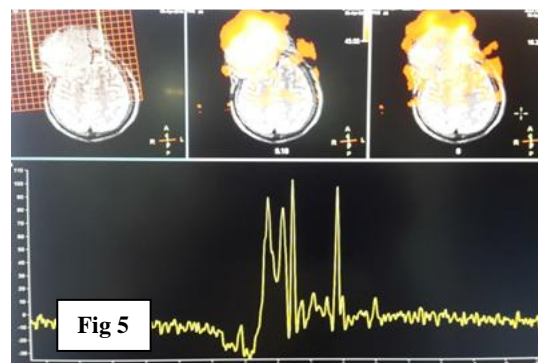


Figure 5 - MR Spectroscopy shows other peaks in addition to NAA pointing to the aggressive nature of the mass.

DISCUSSION

Calvarial neoplasms account 0.8% of all the bone tumors. Cranial vault haemangiomas are less in frequency [2]. These do not produce any symptoms but the pressure and compression features can lead to secondary symptoms. These do not bleed. The bony involvement can best be demonstrated by CT. MRI is the best modality for their evaluation and extension [3]. MRI also shows better description of fatty hyper intense diploic space and the matrix of the lesion. Various neurovascular structures in the adjoining region can be delineated for their involvement. T1W shows hyper intensity and T2W show heterogenous hyperintensity. These lesions show variable post contrast enhancement depending upon the underlying constituents and type of vascular malformation [4].

Clinico-radiological-pathological diagnosis is essential part of these lesions. Lloret et al (2009) has reviewed the record of 61 cases of calvarial lesions and found the most common lesions were osteoma (26%), eosinophilic granuloma (18%), fibrous dysplasia (20%), osseous haemangioma (13%), epidermoids cysts (7%), miscellaneous benign lesions (8%) and osteosarcoma (8%). These did not include metastasis and multiple myeloma lesions [5]. It is very important to know the site of origin, size, number, pattern of bone destruction, margins, periosteal reaction, soft tissue component with extension and the type of matrix of the tumors. Aggressive tumors usually have poor zone of transition.

Calvarial haemangiomas gives appearance of malignant tumors when extend both intracranially and extracranially. There is no periosteal reaction. MRI appearance shows serpentine vessels within the lesion and can be recognized easily [6]. In our case the giant tumor had both intracranial and extra cranial components with clear transition zone of skull table. Bone metastasis from few malignancies like renal cell carcinoma can present as multiple lytic lesions and can resemble cranial vault hemangiomas. These can either be osteoblastic or osteolytic in nature.

Various options for the treatment are radiation therapy, pre operative embolisation, surgical resection or only intralesional ethanol injection [7]. The treatment decision depends upon the main complaints or aesthetic reasons. The mainstay of treatment remains as embolisation with excision of the mass in majority of the cases. Prognosis of

the disease is excellent and recurrence is rare if total excision is made [8].

CONCLUSION

Giant calvarial haemangioma do not show any symptoms for long time but keep on growing under the scalp. These extend to the intracranial compartment after destruction of the table. CT and MRI play a great role in the decision and roadmap of the management. The local aggressive role should not be confused with malignancy until or unless proved otherwise. Pre embolisation before surgical excision is of great benefit to avoid bleeding catastrophe.

REFERENCES

1. Kuzeyli K, Usul H, Cakir E, Caylan R, Rei A, Baykal S, et al. Multifocal intradiploic cavernous hemangioma of the skull associated with nasal osteoma. *Acta Neurochir (Wien)*. 2003; 145: 323-326.
2. Peterson DL, Murk SE, Story JL. Multifocal cavernous hemangioma of the skull: report of a case and review of the literature. *Neurosurgery*. 1992; 30: 778-781.
3. Bastug D, Ortiz O, Schochet SS. Hemangiomas in the calvaria: imaging findings. *AJR Am J Roentgenol*. 1995; 164: 683-687.
4. Ortiz O, Schochet S, Bastug D. Imaging evaluation and clinicopathologic correlation of mass lesions involving the calvaria. Part I: congenital and traumatic lesions. *Int J Neuroradiol*. 1999; 5: 96-108.
5. Lloret I, Server A, Taksdal I. Calvarial lesions: a radiological approach to diagnosis. *Acta Radiol*. 2009; 50:531-542.
6. Murphey MD, Fairbairn KJ, Parman LM, Baxter KG, Parsa MB, Smith WS. From the archives of the AFIP: Musculoskeletal angiomatous lesions: radiologic-pathologic correlation. *Radiographics*. 1995; 15:893-917.
7. Reis BL, Carvalho GT, Sousa AA et-al. Primary hemangioma of the skull. *Arq Neuropsiquiatr*. 2008; 66 (3A):569-571.
8. Relf SJ, Bartley GB, Unni KK. Primary orbital intraosseous hemangioma. *Ophthalmology* 1991. 98(4): - 541-6.

How to cite this article: Sharma BB, Sharma S, Sarin M, Jilowa S, Kaur J. Giant Cranial Vault Frontal Haemangioma – A Case Report. *Indian J Case Reports*. 2016; 2(2): 43-45.

Conflict of interest: None stated, Funding: Nil