

## A rare form of pancreatic diabetes complicated by portal venous thrombosis: A 25-year follow-up

Nesrine Cheikhrouhou, Ines Barka, Koussay Ach, Larbi Chaieb

From, Department of endocrinology, Farhat Hached University Hospital, Sousse, Tunisia

**Correspondence to:** Dr Nesrine Cheikhrouhou, Department of endocrinology, Farhat Hached University Hospital, Sousse, Tunisia, Email: [nesrina87@live.fr](mailto:nesrina87@live.fr)

Received: 22 March 2016

Initial Review: 24 April 2016

Accepted: 28 April 2016

Published Online: 07 May 2016

### ABSTRACT

Fibrocalculous pancreatic diabetes (FCPD) is an uncommon type of diabetes mellitus, so called tropical diabetes, due to chronic calcific non-alcoholic pancreatitis. This type of diabetes is associated to several particularities based on glycemic control and the occurrence of degenerative and metabolic complications, in addition to chronic pancreatitis complications such as venous thrombosis. We report here a rare case of a young North-African patient with long standing FCPD followed for 25 years and complicated by portal venous thrombosis. This case presentation highlights how important is to suspect fibrocalculous pancreatic diabetes especially in the presence of chronic abdominal pain. The follow-up of such patients should be focused not only on the clinical and biological markers of diabetes, but also on pancreatitis complications.

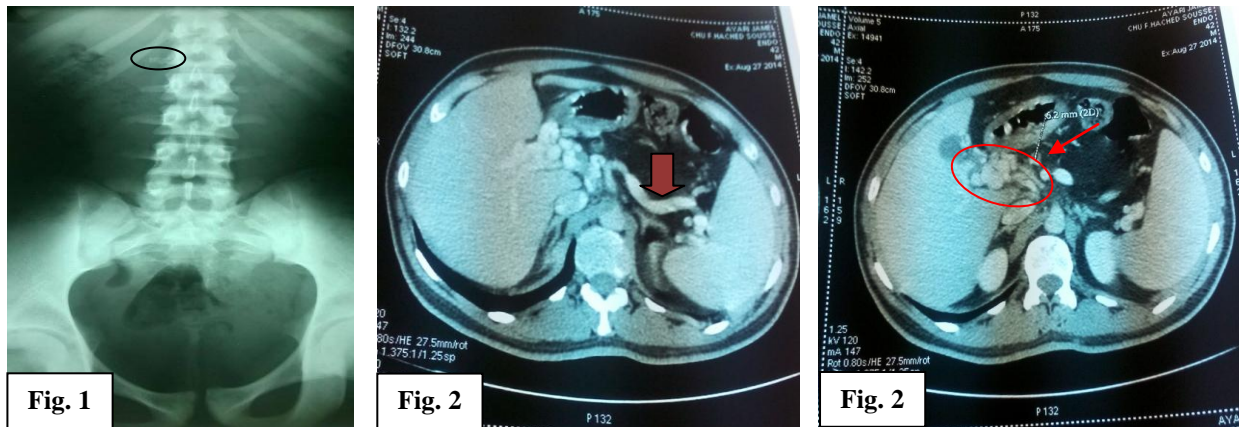
**Keywords:** Chronic pancreatitis, Fibrocalculous pancreatic diabetes, North-Africa, Tropical diabetes

Both type 1 and type 2 diabetes mellitus (DM) are well known by the physicians and general population but other rare forms of DM such as Fibrocalculous pancreatic diabetes (FCPD) should be more studied. The FCPD is a DM secondary to tropical chronic pancreatitis (TCP) which is considered as a form of chronic calcific non-alcoholic pancreatitis. This type of DM is almost exclusively met in the developing countries of the tropical world [1].

There are little data on the prevalence of FCPD in the general population. A study by Balaji et al. [2] found the prevalence of TCP to be one in 793 individuals in Kerala. In a clinic based study from Chennai, the prevalence of FCPD was found to have decreased from 1.6 % (for the years 1991–1995) to 0.2 % (during the years 2006–2010) [3]. The classical triad of TCP consists of abdominal pain, steatorrhea, and hyperglycemia.

### CASE PRESENTATION

A 17-year-old male, with no familial history of diabetes and no alcohol consumption, was hospitalized in 1989 for ketone prone diabetes. He has reported abdominal pain for about 2 years, in a chronic and relapsing mode associated with progressive weight loss. Physical examination has revealed body mass index (BMI) of 18.8 kg/m<sup>2</sup>; waist circumference of 85 cm, systolic blood pressure of 110 mmHg and diastolic blood pressure of 80 mmHg. Biologic plasma investigation has shown a raised random blood glycemia level of 26.7 mmol/l and hemoglobin level of 14.6 g/dl. The lipid profile, amylase and protidemia levels were normal. The urinalysis showed massive glycosuria and ketonuria. The abdominal X-ray showed multiple pancreatic calcifications (figure 1). Ketosis was well managed and the patient has been treated by high doses of NPH insulin (1IU/kg/day) to achieve good glycemic control. Later, insulin dose degression was scheduled.



**Figures:** Fig. 1 - Abdominal X-ray, performed in 1989, has shown multiple pancreatic calcifications in the pancreatic area. Fig. 2 - Contrast Enhanced Computed tomography scan demonstrating complete involution of pancreas (↓) and portal cavernoma (○) and dilatation of main pancreatic duct (→)

The 25-year follow-up showed difficulty to obtain a good glycemic control despite of a good treatment adherence. The patient presented frequent mild hypoglycemia (> 2/week), with mild polyuria and nocturia. The fasting blood glucose level was always within 10-15 mmol/l with glycated hemoglobin (HbA1c) within 8.5% - 11%. Improvement of glycemic control was obtained by the use of insulin analogues. No diabetic ketoacidosis has occurred during the evolution. Diabetic retinopathy has been diagnosed and treated after 10 year-duration of DM.

In 2009, which corresponds to a 20-year-history of DM, the patient presented with abdominal pain and fever. Acute pancreatitis with worsening signs of malabsorption was documented, including leucocytosis of 21900/mm<sup>3</sup>; anemia of 11.0 g/dl; hypoalbuminemia of 30 g/l and hypocholesterolemia of 2.5 mmol/l. Abdominal computed tomography (CT) scans revealed chronic calcifiant pancreatitis with porto-spleno-mesenteric venous thrombosis. No pancreatic tumor was found. The etiologic exploration of thrombosis revealed a resistance of activated protein C. The patient was treated by pancreatic enzyme granules and a lifelong anti coagulation therapy. The last biologic control, done in 2013, showed an improved glycemic control without any malabsorption sign. Abdominal CT showed complete involution of pancreas and a portal cavernoma (figure 2).

## DISCUSSION

We report a 25 years follow-up of FCPD occurred in a North-African 17 year-old man and complicated by portal

thrombosis. FCPD was first reported in 1959 by Zuidema, among the lower socioeconomic strata of society [4]. This form was included in the World Health Organization (WHO) classification in 1980 as tropical diabetes [5]. FCPD is secondary to a juvenile form of chronic calcific, non-alcoholic pancreatitis, prevalent almost exclusively in the developing countries of the tropical world [6]. Several studies have debated the theories that malnutrition have etiological role in TCP, they confirmed a link between the serine protease inhibitor, Kazal type 1 (SPINK 1) gene and TCP. It is a vital protease inhibitor that prevents unregulated or inappropriate activation of the pancreatic enzyme cascade by inhibiting trypsin activity [7-9]. FCPD has been classified later by the WHO as a form of diabetes secondary to the exocrine pancreas disease (Type 3c diabetes mellitus) [10].

Some of its distinctive features are younger onset, presence of large intraductal calculi, accelerated course of the disease, and high susceptibility to pancreatic cancer. Our patient was first admitted with ketosis-prone diabetes. Based on this, as well as young age and a BMI 18.8 kg/m<sup>2</sup>, he could be considered as a patient with type 1 DM. Unfortunately at that time (1989), anti-pancreatic antibodies were not common to assess in our area. Nevertheless, our patient presented many additional features suggestive of FCPD as reported in the literature, such as an onset during youth, rapid progression with bad glycemic control on insulin therapy and association to pancreatic calcifications without alcohol consumption. This type of diabetes is classically known to be difficult to achieve a good glycemic control with frequent

hypoglycemic episodes, which was the case of our patient. Brittle diabetes in patients with FCPD may be explained by the loss of pancreatic counter-regulatory hormones i.e. somatostatin and glucagon, as well as impaired and irregular nutrient absorption due to exocrine pancreatic insufficiency. However, this concept remains uncertain.

A British study on patients with Type 3c DM due to pancreatectomy reported a mean HbA1c of 8.1%, which was not statistically significant from the entire diabetic population (8.2%). None of the patients in this study reported a severe hypoglycemic event [11]. No diabetic ketoacidosis was noticed in our patient during the 25-year follow-up. One of the mechanisms for the ketosis resistance seen in FCPD patients was suggested by Mohan et al. They demonstrated that there was no significant change in plasma glucagon levels in FCPD patients in response to an oral glucose load compared with Type 2 diabetic patients, in whom plasma glucagon levels rose after the glucose load [12].

Our patient presented with retinopathy after 9 years of diabetes diagnosis. The occurrence of retinopathy, nephropathy [13] and neuropathy [14] in FCPD patients was reported in the literature. In a cross sectional comparative study, the overall prevalence of these complications was not different from a matched group of patients with type 2 DM [15]. However, the occurrence of cardiovascular events like coronary artery disease and peripheral vascular disease is lower among FCPD patients and this could be attributed to the lower age and leanness of these subjects, as well as to lower lipid levels [7]. Our patient has not presented any vascular disease.

Venous thrombosis is typically reported in cases of chronic pancreatitis. It is localized in the splenic vein and less commonly in the superior mesenteric vein or portal vein [16,19]. Thrombotic complications have been known to be more common in alcohol-induced, necrotizing, and chronic pancreatitis [17, 18]. We have documented in our case a portospleno-mesenteric venous thrombosis associated with non-necrotizing and non-alcoholic pancreatitis. This complication results from a combination of local and systemic prothrombotic risk factors. Local factors are mainly stasis, spasm, and mass effects from the surrounding inflamed pancreas and direct damage of the venous wall by liberated enzymes [16]. Systemic factors may be involved such as resistance to activated protein C, as confirmed in our patient. Cavernous transformation of

the portal vein is a sequela of portal vein thrombosis and it is the replacement of the normal single channel portal vein with numerous tortuous venous channels [17]. This process takes a variable amount of time, from as little as a week to a year [18,20].

Although no randomized controlled trial regarding the use of anticoagulants in portal vein thrombosis has been conducted, the use of unfractionated heparin, with subsequent transition to oral anticoagulation, is the most common approach. A particular attention is needed for patients with pancreatic diabetes to prevent thrombotic complications that could be fatal. We suggest clinical attention and probably biologic screening for systemic disorders of hemostasis for these patients.

## CONCLUSION

The fibrocalculous pancreatic diabetes remains a rare entity which should be suspected in young patient with no family history of diabetes or autoimmune predisposition and also the occurrence of hypoglycemia with insulin. Those patients need a regular monitoring to detect earlier multiple complications especially thrombotic complications which could be severe and even fatal.

## REFERENCES

1. Unnikrishnan R, Mohan V. Fibrocalculous pancreatic diabetes (FCPD). *Acta Diabetol.* 2015; 52(1): 1-9.
2. Balaji LN, Tandon RK, Tandon BN, Banks PA. Prevalence and clinical features of chronic pancreatitis in southern India. *Int J Pancreatol.* 1994; 15: 29-34.
3. Papita R, Nazir A, Anbalagan VP, Anjana RM, Pithumoni C, Chari S, et al. Secular trends of fibrocalculous pancreatic diabetes and diabetes secondary to alcoholic chronic pancreatitis at a tertiary care diabetes centre in South India. *JOP.* 2012; 13: 205-209.
4. Zuidema PJ. Cirrhosis and disseminated calcification of the pancreas in patients with malnutrition. *Trop Geogr Med.* 1959; 11: 70-74.
5. World Health Organization. WHO Study Group Report on Diabetes Mellitus. WHO Technical Report Series no. 727. Geneva: WHO, 1985.
6. Barman K, Premalatha G, Mohan V. Tropical chronic pancreatitis. *Postgrad Med J.* 2003; 79: 606-615.
7. Hassan Z, Mohan V, Ali L, Allotey R, Barakat K, Faruque MO, et al. SPINK1 is a susceptibility gene for fibrocalculous pancreatic diabetes in subjects from Indian subcontinent. *Am J Hum Genet.* 2002; 71: 964-968.

8. Bhatia E, Choudhuri G, Sikora S, et al. Tropical calcific pancreatitis: Strong association with SPINK 1 trypsin inhibitor mutation. *Gastroenterology*. 2002; 123: 1020–1025.
9. Whitcomb D, Gorry MC, Preston RA, Furey W, Sossenheimer MJ, Ulrich CD, et al. Hereditary pancreatitis is caused by a mutation in the cationic trypsinogen gene. *Nat Genet*. 1996; 14: 141–145.
10. Alberti KG, Zimmet PZ. Definition, diagnosis and classification of diabetes mellitus and its complications. Part 1: Diagnosis and classification of diabetes mellitus provisional report of a WHO consultation. *Diabet Med*. 1998; 15: 539–53.
11. Jethwa P, Sodergren M, Lala A, Webber J, Buckels JA, Bramhall SR, et al. Diabetic control after total pancreatectomy. *Dig Liver Dis*. 2006; 38:415–9
12. Mohan V, Snehalatha C, Ramachandran A, Chari S, Madanagopalan N, Viswanathan M. Plasma glucagon responses in tropical fibrocalculous pancreatic diabetes. *Diabetes Res Clin Pract*. 1990; 9: 97–101.
13. Mohan R, Rajendran B, Mohan V, Ramachandran A, Vishwanathan M, Kohner EM. Retinopathy in tropical pancreatic diabetes. *Arch Ophthalmol*. 1985; 103: 1487–9.
14. Ramachandran A, Mohan V, Kumaravel TS, Velmurugendran CU, Snehalatha C, Chinnikrishnudu M, et al. Peripheral neuropathy in tropical pancreatic diabetes. *Acta Diabetol Lat*. 1986; 23: 135–40.
15. Barman KK, Padmanabhan M, Premalatha G, Deepa R, Rema M, Mohan V. Prevalence of diabetic complications in fibrocalculous pancreatic diabetic patients and type 2 diabetic patients: A cross sectional comparative study. *J Diabetes Complications*. 2004; 18: 264–70.
16. Mohan V, Premalatha G, Padma A, Chari ST, Pitchumoni CS. Fibrocalculous pancreatic diabetes: Long-term survival analysis. *Diabetes Care*. 1996; 19: 1274–8.
17. Mortelé KJ, Mergo PJ, Taylor HM, Wiesner W, Cantisani V, Ernst MD, et al. Peripancreatic vascular abnormalities complicating acute pancreatitis: contrastenhanced helical CT findings. *Eur J Radiol*. 2004; 52: 67–72.
18. Dörffel T, Wruck T, Rückert RI, Romaniuk P, Dörffel Q, Wermke W. Vascular complications in acute pancreatitis assessed by color duplex ultrasonography. *Pancreas*. 2000; 21: 126–133.
19. Mendelson RM, Anderson J, Marshall M, Ramsay D. Vascular complications of pancreatitis. *ANZ J Surg*. 2005; 75: 1073–1079.
20. De Gaetano AM, Lafortune M, Patriquin H, De Franco A, Aubin B, Paradis K. Cavernous transformation of the portal vein: patterns of intrahepatic and splanchnic collateral circulation detected with Doppler sonography. *AJR Am J Roentgenol*. 1995; 165: 1151-5.

**How to cite this article:** Cheikhrouhou N, Barka I, Ach K, Chaieb L. A Rare Form Of Pancreatic Diabetes Complicated By Portal Venous Thrombosis: A 25-Year Follow-Up. *Indian J Case Reports*. 2016; 2(2): 32-35.

*Conflict of interest: None stated, Funding: Nil*