

Rhinosporidioma: Primary Cutaneous Rhinosporidiosis - A Rare Case Report

A Prabakar, G Karthikeyan, R Syed

From Department of General Surgery, Thanjavur Medical College, Thanjavur, Tamil Nadu, India

Correspondence to: Dr A Prabakar, Department of General Surgery, Thanjavur Medical College, Thanjavur, Tamil Nadu, India.

E mail: dr.a.prabakar@gmail.com.

Received: 13 February 2016

Initial Review: 09 March 2016

Accepted: 17 April 2016

Published online: 27 April 2016

ABSTRACT

Rhinosporidiosis is a chronic granulomatous disease caused by *Rhinosporidium seeberi*. *Rhinosporidium seeberi* causes granulomatous inflammation of mucocutaneous sites, presenting most frequently as polypoidal lesions in the nose. Sites like the conjunctiva, trachea, nasopharynx, skin, and genitourinary tract are less frequently involved. Primary cutaneous lesion is extremely rare and it is often mistaken for soft-tissue tumour. We present a case of 55 years male patient from Thanjavur, Tamilnadu, with primary cutaneous rhinosporidiosis without mucosal involvement.

Keywords: Cutaneous rhinosporidiosis, Rhinosporidioma, Rhinosporidiosis

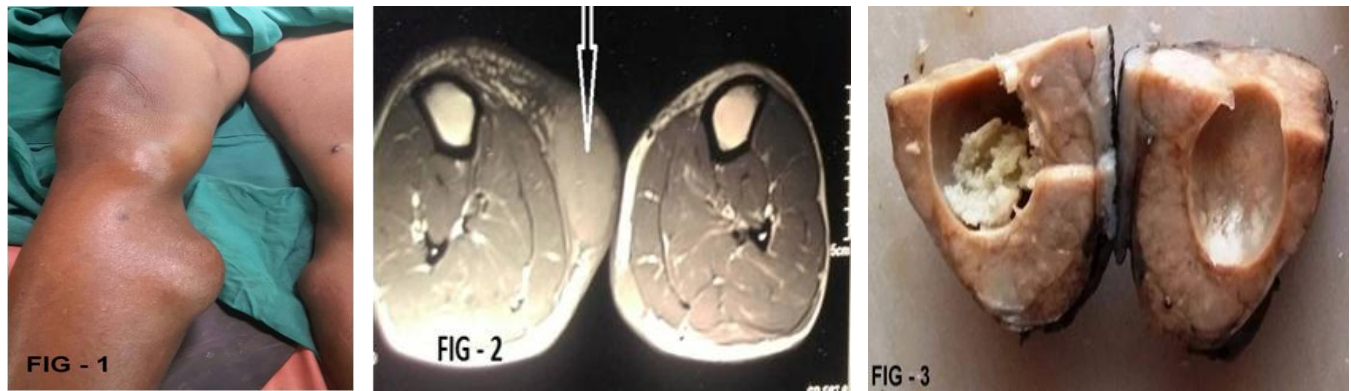
Rhinosporidiosis is a chronic granulomatous infection caused by *Rhinosporidium seeberi*. It is endemic in India and in Sri Lanka but has also been reported from United States, South America and Iran [1]. In India, the disease is endemic in Tamilnadu, Kerala, parts of Orissa and eastern Madhya Pradesh. Infection is usually caused by contact with fresh water such as swimming pools. Rhinosporidiosis frequently involves the nasopharynx (70%) presenting as painless, friable, polypoidal growth which may hang anteriorly into the nares and posteriorly into the pharynx. The cutaneous lesions without mucosal involvement are extremely rare and they present as asymptomatic soft tissue growth or warty growth [1-2]. We report this rare case of primary cutaneous rhinosporidiosis without mucosal involvement.

CASE REPORT

A 55 years male patient was admitted to our institution, with multiple swellings all over the body of 4 years

duration. The initial lesion appeared in the right thigh; followed by in right knee, right leg and left leg. There was also multiple small swelling all over the body of recent onset within 4 months duration. These swellings were not associated with pain, bleeding, ulceration or discharge. There was gradual increase in the size of the swellings. He did not have any difficulty in walking or any sensory deficit.

The systemic examination of the patient was normal. Amongst various swellings, there was 7x4 cm swelling in the right thigh in lower one-third in the anterior aspect, 7x3 cm swelling in right anteromedial aspect of upper one third of leg, 3x4 cm swelling in right knee and 6x3 cm swelling in left leg (Fig 1). These were all soft to firm in consistency, non-tender, non-compressible, mobile lesions with smooth surface. Similar swellings of varying size and swellings were noted in lower limbs, abdomen and back of the trunk. Clinical diagnosis of multiple lipoma was made.



Figures: Fig 1 - Multiple subcutaneous lesions in both lower limbs. Fig 2 - MRI scans of lower limb showing lesion in the subcutaneous plane. Fig 3 - Cut section of the specimen

On investigation, haematological and biochemical examinations were normal. Chest X-ray and Ultrasound abdomen were normal. MRI of both lower limbs were done, which showed subcutaneous swelling without penetrating the underlying muscle or bone (Fig 2). Fine needle aspiration cytology was done which was reported as adipocytes with spindle cells and multinucleated giant cells, with few adipocytes showing degenerative changes in a hemorrhagic background. Excision biopsy was planned to confirm the diagnosis. An excisional biopsy of the swellings in right thigh, right knee, right leg and left leg was carried with a rim of normal skin around (Fig 3).

Histopathological examination sections showed multiple round to oval structures – sporangiophores of different sizes with different stages of maturation, the laminated bodies and mature endospores with surrounding inflammatory cellular infiltrates. Sporangiophores were also seen bursting out through the endospores with smaller sporangia in large numbers. These findings were suggestive of rhinosporidiosis. PAS staining was done to confirm the diagnosis which revealed thick walled laminated bodies, released from mature endospores and then go on to give rise to spherical juvenile sporangia, which is in large numbers. There were immature and mature sporangia (Fig 4 & 5). A diagnosis of cutaneous rhinosporidiosis was made.

Patient was subjected to ENT examination to rule out mucosal lesion which was normal. CT brain was done to rule out disseminated rhinosporidiosis and was found to be normal. He did not give any previous history suggestive of mucocutaneous or nasopharyngeal rhinosporidiosis. Hence, a diagnosis of primary cutaneous rhinosporidiosis

was made. Following surgical excision, the patient was put on dapsone 100 mg twice daily and is on regular follow up. Patient is recovering well and no more swelling appeared in the follow up period of 3 months.

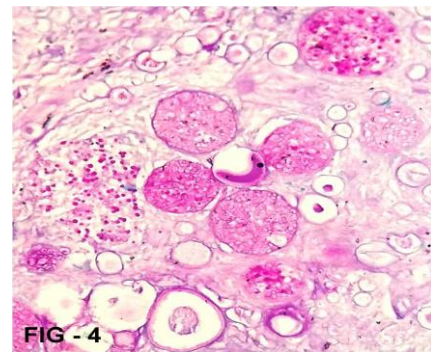


Fig 4 - HPE showing rhinosporidiosis

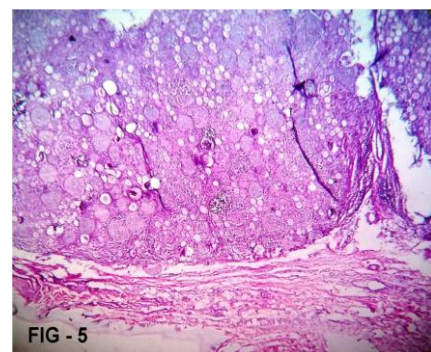


Fig 5 - HPE showing rhinosporidiosis

DISCUSSION

Rhinosporidiosis is a chronic recurrent granulomatous disease of man and animals, caused by fungus

Rhinosporidium Seeberi. The organism has not been cultured nor has it been successfully transmitted to experimental animals [3]. The infection affects nasal mucosa, ocular conjunctiva of human and animals producing slowly growing masses with pink to purple, friable polyps. Disease can manifest in four forms i.e. nasal, ocular, cutaneous and disseminated. Infection of nose and nasopharynx is observed in majority, while infection of the palpebral conjunctiva or associated structures like the lacrimal apparatus is observed in 15%. Cutaneous lesions are infrequent and are generally associated with mucosal lesions.

Cutaneous Rhinosporidiosis was initially described by Forsyth in 1924. Cutaneous lesions can occur due to autoinoculation or due to hematogenous spread and are described to be of three types: 1) Satellite lesions around the nasal polypoidal lesions 2) Disseminated lesions with visceral involvement and 3) Primary cutaneous lesions without internal organ involvement. Although primary cutaneous lesions appear to be uncommon, most authors have reported lesions that begin as tiny papules, which eventually developed into warty polypoidal growths. Poricha *et al.* described a male patient of rhinosporidiosis with multiple, mobile, subcutaneous nodules that suppurated and burst with the drainage of mucopurulent content leading to ulceration [4]. Other authors have described similar presentations either in the presence or absence of nasal involvement.

Date *et al.* described large lesions on the right thigh in a patient from Orissa and subsequently proposed the term "rhinosporidioma" [5]. Angunwala *et al* also described similar case of 44-year old male patient from Sri Lanka with large masses on thigh and anterior chest wall [6]. In above mentioned patients, the clinical appearance had led to the diagnosis of chondrosarcoma and soft-tissue sarcoma with biopsy showing the typical picture of rhinosporidiosis. Our patient with multiple tumor-like swellings was a unique presentation of primary cutaneous rhinosporidiomas.

Rhinosporidiosis remains a therapeutic challenge amenable only to surgical excision with a high risk of recurrence and occasional widespread and fatal complications. A number of previous studies using various drugs like dapsone, ketoconazole, ciprofloxacin and amphotericin B suggested encouraging results only with dapsone. Previous light and electron microscopic studies

have confirmed maturation arrest of spores and accelerated granulomatous response with fibrosis following the dapsone therapy [7]. Surgical removal and electrodesiccation are the treatments of choice [8]. Our patient has undergone surgical excision of all significant lesions and has been advised to take dapsone for one year.

CONCLUSION

The present case is being reported to highlight this rare presentation of primary cutaneous rhinosporidiosis that can masquerade as soft-tissue tumors. So, we should always consider the possibility of cutaneous rhinosporidiosis whenever we encounter patients with subcutaneous swellings especially in endemic areas.

REFERENCES

1. Kumari R, Laxmisha C, Thappa DM. Disseminated cutaneous rhinosporidiosis. *Dermatol Online J*. 2005; 11: 19.
2. Padmavathy L, Rao IL, Sevam SS, Sahoo CG. Disseminated cutaneous rhinosporidiosis in a HIV seropositive patient. *Indian J Dermatol Venerol Leprol*. 2001; 67: 332-3.
3. https://en.wikipedia.org/w/index.php?title=Rhinosporidium_seeberi&oldid=714932247.
4. Porichha O, Pradhan SC, Agarwal MN. Cutaneous rhinosporidiosis in a patient of lepromatous leprosy: A case report. *Indian J Lepr*. 1986; 58: 626-7.
5. Date A, Ramkrishna B, Lee VN, Sundraraj GD. Tumoral rhinosporidiosis. *Hiatopathology* 1995; 27: 288-90.
6. Anjunwala P, Teissera DA, Dissanaikie AS. Rhinosporidiosis presenting with two soft tissue tumors followed by dissemination. *Pathology*. 1999; 31: 57-8.
7. Job A, Venkateswaran S, Mathan M, Krishnaswami H, Raman R. Medical therapy of rhinosporidiosis with dapsone. *J Laryngol Otol*. 1993; 107: 809-12.
8. Kumari R, Nath AK, Rajalakshmi R, Adityan B, Thappa DM. Disseminated cutaneous rhinosporidiosis: varied morphological appearances on the skin. *Indian J Dermatol Venerol Leprol*. 2009; 75: 68-71.

How to cite this article: Prabakar A, karthikeyan G, Syed R. Rhinosporidioma: Primary Cutaneous Rhinosporidiosis - A Rare Case Report. *Indian J Case Reports*. 2016; 2(2): 27-29.

Conflict of interest: None stated, Funding: Nil