

Marjolin's Ulcer: a form of chronic non healing ulcer

Arjun Agarwal, Sreekanth Reddy, B R Keerthi, M S Ganesh, Sathyanarayan Shivkumaran

From, Department of Surgical Oncology, Vydehi Institute of Medical Sciences, Bengaluru, India

Correspondence to: Dr Arjun Agarwal, Vydehi Institute of Medical Sciences, Bengaluru, India Email: arjunbly@hotmail.com

Received: 27 June 2016

Initial Review: 09 July 2016

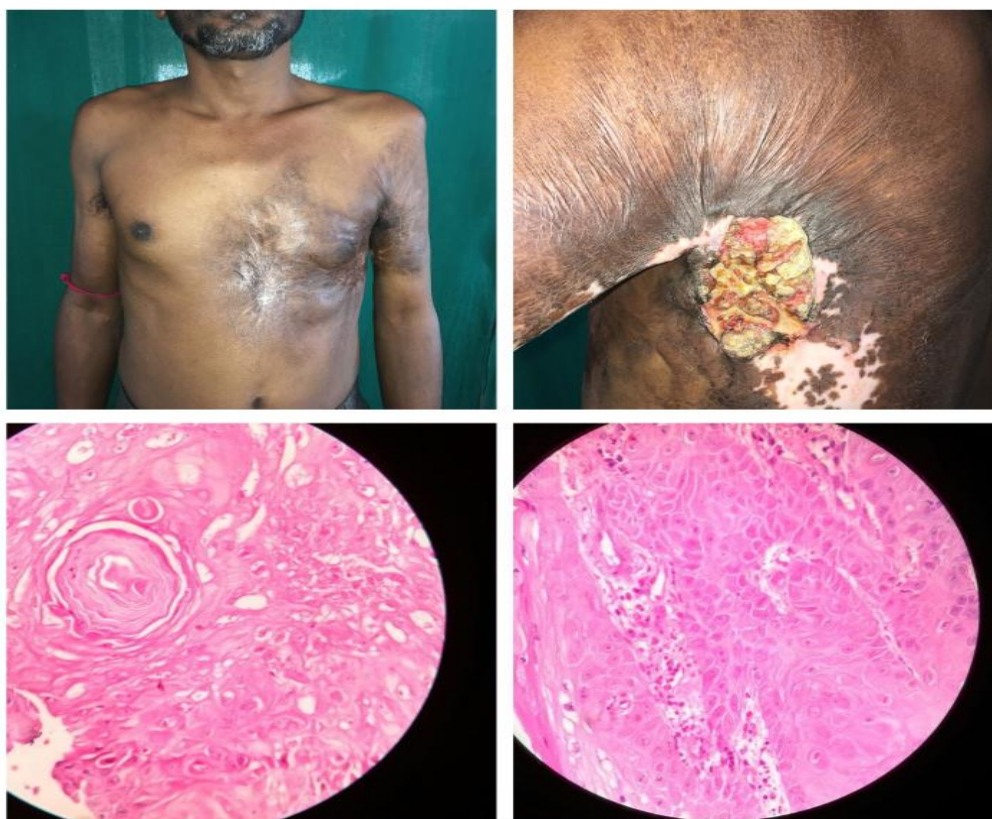
Accepted: 20 July 2016

Published Online: 14 August 2016

QUERY

A man sustained thermal injury 30 years ago and now he had presented with an ulcer in the left posterior axillary

region with serous discharge as shown in figures. What is the probable diagnosis?



Figures: **Fig A** - Man who sustained thermal injury 30 years ago, **Fig B** - Showing left posterior axillary region with a 10 x 8 cm indurated ulcer with everted edges and exuberant granulation tissue with serous discharge. **Fig C** - Showing keratin pearl seen with cytoplasmic keratinisation within neoplastic cells, **Fig D** - Showing acanthotic epidermis with invading sheets and nests of atypical squamous cells having high N:C ratio and moderate nuclear pleomorphism.

ANSWER: Marjolin's Ulcer, A Well Differentiated Squamous Cell Carcinoma

Marjolin's ulcer is defined as malignant degeneration arising within the pre-existing scar tissue or even in chronic inflammatory skin lesions. The most frequent site is in the lower extremity, especially the plantar foot. The leading cause is chronic burn wounds, as described originally by Marjolin [1]. The average age of latency is 30 to 35 years with a range from 11 to 75 years [1].

The classic triad of nodule formation, induration, and ulceration at a scar site suggest the diagnosis. In most instances, biopsied lesions demonstrate well-differentiated squamous cell tumors but can be basal cell or melanoma. Depending on the size and stage of the ulcer, wide excision with grafting or amputation is the mainstay of treatment [1].

To prevent this wound degeneration into squamous cell carcinoma, it is imperative to provide early and definitive wound coverage or replacement of unstable scar tissue

with healthy tissue. Although prevention is ideal, a high index of suspicion in chronic wounds is necessary so that early detection can prevent metastatic disease, which carries with it a poor prognosis [2].

REFERENCES

1. Pekarek B, Buck S, Osher LJ. A Comprehensive Review on Marjolin's Ulcers: Diagnosis and Treatment. *Am Col Certif Wound Spec.* 2011; 3(3): 60–64.
2. Tobin C, Sanger JR. Marjolin's Ulcers: A Case Series and Literature Review. *Wounds.* 2014; 26(9): 248-254.

How to cite this article: Agarwal A, Reddy S, Ganesh MS, Keerthi BR, Shivkumaran S. Marjolin's Ulcer: a form of chronic non healing ulcer. *Indian J Case Reports.* 2016; 2(3): 85-86.

Conflict of interest: None stated, Funding: Nil