

Primary primitive neuroectodermal tumor of the bladder: A case report

Bahattin Erdogan¹, Kismet Civi Cetin²

From ¹Expert PhD, ²Associate Professor, Department of Pathology, Eskisehir City Hospital, Odunpazari/Eskisehir, Turkey

ABSTRACT

A primitive neuroectodermal tumor (PNET) is part of the Ewing sarcoma family of tumors. PNET of the urinary bladder is extremely rare. In this paper, we describe the case of a 42-year-old man with a PNET of the bladder. He presented with dysuria and microscopic hematuria. Pelvic computed tomography showed a mass in the urinary bladder. He had undergone transurethral resection of the tumor. Histology of tumor biopsies showed a highly cellular, focally necrotic small round-cell tumor with numerous mitoses and occasional rosette-like structures. Strong CD99 and vimentin expression and focal reactivity to CD117 (c-kit) were observed in tumor cells. The patient did not accept surgery and chemotherapy. He is alive and well with no evidence of disease 4 years after the surgery.

Key words: Primitive neuroectodermal tumor, Urinary bladder, Ewing sarcoma

Tumors in the Ewing's sarcoma (ES) family develop in the bones or nearby soft tissues and share some common features. Three main types of ES have been described: ES of the bone, extra-osseous (extraskelatal) ES, and primitive neuroectodermal tumor (PNET) [1]. The peak incidence of PNET is at ages 10–20 years [1,2]. PNET may occasionally be observed in other sites such as the chest wall, head and neck, kidneys, adrenal glands, female genital tract, extremities, prostate, and scrotal sac [3,4]. Their metastatic or localized form determines the prognosis of these pathologies. When the tumor is localized, a survival rate of more than 70% at 4 years is evident, and it is <30% if it is in the metastasis stage. PNET of the urinary bladder is rare but more frequent in older adults [5-7].

We presented the case of a 42-year-old male patient with primary bladder PNET due to its rarity.

CASE REPORT

A 42-year-old man presented with dysuria and irritative urinary symptoms. No gross hematuria or weight loss was registered. He had no personal or family history of tumors.


Physical examination and routine blood parameters were regular. Chest X-ray, bone, and computed tomography (CT) scans did not show extravescical extension. The patient underwent a cystoscopy due to hematuria. In the cystoscopic evaluation, a 30 × 20 × 20 mm nodular mass was detected in the trigone of the bladder.

The mass in the bladder was removed by transurethral resection. Microscopic examination revealed a tumor diffusely infiltrating the lamina propria and muscularis propria under the intact urothelium. It comprised small round blue cells with scant cytoplasm, monotonous round or oval nuclei, stippled chromatin, and small nucleoli. Neoplastic cells were arranged in solid sheets, nests, tightly packed cords, and ribbons (Fig. 1a and b). Homer-Wright rosettes were observed occasionally, while mitotic activity was abundant. No surface papillary projections, *in situ* intraepithelial neoplasia, or urothelial carcinoma was identified (Fig. 1b). Periodic acid-Schiff stain was negative. Pan-cytokeratin, epithelial membrane antigen, chromogranin, synaptophysin, CD56, S100, HMB45, desmin, cytokeratin 20, smooth muscle actin, leukocyte common antigen, and terminal deoxynucleotidyl transferase were negative. Immunohistochemistry (IHC) staining confirmed PNET diagnosis with strong reactivity for CD99 and vimentin markers and focal reactivity to CD117 (c-kit) (Fig. 2a and b). The diagnosis was established according to an IHC evaluation. The metastatic evaluation was negative.

The patient refused to undergo radical cystectomy, systemic chemotherapy, and radiotherapy. Follow-up patient assessments, including the results of periodic cystoscopy and imaging studies, were routine until 2022. He is well after 4 years of follow-up, with no signs of recurrence or metastasis.

DISCUSSION

PNET is a high-grade malignant neoplasm within the Ewing family of tumors originating from embryonic migrating neural crest cells. It predominantly affects bones and soft tissues in children and

Access this article online	
Received - 20 August 2024 Initial Review - 04 September 2024 Accepted - 19 October 2024	Quick Response code 
DOI: 10.32677/ijcr.v10i12.4777	

Correspondence to: Bahattin Erdogan, 71 Evler, Çevre Yolu, Odunpazari/Eskisehir - 26080, Turkey. E-mail: bhntnrdgn@gmail.com

© 2024 Creative Commons Attribution-NonCommercial 4.0 International License (CC BY-NC-ND 4.0).

adolescents. PNET and ES are closely related, both characterized by the t(11;22)(q24;q12) translocation present in about 90% of cases, as well as the variant t(21;22)(q22;q12) translocation. Reverse transcription-polymerase chain reaction (RT-PCR)

studies facilitate a more detailed characterization of these tumors by expanding the molecular spectrum. Immunohistochemically, PNETs are positive for the anti-CD99 antibody directed against the MIC2 gene product, with over 90% of cases showing

Table 1: Reported series of primary peripheral primitive neuroectodermal tumors of the urinary bladder

Author	Year of publication	Age/sex	Symptoms	Growth pattern	HC stain			IHC stains		
					PAS	CD99	C-KIT	NSE	S100	PAN CK
Banerjee <i>et al.</i>	1997	21/M	Microscopic hematuria and dysuria	Endophytic	+	+++	ND	Negative	Focal	Focal
Gousse <i>et al.</i>	1997	15/F	Macroscopic hematuria	Endophytic	+	+++	ND	Focal	Negative	ND
Desai <i>et al.</i>	1998	38/F	Gross hematuria	Endophytic and exophytic	+	+++	ND	+++	Negative	Negative
Mentz <i>et al.</i>	1998	81/M	Fever, acute urinary retention	Endophytic and exophytic	+	+++	ND	+++	Negative	Negative
Colecchia <i>et al.</i>	2002	61/F	Gross hematuria	Exophytic	+	+++	ND	Focal	Negative	Negative
Kruger <i>et al.</i>	2003	62/M	Fatigue, urge incontinence	Endophytic and exophytic	+	+++	ND	Focal	Focal	Negative
Lopez-Beltran <i>et al.</i>	2006	21/F	Frequency, dysuria	Endophytic	+	+++	++	Focal	Negative	Negative
Meshaan <i>et al.</i>	2009	67/F	Mild hematuria	Endophytic and exophytic	ND	+++	ND	Fokal	Negative	Negative
Zheng <i>et al.</i>	2011	74/M	Frequency dysuria gross hematuria	Endophytic and exophytic	+	+++	ND	Focal	Negative	Negative
Okada <i>et al.</i>	2011	65/M	Gross hematuria and dysuria	Endophytic	+	+++	ND	Focal	Negative	Negative
Cameron <i>et al.</i>	2016	31/F	Polyuria and gross hematuria	poly uria and gross hematuria.	ND	+++	ND	ND	Focal	ND
Tonyalı <i>et al.</i>	2016	38/F	Gross hematuria	Endophytic	+	+++	ND	Focal	Negative	Negative
Yuhai <i>et al.</i>	2016	66/M	Gross hematuria	Endophytic	ND	+++	Negative	++	Negative	Negative
Alive <i>et al.</i>	2019	64/M	Abdominal pain and urination	Exophytic	+		ND	Focal	Negative	Negative
Orbegoso-Celis <i>et al.</i>	2021	Newborn/M	Gross hematuria	Exophytic	ND	+++	ND	ND	ND	ND
Liang <i>et al.</i>	2020	45/F	Urgency, frequency, and dysuria	Exophytic	ND	+++	ND	Focal	Focal	Negative
Nakdali Kassab <i>et al.</i>	2022	59/M	Hematuria and disuria	Endophytic	ND	+++	ND	++	Negative	Negative
Tian <i>et al.</i>	2022	58/M	Dysuria	Endophytic	ND	+++	ND	ND	ND	ND
Present case	2024	42/M	Dysuria	Endophytic and exophytic	Negative	+++	++	Negative	Negative	Negative

IHC: Immunohistochemistry

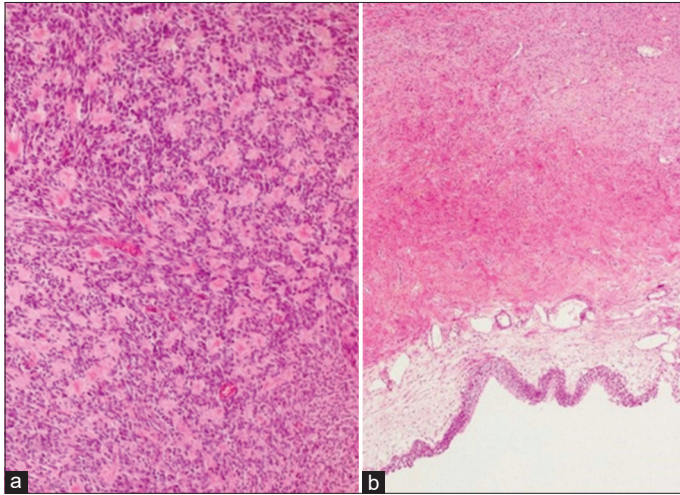


Figure 1: (a) (HE staining ×10), Uniform neoplastic cells with round to oval nuclei and small nucleoli. (b) (HE staining ×4), Tumor diffusely infiltrating the lamina propria and muscularis propria under an intact urothelium

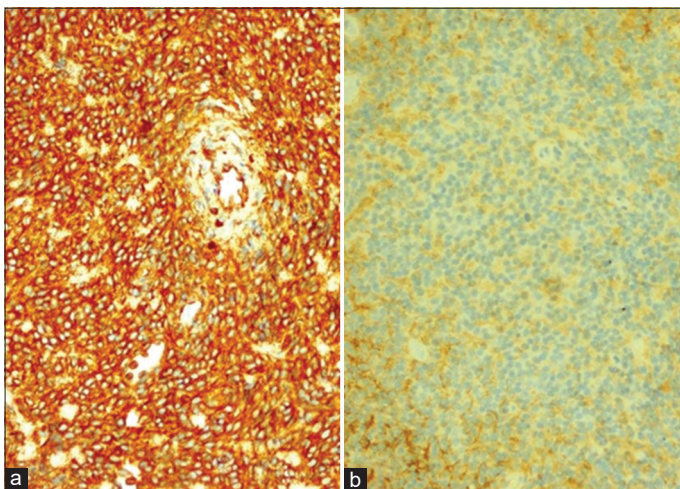


Figure 2: (a) Immunohistochemistry shows a diffuse-type lesion with strong CD99 positivity, (b) immunohistochemistry shows a diffuse-type lesion with vimentin positivity

this marker, making it crucial for diagnosis. A negative result necessitates consideration of alternative diagnoses [5].

Primary PNET of the urinary bladder is rare, with only 20 cases reported in the literature [7]. Patients range in age from 10 to 81 years, with a mean age of 44 years [8]. There is no gender preference [8]. Our patient was a 42-year-old male. The first reported case involved a newborn [9], and recent evidence suggests that immunodeficiency might be a risk factor for bladder PNET [2]. The most common symptoms include hematuria, dysuria, urinary frequency, and hydronephrosis, with hematuria being the most frequent [8]. However, in our case, the primary symptoms were dysuria and urinary irritation rather than hematuria.

Diagnostic imaging, including intravenous pyelography, magnetic resonance imaging, ultrasonography, CT, and bone scintigraphy, is typically employed for diagnosis and evaluation. Most PNETs are intravesical or predominantly endophytic, occasionally exhibiting exophytic growth from the bladder [6].

Histologically, PNETs comprise small, round, uniform, and poorly differentiated cells, with definitive diagnosis confirmed by IHC. These cells are strongly positive for CD99, and the EWS-FLI1 fusion gene test is also positive [5]. Differential diagnosis includes other small round cell malignancies such as small cell neuroendocrine carcinoma, embryonal rhabdomyosarcoma, and non-Hodgkin lymphoma. IHC, ultrastructural, and molecular genetic analyses are essential to differentiate PNET from these conditions.

In previous studies, light microscopy revealed rare rosette or pseudo-rosette formations. CD99 protein was consistently expressed in bladder PNETs, though it is not a specific biomarker. Additional markers include S-100, synaptophysin, vimentin, neuron-specific enolase (NSE), and desmin, with positivity rates of 83.3%, 58.3%, 70%, 33.3%, and 18.7%, respectively. Diagnosis of bladder PNET now relies on a combination of histology, IHC, fluorescence *in situ* hybridization, or RT-PCR, with molecular analysis confirming the presence of EWS gene rearrangement or EWS/FLI1 fusion transcripts [5]. However, in our case, while the diagnosis was made using histology and IHC, ultrastructural and molecular analyses were not performed. Reported studies of primary peripheral PNETs of the bladder appear in Table 1.

There is no definitive treatment guideline for primary bladder PNETs. Management typically mirrors that of PNETs in other organs, involving radical surgery, systemic chemotherapy, and radiotherapy [1]. Surgery combined with chemotherapy is recommended, especially in advanced cases, with various chemotherapeutic agents such as vincristine, adriamycin, cyclophosphamide, and cisplatin being utilized [2]. Radiotherapy is also employed for local disease control, though its efficacy in bladder PNETs requires further study due to limited follow-up data.

The prognosis for PNETs is generally poor, with worse outcomes in adults compared to children [7]. The prognosis is better for PNETs located in the head and neck compared to other body parts [8]. Factors associated with poor prognosis include advanced age, metastatic disease, and limited resection. Complete tumor resection and standard chemotherapy improve outcomes, while metastasis, incomplete resection, and inadequate response to chemotherapy are unfavorable factors [10]. Moreover, elevated NSE may indicate a poor prognosis among PNET patients [10,11]. Our case is the second reported patient with primary bladder PNET who showed no signs of recurrence or metastasis after 4 years of follow-up.

CONCLUSION

Reported cases of primitive neuroectodermal tumors in the urinary bladder are sporadic. This case is the only patient with primary bladder PNET that survived and remained tumor-free at least 4 years after diagnosis. With the description of new cases and long-term follow-up results, our knowledge and experience will improve.

REFERENCES

1. Parizi MK, Mousavi A, Sadeghyar N. An unusual natural history of a rare bladder tumor: Primitive neuroectodermal tumor. *Turk J Urol* 2019;45:316-8.
2. Gao L, Xie W, Li K, Huang G, Ji Y, Ou Y, *et al.* Primitive neuroectodermal tumor of urinary bladder: A case report and literature review. *Medicine* 2020;99:45.
3. Tian DW, Wang XC, Zhang H, Tan Y. Primitive neuroectodermal tumor of the prostate in a 58-year-old man: A case report. *World J Clin Cases* 2022;10:4145-52.
4. Gao J, Chow E, Aloma A, Gupta P. Peripheral primitive neuroendocrine tumor of the chest wall-a case report with pathological correlation. *Radiol Case Rep* 2018;13:392-96.
5. Lopez-Beltran A, Pérez-Seoane C, Montironi R, Hernández-Iglesias T, Mackintosh C, De Alava E, *et al.* Primary primitive neuroectodermal tumour of the urinary bladder: A clinico-pathological study emphasising immunohistochemical, ultrastructural and molecular analyses. *J Clin Pathol* 2006;59:775-8.
6. Liu B, Qi DJ, Zhang QF. Primary adult primitive neuroectodermal tumor of the bladder. A case report and literature review. *Medicine (Baltimore)* 2020;99:e21740.
7. Nakdali Kassab B, Pérez-Seoane Ballester H, Sarrió Sanz P, Sánchez Caballero L, Gómez Garberí M, Ortiz Gorraiz M. Ewing-like sarcoma bladder primary tumour: A case report and literature review. *Urol Case Rep* 2022;44:102139.
8. Tonyalı Ş, Yazıcı S, Yeşilirmak A, Ergen A. The Ewing's sarcoma family of tumors of urinary bladder: A case report and review of the literature. *Balkan Med J* 2016;33:462-6.
9. Orbegoso-Celis L, Bernuy-Guerrero R, Iman-Izquierdo F, Alfaro-Lujan L, Barreto Espinoza L, W Silva-Caso W. First report of a primitive neuroectodermal tumor of the bladder in a newborn. *Urol Case Rep* 2021;34:101458.
10. Lam CJ, Shayegan B. Complete resection of a primitive neuroectodermal tumor arising in the bladder of a 31-year-old female after neoadjuvant chemotherapy. *Can Urol Assoc J* 2016;10:E264-7.
11. Wu Y, Ji H, Zhang S, Zhang Y, Chu W, Mei Y, *et al.* Primary primitive neuroectodermal tumor of the urinary bladder: A case report and literature review. *Transl Cancer Res* 2021;10:4997-5004.

Funding: Nil; Conflicts of interest: Nil.

How to cite this article: Erdogan B, Cetin KC. Primary primitive neuroectodermal tumor of the bladder: A case report. *Indian J Case Reports*. 2024;10(12):395-398.