

Intracranial space-occupying lesion (cerebellar mass): A case report

Rahul Shil¹, Adalarisa Mitri²

From ¹Associate Professor, Department of MSN (Neuroscience), Sapthagiri Institute of Medical Sciences and Research Centre, Sapthagiri NPS University, Bengaluru, Karnataka, ²Lecturer, Department of Psychiatric Nursing, Arya Nursing College, Guwahati, Assam, India

ABSTRACT

Regardless of their unclear etiology, intracranial space-occupying lesions (ICSOL) are no longer uncommon. Malignancy or any other underlying pathology could be the cause of ISCOL. According to the report, the incidence could be found in children's as low as under the age of five. We present a case of ICSOL in a 13-year-old female. Following the magnetic resonance imaging, the surgery was done, and the prognosis was better. However, accurate and timely diagnosis is important to counsel the patient and with a better prognosis.

Key words: Cerebellar mass, Intracranial tumor, Space-occupying lesion

A space-occupying lesion (SOL) generally occurs in the brain and can be caused by malignancy or other pathological features such as an abscess or hematoma. Almost half of the intracerebral tumors are primary, the rest have originated outside the central nervous system (CNS) and become metastases. The tumor effect may be local due to focal brain damage, and the presentation may give an indication of the location of the lesion but not its etiology [1]. Neoplasm may be benign or malignant and primary or metastatic. Non-neoplastic lesions include hematomas, and cerebral abscesses, including toxoplasmosis, colloid cysts, dermoid cysts, epidermoid cysts, etc. [2]. The annual incidence of CNS tumors ranges from 10 to 17 out of 100000 persons, and the cases are increasing gradually. Due to this, the CNS tumor becomes the second-commonest death from cancer under the age group of fifteen in both males and females [3]. Compared to other tumors, the disease's morbidity and mortality rate significantly affect death-adjusted life years despite its relatively uncommon nature. However, a patient's quality of life could be improved by an early diagnosis [4]. The symptoms generally include localizing signs, generalized signs, and false localizing signs, which include headache, increased intracranial pressure, blackout, personality and behavioral changes, nausea, vomiting, ataxia, epileptic seizures, etc. [1]. Compared to other tumors, the disease's morbidity and mortality rate significantly affect death-adjusted life years despite its relatively uncommon nature. However, a patient's quality of life may be enhanced by an early diagnosis [5].

In this case report, we shared the case of a 13-year-old girl who has cerebellar mass due to intracranial SOL (ICSOL) with a


history of tuberculosis. Through the case study, we hope to draw attention to how crucial an early diagnosis and timely intervention are to the effective care of such cases.

CASE REPORT

A 13-year-old female was admitted to the Apollo Hospital in the neurosurgery department on June 14, 2024, with the chief complaints of headaches and visual disturbances for the past 1 week and was diagnosed with cerebellar mass (? granulomatous lesion).

The patient had a history of tuberculosis and completed anti-tubercular treatment 5 years ago. On physical examination, the patient complained about severe headaches with papilledema. Furthermore, the patients also have a few episodes of vomiting. However, the patients do not have any ataxic gait and poor coordination. Further, assessment findings show that the patient was conscious and oriented to time, place, and person. She was attentive with intact memory, her cranial nerve was intact, and MRC was 5+ in all four limbs. Furthermore, the patient did not show any sign of a cerebellar or meningeal problem.

On arrival, routine laboratory tests were done along with thyroid function, where it was found that the thyroid stimulating hormone was 6.6 uIU/dL, creatinine was 0.7 mg/dL, glucose-plasma (random) was 95 mg/dL, serum protein was 7.2 mg/dL, total bilirubin was 7.2 mg/dL, gamma-glutamyl transferase was 75* U/L, serum glutamic pyruvic transaminase was 68 U/L, albumin was 38 g/dL, and globulin was 3.4 g/dL. Furthermore, the magnetic resonance imaging report shows the presence of a lobulated 30 × 28 mm ossified/calcified mass with surrounding

Access this article online	
Received - 17 August 2024 Initial Review - 18 August 2024 Accepted - 20 September 2024	Quick Response code 
DOI: ***	

Correspondence to: Rahul Shil, Associate Professor and Ph.D. Researcher, Department of MSN (Neuroscience), Sapthagiri NPS University, Bengaluru, Karnataka, India. E-mail: shil.rahul06@gmail.com

© 2024 Creative Commons Attribution-NonCommercial 4.0 International License (CC BY-NC-ND 4.0).

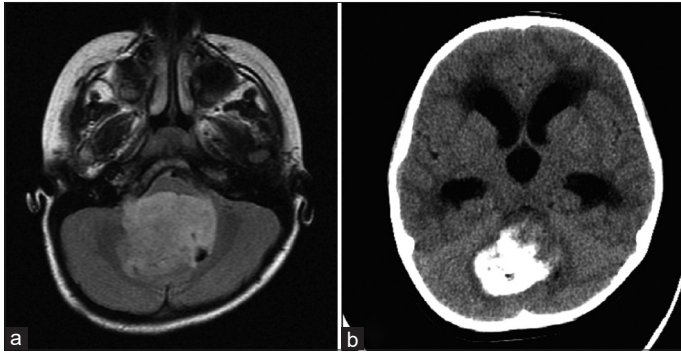


Figure 1: (a and b) Cerebellar tumor

gliosis on the right cerebellar ICSOL. The biopsy report shows hemorrhagic and fibrinous material with neutrophils, lymphocytes, and foci of calcification. There was no evidence of granuloma or neoplasia (Fig. 1). Moreover, due to the younger age, the patient was also referred to pediatric physicians. However, the interferon-gamma release assay test result shows positive, and the patient is most likely to have an *Mycobacterium tuberculosis* infection.

Due to the complexity of the problem, the patient had undergone sub-occipital craniotomy and decompression of posterior fossa SOL surgery under general anesthesia, and all the vitals were stable post-operatively, where her blood pressure was 110/70 mmHg, respiratory rate was 18 bpm, pain was 0/10, pulse rate was 70/min, and temperature was 97.6°F. Furthermore, the patient was prescribed injection mannitol 100 mL IV stat, injection kabilol 65 mL × SOS, injection levipil 500 mg IV × 12 hourly, injection pantoprazole 40 mg × OD, IVF-DNS/RL @ 90 mL/h, and injection PCM 75 mL × 8 hourly.

DISCUSSION

Malignancy is one of the most common causes of SOL that occurs in the brain in addition to infectious disease, hematoma, metabolic causes, tuberculosis, etc. [6]. Like in most of the previous cases, in our case also, the most prevalent sign was headache [7]. The prognosis of ICSOL is improving due to the advancement of the healthcare system. However, early and accurate diagnosis plays a major role in managing the condition and also in improving the quality of life [8].

Our report was similar to the study done in Bahrain [9,10]. A study done by Gotecha *et al.* [11] regarding the neuro-ophthalmic manifestation of ICSOL found that ophthalmic examination along with neurological examination is important to have a clear diagnosis. In our case, the patient underwent sub-occipital surgery and decompression of posterior fossa SOL surgery, and there was a gradual improvement in patient's condition postoperatively. From the postoperative ward, the patient was moved to the pediatric ward, and the Foley catheter was removed as the patient passed urine normally. Furthermore, the patient was able to walk out of bed normally. There was no sign of infection at the surgical site. However, the patient was advised to change the dressing every

alternative day to reduce the chance of infection. Along with dressing tablet ceftum 250 mg, 1 tablet BD after food × 5 days, syrup zincovit 10 mL OD after food × 1 month was advised, and the patient was asked to visit neuro outpatient department after 15 days and SOS in the case of any emergency. Following this, the patient was discharged from the hospital happily without having headaches or other complaints. After 4 days, the patient once again came to the emergency room for viral fever, which was managed by antibiotics and paracetamol.

CONCLUSION

Radiological investigation is the gold-standard diagnostic tool for ICSOL. The most common pathological feature of ICSOL is headache, which is sometimes unexplained. Therefore, most of the time, the patients usually go to neurologists. Hence, it is very important for physicians to do a detailed neurological examination of the patient to properly diagnose the condition and also to reduce the mortality rate.

REFERENCES

1. Space-Occupying Lesions of the Brain; 2022. Available from: <https://patient.info/doctor/space-occupying-lesions-of-the-brain> [Last accessed on 2024 Aug 17].
2. Soomro BA, Khalid S, Alvi S. Analytic study of clinical presentation of intracranial space-occupying lesions in adult patients. *Pak J Neurol Sci* 2014;9:2.
3. Hema NA, Ravindra RS, Karnappa AS. Morphological patterns of intracranial lesions in a tertiary care hospital in North Karnataka: A clinicopathological and immunohistochemical study. *J Clin Diagn Res* 2016;10:EC01-5.
4. Rure D, Kaithwas N, Kushwah SS, Mishra N, Mishra D, Shakya M. Psychiatric presentation in undiagnosed intracranial space-occupying lesions: A case series. *Ind Psychiatry J* 2023;32:S268-72.
5. Ludlam M, Birkett R, Jajawi S, Khurana R. Space-occupying lesion presenting with behavioural change symptoms. *Prog Neurol Psychiatry* 2020;24:11-3.
6. Sajjad A, Naroo G, Khan Z, Ali Z, Nasim B, Sheikh A, *et al.* Space occupying lesions (SOL) of the brain-clinical manifestation with subtle neurological symptoms in emergency department. *J Adv Med Med Res* 2018;26:1-8.
7. Kumari S, Kumar R. Imaging of intracranial space occupying lesions. *Int J Med Biomed Stud* 2021;5:106-8.
8. Lee WY, Tan WC, Tan YR, Tan HK. Congenital intracranial space occupying lesion: A case report. *Obstet Gynecol Int J* 2016;5:340-3.
9. AlHarmi RA, Henari DF, Jadah RH, AlKhayyat HM. A brain populated with space-occupying lesions: Identifying the culprit. *BMJ Case Rep* 2018;2018:bcr2018224286.
10. Datta A, Mukherjee N. Intracranial space-occupying lesion presenting as catatonia in a patient of affective disorder with a history of recurrent catatonic episodes: A case report. *Neuropsychiatr Invest* 2024;62:32-4.
11. Gotecha S, Kotecha M, Punia P, Chugh A, Shetty V. Neuro-ophthalmic manifestations of intracranial space occupying lesions in adults. *Beyoglu Eye J* 2022;7:304-12.

Funding: Nil; Conflicts of interest: Nil.

How to cite this article: Shil R, Mitri A. Intracranial space-occupying lesion (cerebellar mass): A case report. *Indian J Case Reports*. 2024; October 07 [Epub ahead of print].