

## Periventricular leukomalacia in a preterm neonate with early onset Capnocytophaga sepsis

Shrenik Vora, Pandian Panjangam, Victor Samuel Rajadurai

From, the Department of Neonatology, KK Women's and Children's Hospital, Singapore

**Correspondence to:** Dr. Shrenik Vora, Senior Staff Registrar, Department of Neonatology, KK Women's and Children's Hospital, 100, Bukit Timah Road, Singapore – 229899. E-mail: [dr\\_shrenikvora@yahoo.co.in](mailto:dr_shrenikvora@yahoo.co.in), [vora.shrenik@kkh.com.sg](mailto:vora.shrenik@kkh.com.sg).

Received: 22 June 2016

Initial Review: 03 July 2016

Accepted: 07 July 2016

Published Online: 16 July 2016

### ABSTRACT

*Capnocytophaga sputigena* is a slow-growing, capnophilic, gram negative, anaerobic, fusiform bacilli residing in oropharyngeal cavity of mammals. In humans, it causes localized periodontal infections and sporadic invasive infections in immunocompromised persons. Infrequently, it does cause chorioamnionitis and perinatal infections and is generally of lower morbidity risk in fetus and neonates. We describe a rare case report of early-onset neonatal Capnocytophaga sepsis with culture negative meningitis in preterm infant who developed early cystic periventricular leukomalacia in second week of life. Though neonatal Capnocytophaga infection is probably under-reported due to its fastidious nature and subclinical infection in mother, this case reminds that Capnocytophaga may be responsible for some occult cases of early neonatal septicemia, and that the organism may be more virulent in premature neonates with possibility of development of periventricular leukomalacia and neurological morbidities.

**Key words:** *Capnocytophaga species*, Neonatal Infection, Periventricular Leukomalacia

**C**apnocytophaga *Sputigena* is an opportunistic, slow-growing, facultative anaerobic, gram negative, fusiform bacilli, usually isolated from the mammalian oropharyngeal cavity and rarely residing in the genital tract. In humans, it causes localized periodontal infections, and sporadic invasive infections in immunocompromised persons and seldom a cause of early neonatal infections [1]. It is an infrequent cause of maternal chorioamnionitis and neonatal septicemia and is reported to be of a potential risk factor for preterm birth. Most cases of preterm labor caused by *Capnocytophaga* are probably not identified as the techniques to isolate them are not routinely performed and therefore, infection with *Capnocytophaga* is probably underestimated. Chorioamnionitis and perinatal infection with *Capnocytophaga* is generally of lower morbidity risk in

fetus and neonates. Literature review reveals that there are not many reports of severe neonatal infection or long term neurological morbidities caused by this organism [2].

We describe a case report of prenatally acquired neonatal *Capnocytophaga* sepsis with culture negative meningitis associated with development of early cystic periventricular leukomalacia (PVL), which has been reported rarely in literature.

### CASE REPORT

A 1.39 kg male infant was born at 32 weeks gestation via vaginal delivery to a 16-year-old single mother. Mother did not receive any prenatal care, antenatal steroids or antibiotics. The mother reported no history of fever, rash or foul smelling vaginal discharge during the pregnancy

and there was no evidence of clinical chorioamnionitis. She did not undergo any dental procedures during the pregnancy and her dental hygiene was good. There were no pets at her home and no history of animal bites or scratches. The mother started having labour pains at home, followed by rupture of membrane and delivery of baby.

Baby had spontaneous cry at birth, attended by paramedics and transferred to our hospital by 30 minutes of life. He required nasal continuous positive airway pressure support for 12 hours for respiratory distress. He did not receive any inotropic support and his clinical examination was unremarkable except mild respiratory distress. Chest X-ray was suggestive of mild respiratory distress syndrome.

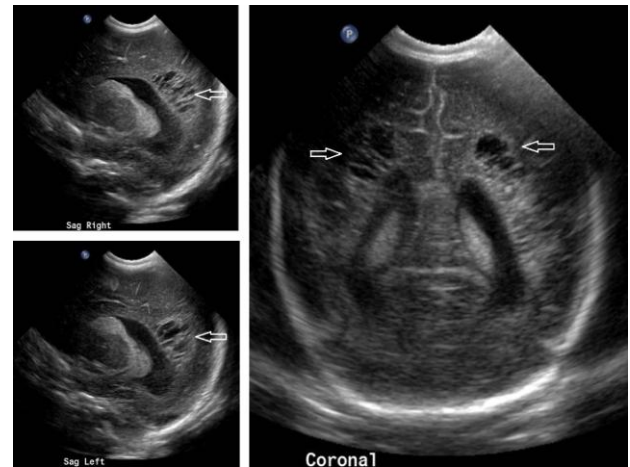
Initial laboratory investigations showed white blood cell count of  $2.5 \times 10^9/L$ , absolute neutrophil count of  $0.72 \times 10^9/L$  and C-reactive protein of  $9.2\text{mg/L}$ . Baby was started on first line antibiotics of intravenous penicillin and gentamicin after drawing blood for culture. Though, initial blood culture showed no bacterial growth at 48 hours, the anaerobic culture grew *Capnocytophaga Sputigena* on day 5. Antibiotic was changed to cefotaxime and it was continued for total 21 days. The lumbar puncture was suggestive of leukocytosis (WBC 60 cells/uL). CSF and repeat blood culture was negative. We were unable to perform maternal vaginal swab culture and placental histological examination.

Cranial ultrasound scan done on day 3 showed bilateral grade I intraventricular hemorrhage. Repeat scan done 2 weeks later showed cystic spaces in the periventricular white matter bilaterally, suggestive of periventricular leukomalacia (Fig.1). His metabolic screen, ophthalmological examination and hearing test were normal. After 4 weeks, the baby was discharged clinically stable and with a follow up appointment in outpatient clinic.

## DISCUSSION

*Capnocytophaga* is a genus of facultative anaerobic, capnophilic, fastidious, fusiform, non-spore-forming, gram-negative bacilli named for their characteristic of "consumption" of CO<sub>2</sub>. It is generally isolated from the oropharyngeal tract of mammals. In humans, it causes localized periodontal disease, sporadic invasive disease in immunocompromised persons and rarely neonatal infections [1].

*Capnocytophaga* organisms may reach the female genital tract either by ascending through the cervix following orogenital contact from a partner with periodontal disease or by haematogenous spread of bacteria from the bloodstream. In pregnant mothers, these bacteria can spread to placenta across the uterus and can cause chorioamnionitis. Occult or clinical chorioamnionitis may be responsible for preterm deliveries and spreading infection to fetus resulting in neonatal sepsis [3].



**Fig 1-Sagittal and coronal cranial ultrasound scans showing cystic periventricular leukomalacia (shown with arrows)**

Reports of *Capnocytophaga* infection in perinatal period are relatively rare. This is due to the fact that it mostly causes apparently silent subclinical chorioamnionitis in the mothers with prominent absence of clinical signs and symptoms [4]. Also cases of preterm labour due to *Capnocytophaga* infection may be missed as molecular technique (16S rRNA gene PCR and sequencing) used to identify these bacteria is not routinely performed, especially when the presentation of chorioamnionitis is clinically silent and asymptomatic [5].

Review of literature suggests that *Capnocytophaga* species can be responsible for early preterm labour and deliveries. In most of the published case reports, *Capnocytophaga* was cultured either from endometrium, amniotic fluid or newborn tracheal aspirate; and there are only five cases of blood culture proven severe neonatal *Capnocytophaga Sputigena* septicaemia reported so far [2,4]. In majority of the cases, *Capnocytophaga* sepsis has favorable outcome and rarely, it is responsible for severe neonatal infection or long term neurological morbidity

[6,7]. Of the reported studies, there is only one case report of *Capnocytophaga* sepsis developing cystic periventricular leukomalacia [8].

Hypothetically, *Capnocytophaga* species releases virulence factors consisting of enzymes like proteases and aminopeptidases which trigger the production of inflammatory cytokines. These inflammatory cytokines entering into blood stream leads to the development of chorioamnionitis, meningitis and PVL. PVL is a form of brain injury characterized by focal necrosis and gliosis of the periventricular white matter as a result of injury to oligodendrocyte progenitor cells. This insult is mediated by bacterial lipopolysaccharides recognized by Toll-like receptors (TLR) located on microglia. These activated microglial cells produces cytokines and reactive oxygen species which are toxic to immature oligodendrocytes causing PVL [9].

*Capnocytophaga* species are usually susceptible to macrolides, third-generation cephalosporins, carbapenems and fluoroquinolones. They are usually resistant to aminoglycosides, trimethoprim and metronidazole and some may produce  $\beta$ -lactamase which may be resistant to penicillins and first-generation cephalosporins [10].

In our case, mother probably had asymptomatic subclinical chorioamnionitis and she progressed to preterm labour. Baby developed neonatal septicemia with CSF pleocytosis which responded to cefotaxime. The favorable neonatal course indicates that the neonatal *Capnocytophaga* infection was not severe and prognosis was mostly related to early preterm birth. However, early development of PVL in our case leads to importance of serial neuroimaging and follow up neurodevelopmental assessment.

## CONCLUSION

The incidence of perinatal infections caused by *Capnocytophaga* species is often underestimated due to their fastidious growth and pleomorphic morphology. Clinicians should maintain a high index of suspicion of this organism as a possible cause of maternal subclinical chorioamnionitis, preterm labour and early onset neonatal sepsis. Lastly, serial neuroimaging studies and neurodevelopmental follow up of preterm infants with *Capnocytophaga Sputigena* is recommended to look for possibility of PVL and neurological morbidities.

## REFERENCES

1. Bonatti H, Rosboth DW, Nachbaur D, Fille M, Aspöck C, Hend I, et al. A series of infections due to *Capnocytophaga* spp in immunosuppressed and immunocompetent patients. Clin Microbiol Infect. 2003; 9: 380-7.
2. Lopez E, Raymond J, Patkai J, El Ayoub M, Schmitz T, Moriette G, et al. *Capnocytophaga* species and preterm birth: case series and review of the literature. Clin Microbiol Infect. 2010; 16: 1539-43.
3. Mikamo H, Kawazoe K, Sato Y, Izumi K, Tamaya T. Intra-amniotic infection caused by *Capnocytophaga* species. Infect Dis Obstet Gynecol. 1996; 4: 301-2.
4. Mekouar H, Voortman G, Bernard P, Hutchings G, Boeras A, Rodrigues-Villalobos H. *Capnocytophaga* species and perinatal infections: case report and review of the literature. Acta Clin Belg. 2012; 67: 42-45.
5. Gardella C, Riley DE, Hitti J, Agnew L, Kruger JN, Eschenbach D. Identification and sequencing of bacterial rDNAs in culture-negative amniotic fluid from women in premature labor. Am J Perinatol. 2004; 21: 319-323.
6. Chan E, Mildenhall L, Taylor S. A rare case of early-onset neonatal sepsis. JMM case reports 2014; DOI 10.1099/jmmcr.0.001099.
7. Howlett AA, Mailman TL, Ganapathy V. Early cystic lung disease in a premature neonate with perinatally acquired *Capnocytophaga*. J Perinatol 2007; 27: 68-70.
8. Bass WT, DeLoach D, Khan JH, Green GA, Cunnion KM. Severe cystic periventricular leukomalacia in a premature infant with *Capnocytophaga* sepsis. Am J Perinatol Rep. 2014; 4: e73-76.
9. Lehnardt S, Lachance C, Patrizi S. The toll-like receptor TLR4 is necessary for lipopolysaccharide-induced oligodendrocyte injury in the CNS. J Neurosci. 2002; 22 (7): 2478-86.
10. Douvier S, Nenwinth C, Fillipuzzi L, Kisterman JP. Chorioamnionitis with intact membranes caused by *Capnocytophaga sputigena*. Eur J Obstet Gynecol Reprod Biol. 1999; 83: 109-12.

**How to cite this article:** Vora S, Panjagam P, Rajadurai VS. Periventricular leukomalacia in a preterm neonate with early onset Capnocytophaga sepsis. Indian J Case Reports. 2016; 2(3): 50-52.

*Conflict of interest: None stated, Funding: Nil*