

## Septic shock secondary to febrile urinary tract infection in a case of long-standing phimosis: A novel presentation

Dhirenkumar Arvindbhai Shah<sup>1</sup>, Shreya Poshia<sup>2</sup>, Anjani Gohil<sup>2</sup>

From <sup>1</sup>Full Time Surgeon; GMS Class - 1, Department of Surgical, J.Z.M.&N. Civil Hospital Nadiad, Nadiad, <sup>2</sup>2<sup>nd</sup> Year Resident, Department of General Surgery, Pramukh Swami Medical College, Anand, Gujarat, India

### ABSTRACT

A case report of a 75-year-old Hindu, Indian old male presenting with septic shock and recurrent episodes of urinary tract infection (UTI). The patient had long-standing phimosis and balanitis for which emergency circumcision was done. This case illustrates how lack of education, poor personal hygiene, and access to basic surgical care for an easily treatable condition leads to advanced presentation of a severe disease process. The patient's main concerns were recurrent UTI and the inability to retract the foreskin. The final diagnosis of urosepsis secondary to long-standing Phimosis was made. The patient was managed for urosepsis with intravenous antibiotics followed by circumcision. The patient had immediate relief of symptoms and urosepsis was managed well with no further episodes of UTI. This case illustrates how timely intervention could save a patient from life-threatening conditions such as urosepsis.

**Key words:** Case report, Circumcision, Febrile urinary tract infection, Phimosis, Septic shock

Phimosis, whether congenital or acquired, is a condition in the penis characterized by natural balanopreputial adhesions, excess foreskin, and various degrees of constriction in its opening, which prevent the total or partial exteriorization of the glans [1]. Urinary tract infections (UTIs) are among the most frequent bacterial infections in older adults. After the age of 50 years, their incidence progressively increases. The category of adult male UTIs includes cases such as prostatitis, epididymitis, orchitis, pyelonephritis, cystitis, urethritis, and infected urinary catheters. Due to the male's urinary tract defense system, infections are usually associated with anatomic abnormalities, which often require surgical correction. Uroseptic shock is defined as sepsis-induced hypotension (systolic blood pressure [SBP] <90 mmHg or mean arterial pressure <70 mmHg or a decrease in SBP by >40 mmHg lasting for at least 1 h, despite adequate fluid resuscitation and in the absence of other cause of hypotension) [2].

This case mainly highlights the need to spread awareness about maintaining basic personal hygiene and to seek medical attention as soon as possible in case a need arises and how a basic procedure such as circumcision brought back the patient from a fatal condition such as septic shock.

### CASE REPORT


A 75-year-old Hindu, Indian male presented to the emergency department with complaints of high-grade fever and loss of consciousness. The patient also complained of recurrent UTI which was later on identified to be due to the presence of phimosis. The patient is a known case of Parkinsonism, Alzheimer's disease, and Hypertension.

On presentation, vitals were temperature 101.4° Fahrenheit, oxygen saturation 90% on room air, blood pressure 80/60 mmHg, pulse rate 130/min, and respiratory rate 28/min. On examination, the abdomen was distended; the patient had altered sensorium and difficulty in breathing. Bilateral lower zone crepitations were present on auscultation. The patient had a urine output of 200 mL since morning. While catheterization, severe phimosis with balanitis was noted. The patient had a pin-point preputial opening which was widened using artery forceps following which per-urethral Foley's catheter was inserted (Fig. 1).

Laboratory analysis revealed pus cells, red blood cells, and the presence of albumin in urine routine examination. Hemoglobin-13.2 g/dL, total leucocyte count- $17.8 \times 10^3/\mu\text{L}$ , Platelets- $1.94 \times 10^3/\mu\text{L}$ , S. Creatinine-3.4 mg/dL, erythrocyte sedimentation rate-20 mm/h, S. Urea-77 mg/dL, S.Na+

**Correspondence to:** Dhirenkumar Arvindbhai Shah, 2<sup>nd</sup> Year Resident, Department of General Surgery, Pramukh Swami Medical College, Nadiad, Gujarat, India. E-mail: shrposhiya3@gmail.com/Anjani/ Anjani Gohil, 2<sup>nd</sup> Year Resident, Department of General Surgery, Pramukh Swami Medical College, Nadiad, Gujarat, India. E-mail: anjani.gohil@yahoo.com

© 2024 Creative Commons Attribution-NonCommercial 4.0 International License (CC BY-NC-ND 4.0).

Access this article online	
Received - 01 August 2024 Initial Review - 12 September 2024 Accepted - 05 October 2024	Quick Response code 
DOI: ***	

125 mEq/L, S. Potassium 2.9 mEq/L, and C- Reactive Protein 76.8 mg/dL.

The patient was investigated radiologically. Ultrasonography revealed prostatomegaly; contrast-enhanced computed tomography (CT) scan of the abdomen plus pelvis revealed paralytic ileus with prostatomegaly (79 cc volume). CT thorax revealed bilateral basal atelectasis; magnetic resonance imaging of brain plus head and neck angiography revealed no significant abnormality, and Electroencephalography was noted to be normal. The patient had urosepsis along with electrolyte imbalance and phimosis. The final diagnosis was septic shock secondary to long-standing phimosis.

Antibiotics, analgesics, and IV Fluids were given for primary stabilization of the patient in view of septic shock. After stabilizing the patient, emergency circumcision was done which improved the general condition of the patient and the laboratory investigations returned to normal levels. Following circumcision, the per-urethral catheter was removed and an urodynamics study was attempted but the patient was unable to void, thus per-urethral catheter was re-inserted. After 2 weeks, a successful transurethral resection of the prostate was done. The patient was voiding urine, has no further UTI episodes, and is clinically well. Fig. 2 shows the timeline of the patient. As this was a case of long-standing phimosis, if the patient had been well educated beforehand, he would have been operated on for phimosis at an early age thus preventing recurrent episodes of balanitis and UTI.

**DISCUSSION**

Phimosis is a condition in which inflammation and scarring of the foreskin leads to a permanently un-retractable prepuce that cannot be drawn back to reveal the glans penis (Fig. 3). Narrowing of the foreskin orifice may compress the meatus, causing high-pressure flow that leads to inflammation of the periurethral tissues; in some cases, phimosis may lead to complete urethral

obstruction. Obstruction, inflammation, and penile edema may create an ischemic process prone to infection [3] Circumcision is sometimes undertaken to cure existing pathological conditions, sometimes to prevent various diseases from occurring at a much later date [4].

Kayaba *et al.* analyzed the degree of retractability of the foreskin and categorized it as follows: Type I: the total absence of preputial retraction; Type II: Exposure only of the external urethral meatus; Type III (intermediate): Partial retraction with exposure from the apex to the middle of the glans; Type IV: Exposure to above the crown of the glans with the presence of adhesions with the foreskin; and Type V: Exposure of the entire glans after retraction [5]. A study has been done which reported that before circumcision, the majority of the boys harbored uropathogenic organisms (*Escherichia coli* and other coliforms, *Enterococcus* spp., *Proteus* spp., *Pseudomonas* spp., and *Klebsiella* spp.) and after circumcision, none of the boys had uropathogens, the only organisms cultured from the periurethral region being skin commensals. We postulate that circumcision converts a “cul-de-sac” that is a reservoir of organisms capable of causing ascending UTI into a surface colonized by natural skin organisms. This study provides circumstantial evidence supporting the idea that circumcision in well-selected patients may confer protection from urine infection [6].

UTI is considered one of the most prevalent infections that may lead to many renal complications. UTI is one of the most prevalent and serious infections worldwide, with more than 150 million new cases reported each year. It affects the urinary tract and prostate, causing significant complications and major health problems such as urinary tract dysfunction, bacterial septicemia, or even prominent kidney damage [7]. A UTI is generally treated with antibiotics. However, if the infection is not identified and is left untreated, it can move to the kidneys and ureters and may cause sepsis and septic shock. UTI is an inflammation of the urinary tract caused by abnormal colonization of harmful microorganisms. Normally, the urinary tract is free from any microorganisms, as it resists long-term colonization via different mechanisms. The protective mechanisms can be either mechanical (e.g., bladder emptying during micturition that washes off any residing microorganism) or physiological (e.g., host immunity, mucus production, and increased urea production). However, the inflammation disrupts the normal urinary tract function, which leads to incomplete microorganism clearance and eventually UTI development (Fig. 4). Nevertheless, acquiring the infection depends on several risk factors such as age, sex, period of hospitalization, pregnancy, diabetes, usage

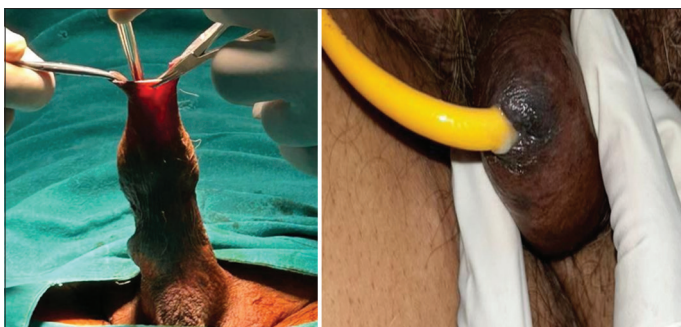


Figure 1: Insertion of per-urethral Foley’s catheter

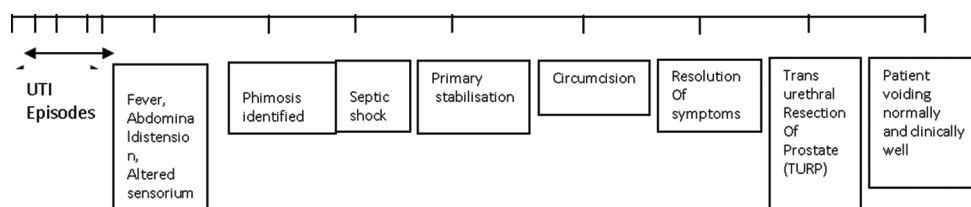


Figure 2: The timeline of the patient

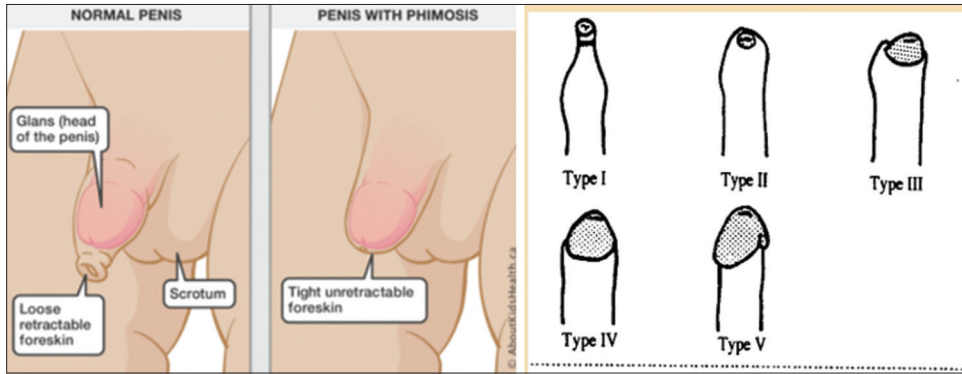


Figure 3: Phimosis leading to permanently un-retractable prepuce that cannot be drawn back to reveal the glans penis

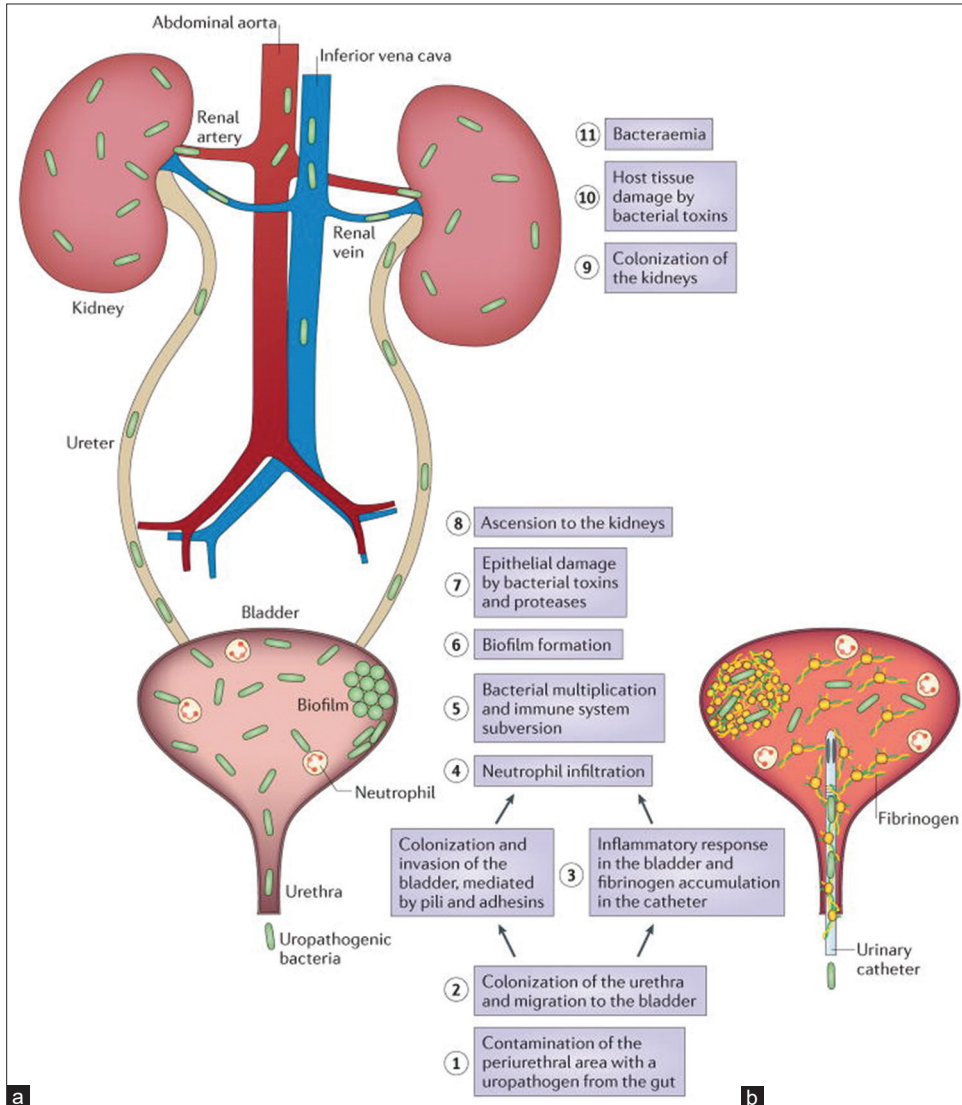


Figure 4: (a and b) Inflammation disrupting the normal urinary tract function, which leads to incomplete microorganism clearance and eventually urinary tract infection development

of urinary catheters, and genitourinary tract or immune system abnormalities [8]. Several microorganisms are commonly involved in UTI, including bacteria, fungi, and viruses. The most frequently identified uropathogen is *E. coli*. However, other uropathogens, including *Klebsiella* spp., *Staphylococcus* spp., *Streptococcus* spp., *Proteus* spp., and *Pseudomonas* spp., may also be involved in UTI development [9].

Normal voiding and maintaining personal hygiene are the most important defenses against UTI. Increased post-void residual volume, which occurs in aging males mainly related to Benign Prostatic Hyperplasia (BPH), causes urinary stasis and predisposes them to UTI. Urinary tract abnormalities and IUC are additional contributors to UTI in geriatric patients [10].

Once a febrile UTI is diagnosed, an empirical antimicrobial treatment has to be started to avoid progression to sepsis or even septic shock. Sepsis can occur as a complication of a UTI, caused by bacteria entering the urinary tract and causing an infection. If the bacteria from the UTI enters the bloodstream, it can lead to sepsis. Symptoms of sepsis may include fever, tachycardia, altered sensorium, and difficulty breathing. Preventive measures, such as maintaining good hygiene, drinking plenty of fluids, and avoiding the use of unnecessary catheters, can help reduce the risk of UTIs and ultimately lower the risk of developing sepsis. Sepsis is the body's extreme reaction to infection. The body attacks its organs and tissues, leading to tissue damage, organ failure, and death. Sepsis that results from an untreated UTI is generally called urosepsis. Urosepsis is a serious complication of a UTI and should be treated as a medical emergency.

Several genitourinary abnormalities may be associated with urosepsis. The most common determinant of urosepsis is obstruction to free flow of urine which may quickly lead to severe sepsis. Various structural and functional abnormalities of the genitourinary tract associated with urosepsis have been mentioned below. Urodynamics is extremely helpful in assessing bladder and urethral function. The urodynamic assessment should include bladder sensation (first sensation of filling), bladder compliance during filling, voluntary detrusor pressure, involuntary detrusor contractions, maximum bladder capacity, a pressure-flow study, and sphincteric function during filling and voiding.

The surviving sepsis campaign (SSC) aims to reduce sepsis mortality, and along with new definitions, the guidelines for the management of sepsis and septic shock were updated in 2016. Upon initial clinical suspicion of sepsis, SSC guidelines recommend initial fluid resuscitation with at least 30 mL/kg of I.V. crystalloid fluid given within the first 3 h. Ongoing reevaluation including a clinical examination of physiologic variables (such as temperature, heart rate, respiratory rate, BP, arterial oxygen saturation, and urine output) remains key in assessing response to therapy. Aggressive fluid resuscitation can help restore hemodynamics and increase oxygen delivery to tissues in patients with sepsis [11].

Basic prompt intervention such as circumcision could prevent fatal complications such as septic shock or even death. Minor procedures such as circumcision can prevent dreaded complications such as septic shock. Preventive measures, such as maintaining good hygiene, drinking plenty of fluids, and avoiding the use of unnecessary catheters, can help reduce the risk of UTIs and ultimately lower the risk of developing sepsis. Based on the strong evidence, male circumcision substantially reduces the risk of UTI. The benefits of male circumcision are even greater when one considers that over their lifetime; approximately half of uncircumcised boys will suffer a medical condition caused by the retention of foreskin.

## CONCLUSION

Our interest mainly lies in spreading health education about maintaining personal hygiene and awareness regarding undergoing circumcision at an early age, in case the need arises to

prevent any life-threatening complications. Maintaining personal hygiene can prevent recurrent balanitis, recurrent UTIs, and sexually transmitted diseases.

## PATIENT'S PERSPECTIVES

I am very happy that how well and quickly these doctors managed my condition and after a series of investigations and two operations, I am finally able to void without any difficulty and I have learnt the lesson how lack my awareness and education led me to dangerous condition landing me into hospitalization. I will encourage my kids, neighbors, friends, and family members to maintain proper personal hygiene and seek medical assistance for the same to prevent any serious complications in life.

I give my consent to present this case report so that I could contribute to the noble cause in spreading awareness about education and hygiene along with these doctors.

## ACKNOWLEDGMENT

I would like to thank Almighty, Parents, My colleagues, My Staff and My Juniors for the constant support and help. This would not have been possible without their help.

## REFERENCES

1. Kanematsu A. Management of phimosis as a risk factor of urinary tract infection: An Asian perspective. *Urol Sci* 2016;27:190-2.
2. Dellinger RP, Levy MM, Rhodes A, Annane D, Gerlach H, Opal SM, *et al.* Surviving sepsis campaign: International guidelines for management of severe sepsis and septic shock: 2012. *Crit Care Med* 2013;41:580-637.
3. Ward L, Eisenson D, Fils JL. Fournier's gangrene of the penis in a 12-year-old patient secondary to phimosis. *R I Med J* (2013) 2016;99:45-6.
4. Gairdner D. The fate of the foreskin, a study of circumcision. *Br Med J* 1949;2:1433-7.
5. Kayaba H, Tamura H, Kitajima S, Fujiwara Y, Kato T, Kato T. Analysis of shape and retractability of the prepuce in 603 Japanese boys. *J Urol* 1996;156:1813-15.
6. Wijesinha SS, Atkins BL, Dudley NE, Tam PK. Does circumcision alter the periurethral bacterial flora? *Pediatr Surg Int* 1998;13:146-8.
7. Almutawif YA, Eid HM. Prevalence and antimicrobial susceptibility pattern of bacterial uropathogens among adult patients in Madinah, Saudi Arabia. *BMC Infect Dis* 2023;23:582.
8. Rowe TA, Juthani-Mehta M. Diagnosis and management of urinary tract infection in older adults. *Infect Dis Clin North Am* 2014;28:75-89.
9. Terlizzi ME, Gribaudo G, Maffei ME. UroPathogenic *Escherichia coli* (UPEC) infections: Virulence factors, bladder responses, antibiotic, and non-antibiotic antimicrobial strategies. *Front Microbiol* 2017;8:1566.
10. Nicolle LE. Urinary tract pathogens in complicated infection and in elderly individuals. *J Infect Dis* 2001;183 Suppl 1:S5-8.
11. Rhodes A, Evans LE, Alhazzani W, Levy MM, Antonelli M, Ferrer R, *et al.* Surviving sepsis campaign: International guidelines for management of sepsis and septic shock: 2016. *Intensive Care Med* 2017;43:304-77.

*Funding: Nil; Conflicts of interest: Nil.*

**How to cite this article:** Shah DK, Poshia SM, Gohil AA. Septic shock secondary to febrile urinary tract infection in a case of long-standing phimosis: A novel presentation. *Indian J Case Reports*. 2024; October 07 [Epub ahead of print].