

## Primary Ewing Sarcoma of Kidney in an Adult: An Oddball

Nidhi Mahajan<sup>1</sup>, Neelakshi Mahanta<sup>2</sup>, Arpita Ray<sup>3</sup>, Mandakinee Phukan<sup>4</sup>, Naveen Saini<sup>5</sup>

From <sup>1</sup>Fellow, <sup>2</sup>Professor and Head, <sup>3</sup>Assistant Professor, Department of Medical Oncology, <sup>4</sup>Assistant Professor, Department of Nuclear Medicine, <sup>5</sup>Mch Resident, Department of Surgical Oncology, State Cancer Institute, Guwahati, Assam, India

### ABSTRACT

Ewing sarcoma (ES) is a malignant bone and soft-tissue tumor derived from neuroectoderm. It occurs, mostly, in pediatric adolescents with the histopathological features of invasiveness. The occurrence of ES of the kidney is rare, comprising only 1% of all renal tumors which are limited to case reports and small case series. Herein, we report a case of a 44-year-old male patient, presenting with the right flank pain and hematuria. Computed tomography scan demonstrated a right midpolar exophytic renal mass with intraluminal right renal vein and inferior vena cava (IVC) thrombus without visceral metastasis suggesting the diagnosis of renal cell carcinoma (T3BN0M0). The patient underwent the right radical nephrectomy with IVC thrombectomy. In view of the aggressiveness of the tumor, the patient received adjuvant chemotherapy (i.e., four cycles of vincristine, adriamycin, and cyclophosphamide alternating every 3 weeks with four cycles of ifosphamide and etoposide). The patient had near-complete resolution of the tumor with no thrombus seen in the follow-up scan. We could not complete six cycles of chemotherapy which were planned initially due to recurrent cytopenias. Six months post-chemotherapy, the patient is clinically and radiologically disease-free and is in close follow-up. We are reporting this case to highlight the rarity of this entity and its challenging clinicopathological diagnosis when presenting as a renal tumor.

**Key words:** Adjuvant chemotherapy, Ewing sarcoma, Radical nephrectomy

The term Ewing sarcoma (ES) is based on nomenclature from the World Health Organization pathology classification system. Several terms previously used to describe ES include the ES family of tumors, peripheral primitive neuroectodermal tumor (PNET), peripheral neuroepithelioma, and small cell tumors of the chest wall (Askin tumor) [1]. ES of kidney (ESK) is a rare neoplasm, typically presenting with irradiating flank pain that mimics the pain associated with kidney stones. Total surgical resection is considered as the treatment of choice for these tumors. However, chemotherapy in an adjuvant setting has also shown promising results [1,2].

Herein, we report a case of a 44-year-old male diagnosed with ESK. After nephrectomy, a significant response to multi-agent chemotherapy was observed.

### CASE PRESENTATION

A 44-year-old diabetic and hypertensive male presented with complaints of hematuria for 20 days associated with colicky pain in the right flank region (on and off), radiating to the back. Pain is deep-seated, poorly localized, not aggravated by any factors,

and relieved by medications. He had no significant prior family history.


On physical examination, the abdomen was tender with no palpable mass in the abdomen.

His laboratory investigations revealed a raised serum creatinine of 1.3 mg/dL (normal range: 0.6–1.2) and elevated serum potassium of 5.5 mEq/L (normal range: 3.5–5) with no growth on urine culture. He underwent sonography followed by a computed tomography (CT) scan, which revealed a large well-defined heterogeneously enhancing mass lesion (7.54 × 5.5 × 6.1 cm) with exophytic component (5.68 × 5.68 cm) involving anterior and lateral cortex extending into medulla with a non-enhancing lesion suggestive of cystic component/necrosis. Investigations suggested the diagnosis of renal cell carcinoma (RCC). Intraluminal thrombus is seen within the right renal vein and inferior vena cava (IVC).

The patient underwent a right radical nephrectomy and IVC thrombectomy (Figs. 1 and 2).

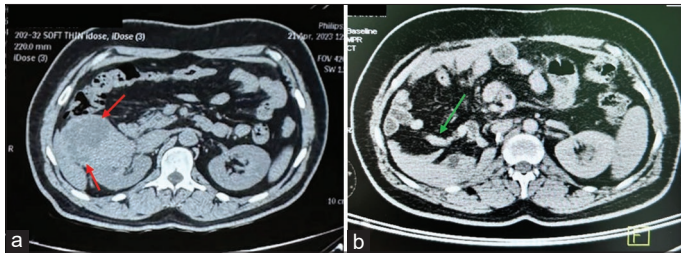
On gross examination, the right kidney measures 11 × 8 × 7 cm. The cut section shows an ill-defined tumor involving the mid-polar region and renal pelvis measuring 7 cm in maximum dimension. The cut surface of the tumor is gray-white and firm and shows areas of hemorrhage and focal cystic change.

Histopathology revealed a neoplastic lesion with a lobular pattern of growth composed of small round cells arranged in

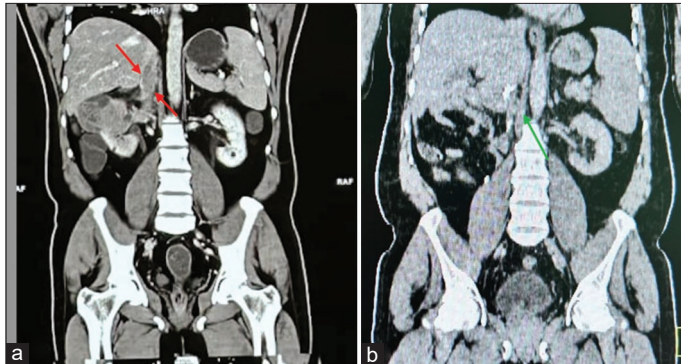
Access this article online	
Received - 10 July 2024 Initial Review - 22 July 2024 Accepted - 21 August 2024	Quick Response code 
DOI: ***	

**Correspondence to:** Dr. Nidhi Mahajan, #801, 8<sup>th</sup> floor, Dona Tower, D Neog Path, Guwahati -781005, Assam, India. E-mail: drnidhimahajan11@gmail.com

© 2024 Creative Commons Attribution-NonCommercial 4.0 International License (CC BY-NC-ND 4.0).



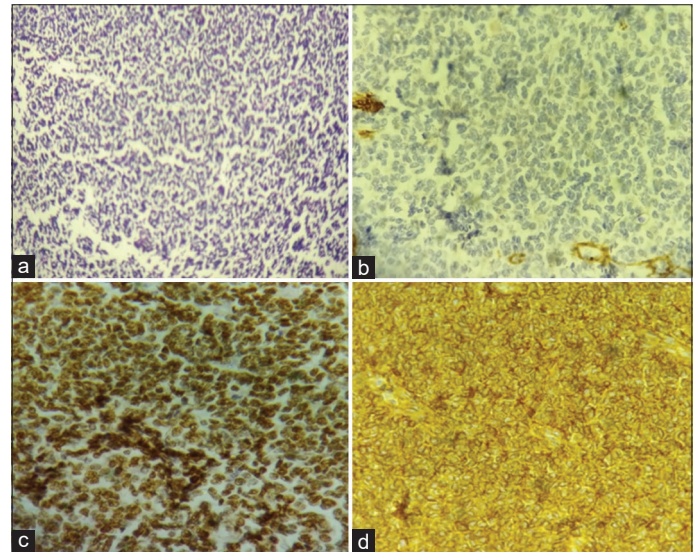
**Figure 1:** Illustrative axial computed tomography (CT) scan images of whole abdomen (a) CT scan done before surgery showing the ESK tumor (red arrows); a large heterogeneously enhancing mass (7.54 × 5.5 × 6.1 cm) involving the right kidney. (b) Post right nephrectomy, inferior vena cava thrombectomy, and post-chemotherapy images with no CT abnormality (green arrow).



**Figure 2:** Coronal computed tomography images of the patient (a) before radical nephrectomy, image showing inferior vena cava (IVC) thrombus (red arrows) and (b) post right radical nephrectomy, IVC thrombectomy, and post-chemotherapy images with no IVC thrombus (green arrow)

sheets. The tumor cells have rounded to oval nuclei, finely granular chromatin, inconspicuous nucleoli, and pale-to-clear scanty cytoplasm. Occasional mitotic figures are seen. No blastemal or mesenchymal component was identified. Tumor involves renal pelvis and sinus fat. The right renal vein shows a luminal thrombus with tumor fragments. The ureter is free of tumor. The rest of the kidney was within normal limits. The immunohistochemical staining pattern in tumor cells was as follows: Positive for CD99 and NKX2.2 and negative for CK and WT1 (Fig. 3). All these findings were consistent with ESK.

Postsurgery, the patient was treated with multi-agent chemotherapy in view of aggressiveness of the disease: Vincristine (1.5 mg/m<sup>2</sup>), adriamycin (50 mg/m<sup>2</sup>), and cyclophosphamide (1200 mg/m<sup>2</sup>) every 3 weekly, alternated by etoposide (100 mg/m<sup>2</sup>) and ifosfamide (1800 mg/m<sup>2</sup>) for total of four cycles (the patient was initially planned for total of six cycles of chemotherapy). The toxicity of chemotherapy was evaluated after every cycle, and hence, adjuvant chemotherapy was stopped early due to recurrent cytopenias. Post-chemotherapy scan showed low-grade metabolism at the surgical stapled site in the post-operative bed with no CT detectable abnormality which could represent inflammatory changes. At 6 months post-chemotherapy, the patient was clinically and radiologically disease-free and was in close follow-up.



**Figure 3:** (a) The tumor shows a solid and diffuse growth pattern arranged in sheets, nests, and trabeculae (hematoxylin and eosin (H and E) stain, ×4 magnification), (b) this section shows the typical small round blue cell morphology (H and E stain, ×40 magnification), (c) immunohistochemistry (IHC) image, NKX 2.2 positive, and (d) IHC image, CD99 positive

## DISCUSSION

ES was initially described by Seemayer *et al.* in 1975. Since the first description of renal ES in 1994, only 150 cases of renal ES/PNET have been reported in the literature. ESK usually affects young adults aged 30.4 years on average at diagnosis. Approximately, 60% of those affected are male. The patient's signs and symptoms mimic that of kidney stones including flank pain (84%), palpable neoplasm (60%), and hematuria (38%) [3]. Ellinger *et al.* reported that in one case series of 52 patients with renal ES/PNET, the average age for those affected was 26, with 38% of all patients with the tumor between the ages of 4 and 69 [4].

No specific imaging features are seen radiologically and it is impossible to differentiate renal Ewing's from much more prevalent RCC by imaging alone. Usually, ultrasound shows an ill-defined hypo to isoechoic mass lesion, with minimal or no internal vascularity. Contrast-enhanced CT shows a hypo-dense and hypo-enhancing mass (as compared to the normal renal parenchyma). They usually do not cross the midline but have a strong tendency to extend into perinephric and renal sinus fat, cause lymphovascular invasion, and distant metastases to lungs and bones, similar to RCC [5]. On imaging of the mass, differential diagnosis of solid, aggressive, and primary renal tumor includes RCC, transitional cell carcinoma, lymphoma, and other mesenchymal malignancies such as osteosarcoma, rhabdomyosarcoma, and leiomyosarcoma [6].

On gross examination, renal ES presents as grayish-white tumors with variable areas of hemorrhage and necrosis. Microscopically, most cases are composed of uniform small round cells with round nuclei, finely stippled chromatin, inconspicuous nucleoli, scant clear cytoplasm, and indistinct

cytoplasmic membranes. Homer wright rosettes are common in ESK, confirming their neuroectodermal differentiation [7].

Immunohistochemistry plays a pivotal role in the diagnosis of ESK, as new markers have improved diagnostic accuracy, including NKX2.2. NKX2.2 is a protein that regulates the expression of genes involved in the neuroendocrine/glial differentiation pathway. NKX2.2 is a specific marker targeting the fusion protein EWS-FLI-1. It shows a high sensitivity of 93% and a specificity of 89% [8]. CD99 and FLI-1 are commonly used for ES, though there is on-going discussion about their precision.

The most frequent translocation in ESK is t(11,22) (q24;q12), which results in the EWSR1-FLI1 fusion transcript which is seen in almost 85% of cases. The second most common translocation is t(21,22) (q22;q12), which results in EWSR1-ERG in ~10% of cases. Fluorescent in situ hybridization is the gold standard method with high sensitivity (92.3%) and specificity (100%) [9].

There is no consensus on treatment for renal ES due to its rarity. The treatment is extrapolated from the treatment of osseous ES. Typically, radical nephrectomy followed by adjuvant chemotherapy is considered as the principal management for ESK. Surgical intervention may incorporate with cavotomy in the presence of venous tumor thrombus, which was frequently reported in ESK and was stated to be associated with the presence of pulmonary metastasis [10]. Tarek *et al.* reported that lesions confined to the kidney, treated with a nephrectomy and adjuvant chemotherapy had favorable outcomes, and that in cases with a rapidly growing tumor, immediate surgery before a biopsy may provide a better outcome [11].

ESK has been speculated as relatively sensitive to chemotherapy. In particular, initially, vincristine, actinomycin, and cyclophosphamide were found effective in treating ESK. Later, doxorubicin, ifosfamide, and etoposide also demonstrated activity toward these tumors. In particular, the European Ewing tumor working initiative of national groups 1999 (EURO-EWING 99) protocol prescribes six courses of chemotherapy (i.e., vincristine, ifosfamide, doxorubicin, and etoposide) for ES tumors [12]. Adjuvant radiotherapy can be offered in certain cases such as – incomplete resection, positive resection margins, or recurrence [3].

The largest meta-analysis including 116 cases of renal ES suggested a 5-year disease-free survival rate of 45–55% [13]. In metastatic cases, molecular-targeted therapy including insulin-like growth factor 1 receptor antibody has shown some promise in ESK. In addition, the newly approved anti-tumor agents, such as the antiangiogenic drug apatinib, were claimed to serve as one of the therapeutic options for ESK [14]. Despite the improved prognosis of this tumor by surgery and adjuvant therapy, optimized and potent therapeutic regimes are still urgently needed.

## CONCLUSION

Primary renal ES is a very rare but aggressive renal tumor. It has no specific imaging features which can distinguish it from RCC, and hence, a possibility of ES should always be kept as a differential

diagnosis in aggressive renal tumors in young adults. In patients with localized disease, complete surgical resection and adjuvant chemotherapy could provide long-term disease-free survival. Local tumor extension beyond the kidney, tumor thrombus, and distant metastasis are unfavorable prognostic factors. The prognosis of patients with metastases is poor. The 5-year overall survival of localized disease and metastatic disease is 61 months and 14 months, respectively. More studies are needed to establish treatment protocols that can reduce recurrence rates and improve patient survival.

## ACKNOWLEDGMENT

We would like to thank Dr. Reshma Nanavati for providing the pathology images for this case report.

## AUTHORS' CONTRIBUTORS

The authors confirm contribution to the case report as follows: Study conception and design: Nidhi Mahajan, Neelakshi Mahanta, Arpita Ray. Draft manuscript preparation: Nidhi Mahajan, Naveen Saini. Search for literature: Nidhi Mahajan, Naveen Saini. Analysis and interpretation of results: Nidhi Mahajan, Neelakshi Mahanta, Arpita Ray. Sourcing of images: Nidhi Mahajan, Mandakinee Phukan. All authors reviewed the results and approved the final version of the manuscript.

## REFERENCES

1. Choudhury AR, Jain SG, Reghunath A, Ghasi RG, Kaur N, Kolte S. Primary Ewing's sarcoma of the kidney: A rare masquerader of renal cell carcinoma on imaging. *Egypt J Radiol Nucl Med* 2022;53:53.
2. Sadiq M, Ahmad I, Shuja J, Ahmad K. Primary Ewing sarcoma of the kidney: A case report and treatment review. *CEN Case Rep* 2017;6:132-5.
3. Hakky TS, Gonzalvo AA, Lockhart JL, Rodriguez AR. Primary Ewing sarcoma of the kidney: A symptomatic presentation and review of the literature. *Ther Adv Urol* 2013;5:153-9.
4. Ellinger J, Bastian PJ, Hauser S, Biermann K, Müller SC. Primitive neuroectodermal tumor: Rare, highly aggressive differential diagnosis in urologic malignancies. *Urology* 2006;68:257-62.
5. Rowe RG, Thomas DG, Schuetz SM, Hafez KS, Lawlor ER, Chugh R. Ewing sarcoma of the kidney: Case series and literature review of an often overlooked entity in the diagnosis of primary renal tumors. *Urology* 2013;81:347-53.
6. Katabathina VS, Vikram R, Nagar AM, Tamboli P, Menias CO, Prasad SR. Mesenchymal neoplasms of the kidney in adults: Imaging spectrum with radiologic-pathologic correlation. *Radiographics* 2010;30:1525-40.
7. Song HC, Sun N, Zhang WP, Huang CR. Primary Ewing's sarcoma/primitive neuroectodermal tumor of the urogenital tract in children. *Chin Med J (Engl)* 2012;125:932-6.
8. Yoshida A, Sekine S, Tsuta K, Fukayama M, Furuta K, Tsuda H. NKX2.2 is a useful immunohistochemical marker for Ewing sarcoma. *Am J Surg Pathol* 2012;36:993-9.
9. Rekhi B, Vogel U, Basak R, Desai SB, Jambhekar NA. Clinicopathological and molecular spectrum of Ewing sarcomas/PNETs, including validation of EWSR1 rearrangement by conventional and array FISH technique in certain cases. *Pathol Oncol Res* 2014;20:503-16.
10. Fergany AF, Dhar N, Budd GT, Skacel M, Garcia J. Primary extrasosseous Ewing sarcoma of the kidney with level III inferior vena cava thrombus. *Clin Genitourin Cancer* 2009;7:E95-7.
11. Tarek N, Said R, Andersen CR, Suki TS, Foglesong J, Herzog CE, *et al.* Primary ewing sarcoma/primitive neuroectodermal tumor of the kidney: The

- MD Anderson cancer center experience. *Cancers (Basel)* 2020;12:2927.
12. Grier HE, Krailo MD, Tarbell NJ, Link MP, Fryer CJ, Pritchard DJ, *et al.* Addition of ifosfamide and etoposide to standard chemotherapy for Ewing's sarcoma and primitive neuroectodermal tumor of bone. *New Engl J Med* 2003;348:694-701.
  13. Risi E, Iacovelli R, Altavilla A, Alesini D, Palazzo A, Mosillo C, *et al.* Clinical and pathological features of primary neuroectodermal tumor/Ewing sarcoma of the kidney. *Urology* 2013;82:382-6.
  14. Javery O, Krajewski K, O'Regan K, Kis B, Giardino A, Jagannathan J, *et al.* A to Z of extraskeletal Ewing sarcoma family of tumors in adults: Imaging

features of primary disease, metastatic patterns, and treatment responses. *AJR Am J Roentgenol* 2011;197:W1015-22.

*Funding: Nil; Conflicts of interest: Nil.*

**How to cite this article:** Mahajan N, Mahanta N, Ray A, Phukan M, Saini N. Primary Ewing sarcoma of kidney in an adult: An oddball. *Indian J Case Reports*. 2024; August 29 [Epub ahead of print].