

## Dental Management of Ectodermal dysplasia: A case report

Baljeet Singh<sup>1</sup>, Harpreet Kaur<sup>2</sup>, Bharat Joshi<sup>3</sup>, Sudan Sahira<sup>4</sup>

From, 1 Professor & Head, Department of Periodontology and Implantology, and 2 Reader, Prosthodontics, Bhojia Dental College and Hospital, Chandigarh, 3 Consultant Periodontist, Ace Medicentre, Baddi, 4 Consultant Prosthodontist, Chandigarh, India

**Correspondence to:** Dr Bharat Joshi, Consultant Periodontist, Ace Medicentre, Baddi, Himachal Pradesh, India, Email – [bharatrimpu@gmail.com](mailto:bharatrimpu@gmail.com).

Received: 10 August 2016      Initial Review: 04 September 2016      Accepted: 17 September 2016      Published Online: 08 October 2016

### ABSTRACT

A variety of syndromes/disorders (genetic/acquired) are encountered in our day-to-day life. Among them, ectodermal dysplasia is a rare syndrome which is transmitted as x-linked recessive/dominant disorder and is known to majorly affect males as compared to females. Clinically, it is observed that there is presence of partial or complete anodontia with conical teeth along with maxillary retrusion, prominent supraorbital ridges or frontal bossing, fine and blond, scanty hair (resembling lanugo), deformed or absent nails, facial physiognomy (fairy-like face) and reduced sweating. Early diagnosis remains the key for the management of ectodermal dysplasia. Since patient suffers from unpleasant appearance (due to partial or complete anodontia); hence, dental management includes replacement of teeth by either fixed/removable partial or complete dentures /implant-supported dentures. We present a case of ectodermal dysplasia with features of oligodontia, severely deficient alveolar processes and maxillary retrusion which was managed with tooth-supported complete overdentures.

**Keywords:** Anodontia, Dentures, Ectodermal Dysplasia, Hidrotic, Oligodontia

Ectodermal dysplasia is seen in every 1 case per 100,000 births [1-2]. It becomes difficult to classify this disorder because of complex, mutually inductive epithelial - mesenchymal interactions which occur during embryogenesis [3-4]. The disease is inherited as X-linked recessive trait; therefore, the frequency and severity of condition is more pronounced in males. Dental anomalies have been associated in 80% of the affected individuals [5]. In some cases, besides oral manifestations, certain organ systems are also affected like immune, respiratory and gastro-intestinal tract.

Often, the skin of the affected individual is eczematous and face appears to have a facial physiognomy which is referred to as 'fairy-like appearance' [6]. It has been observed that this disorder might occur in the first

trimester of pregnancy. It is reported that if the disorder is severe, it appears before the 6<sup>th</sup> week of embryonic life and consequently the dentition is affected [7]. For a proper diagnosis, abnormalities in at least two of the structures i.e. hair, teeth, sweat glands or nails must be present. Prenatal diagnosis is confirmed by foetal biopsy, which is obtained by fetoscopy at about 20 weeks of gestation [8].

### CASE REPORT

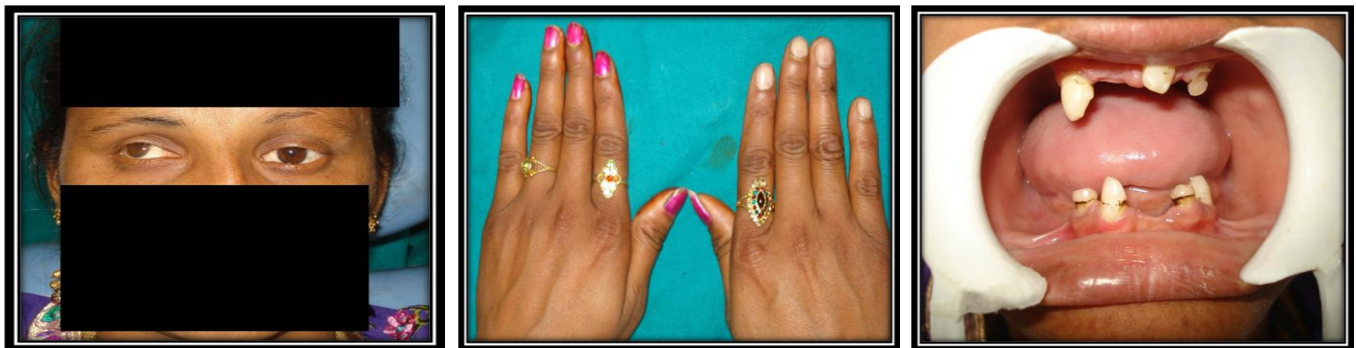A female patient aged, 20 years reported to the Department of Periodontology, Bhojia dental college & Hospital, Baddi, with a chief complaint of inability to eat due to absence of teeth. No family history was reported by the patient. Patient had taken an ayurvedic medicine for the treatment of disease but there was no improvement in the

condition. Clinical examination revealed oligodontia, maxillary retrusion and decreased salivary flow rate. Also, it was observed that there was a defect in the vision of right eye and skin was also a bit scalded. Hair were scanty and nails were normal (Fig. 1 & 2). Only seven teeth were present i.e. right maxillary canine (13), left maxillary central and lateral incisors (21,22) left mandibular canine and lateral incisors (32,33), right mandibular canine and 1<sup>st</sup> premolar (43,44). None of the teeth present in the oral cavity had well developed crowns (Fig. 3).

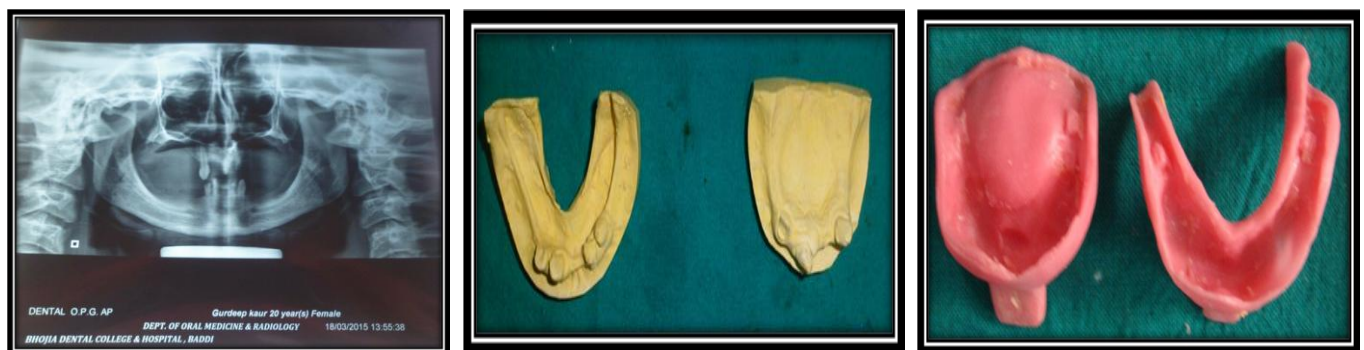There was tenderness on percussion with respect to right maxillary canine (13) and right mandibular 1<sup>st</sup> premolar (44). Radiographic examination revealed poorly

developed alveolar process (Fig. 4). On the basis of the clinical examination and history, a provisional diagnosis of Hidrotic ectodermal dysplasia was made.

Orthopantomogram (OPG) was done to determine the amount of remaining bone and individual radiographs (IOPA) were done to determine the prognosis of teeth present in the oral cavity. It was observed that only basal bone had developed and the alveolar processes were almost completely deficient (Fig. 4). Four teeth had poor crowns and exposed pulps. Analysis of articulated casts and full mouth radiographs determined the potential abutment teeth restoration and endodontic requirement in the context proposed over denture design.



Figures: Figure 1 - Frontal view of patient showing defect in right eye. Figure 2 - Normal finger nails. Figure 3 - Pre-operative view showing partial anodontia

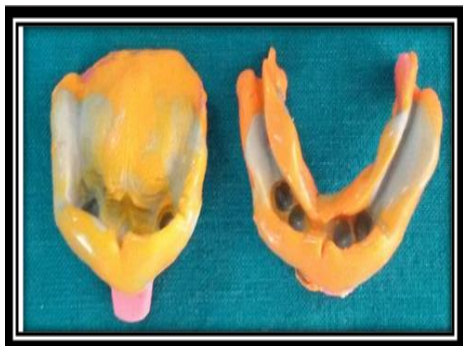

Figures: Figure 4 - Orthopantomogram showing poorly developed alveolar processes. Figure 5 - Diagnostic casts prepared. Figure 6 - Custom trays prepared.

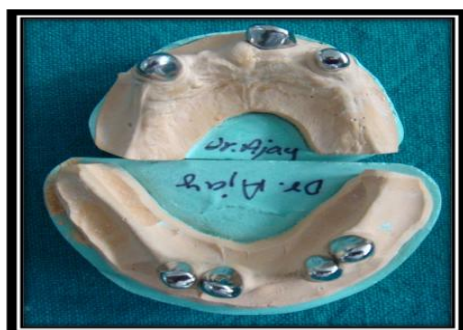
Removable prosthodontics is the most frequently used treatment modality for the dental management of patients with ectodermal dysplasia. Because of anodontia or hypodontia in ectodermal dysplasia, complete partial-dentures or over-dentures (tissue or implant - supported)

are often a part of the treatment. In this case, treatment planning included fabrication of complete tooth supported over-denture for the upper and lower jaws to improve appearance, function and speech. Preliminary impressions were made by hydrocolloid (alginate) impression material

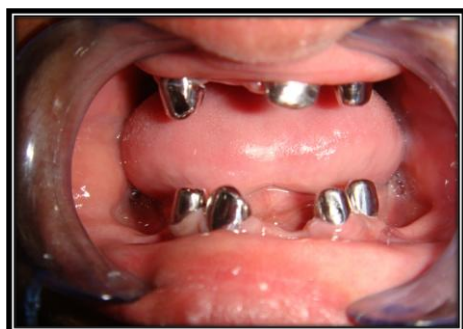using stock tray (Fig. 5). The retained teeth selected as an abutment were modified or restored and endodontically prepared. Maximum reduction of coronal portion of the tooth was accomplished. A better crown to root ratio was established.



**Figure 7 - Final Impressions (elastomeric impression material) taken**



**Figure 8 - Metal Copings placed on master cast**



**Figure 9 - Copings placed in the mouth**

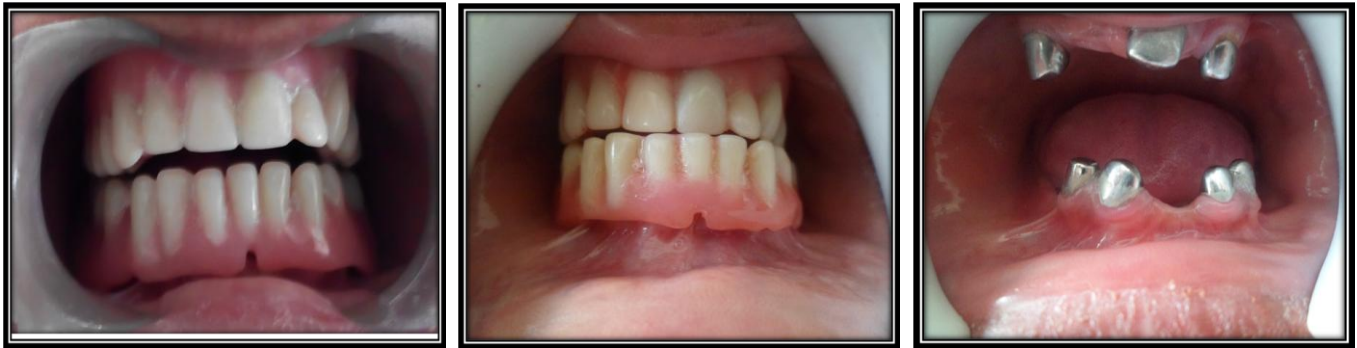Tooth preparation included combination of shoulder and chamfer gingival margins as dictated by the amount of residual tooth structure. Secondary impressions were made by utilizing custom trays and elastomeric impression material (Fig. 6 & 7). The cast copings were fabricated to

prolong the useful life span of the retained abutments and the preservation of alveolar bone. Metal copings were cemented using GIC luting cement (Fig. 8 & 9). Elastomeric impression material was used to make impression for obtaining the master cast. Jaw relations were recorded using temporary base and wax rims. The arranged teeth were verified in the mouth during try-in appointment. After laboratory processing, the over-dentures were relined over metal coping areas by utilizing self-cured acrylic. Flush was removed, finished and polished. Over-dentures were delivered to the patient (Fig. 10). There were no complications with regard to speech, esthetics and mastication after 3, 6 months & 1 year follow-up (Fig. 11 & 12).

## DISCUSSION

Ectodermal dysplasia has been defined by National foundation for ectodermal dysplasia as a genetic disorder in which there are congenital birth defects of two or more ectodermal structures including apocrine glands, lenses, conjunctiva, nipples and ears [9]. Since this disorder affects the ectodermal tissues, it is the keratinocytes which are affected. Individuals often present with premature look along with scaling of skin [7]. Although there are 192 classifications of Ectodermal dysplasia, it can be broadly classified into 5 types: Anhydrotic (hypohidrotic), Hydrotic or Clouston's syndrome, Ectodactyly ectodermal dysplasia, Rapp-hodgkin syndrome and Robinson's disease [10]. Patients report with frontal bossing, depressed nasal bridge, scanty and blond hair (hypotrichosis or atrichosis), and absence of sebaceous glands (asteatosis) with absence or partial absence of sweat glands (hypohydrosis). Often, there is absence of nails or teeth.

In hypohidrotic type, there is maxillary retrusion due to sagittally under developed maxilla and forward and upward placement of mandible along with lower anterior facial height. In oral cavity, the teeth exhibit oligodontia or partial anodontia. Hypodontia often results in articulatory disorders. The frequently affected sounds due to this disorder are sibilants and linguo-dentals. Crowns are abnormally developed and mandibular teeth usually are conical shaped [3]. There is wide midline diastema and lower frenum is hypoplastic. Also, the eyebrows and even eyelashes are missing. There is hoarseness of voice (in hidrotic type), while sweat glands are spared in Clouston type of ectodermal dysplasia [8].



**Figures: Figure 10 - Final denture delivered. Figure 11 – One year post-operative. Figure 12 - One year post-operative**

Certain genetic studies (more than 300 cases) have revealed X-linked inheritance with its gene locus being Xq11-21.1 and gene is carried by female but is manifested in males. However, females are also affected in some cases because of Lyon hypothesis [7]. According to this hypothesis, there is inactivation of one X-chromosome due to which there is one normal gene and one abnormal gene. Hence, females with reduced number of teeth and mild structural changes are also observed as in this case.

Early diagnosis remains the key for management of this disorder. Although there is no definite ideal time at which the management should begin, it is said that initial prosthesis should start when child starts going to school [11]. Periodic recall for young patients is very important because prosthetic modification and replacement may be needed as a result of continuing growth and development. Before placement of any prosthesis, anatomical factors should also be considered [12]. Rehabilitation involves replacement of missing teeth by complete/partial removable partial dentures or over-dentures. Fixed partial dentures are contraindicated since they have rigid connectors that inhibit the growth of dental arches and the number of teeth for support is minimal.

Except the age barrier and cost issues, implant can be considered as an ideal option that will reduce the total treatment time, avoid the iliac crest transplant and eliminates the additional healing time (in case of placement of zygomatic implant in grafted bones). Zygomatic implants associated with gold castings have been successfully used for the treatment of ectodermal dysplasia. However, implants are contraindicated below 13 years of age [13-14]. Hence, the best option is the removable partial/ complete denture.

Since there is absence of alveolar process, there is need of relining or rebasing of dentures between the regular appointments. It is recommended that these procedures should be done after every one or two years due to pre-adolescent growth in jaw dimensions, wear of acrylic teeth, under-extension of dentures and posterior open bite [15]. Optimization of the spaces by orthodontic movement with composite additions, resin retained bridges, veneers, onlays and tooth transplants can contribute to an improvement in aesthetics and functions [6]. Also, dental education regarding cleanliness and better plaque control is required for proper maintenance of dentures.

In the present case, there was complete absence of alveolar processes and only basal bone was present along with oligodontia. Due to partial absence of teeth, patient was not able to masticate properly. Also esthetically, patient wanted to have replacement of the missing teeth. Therefore, complete tooth supported over-dentures were used for rehabilitation. Another option available for the treatment was mini-implants. Since, patient was economically poor, this option for treatment modality was not considered. Patient was frequently recalled to monitor the progress and to adjust the dentures, whenever required.

## CONCLUSION

The major options for oral rehabilitation in ectodermal dysplasia are complete/ removable partial dentures. In children, clinician should opt for removable partial/ overdentures which are both cost effective and easily available modality to restore function, speech, esthetics and psychosocial condition. However, the real success depends upon periodic recalls and patient's co-operation.

## ACKNOWLEDGEMENT

We would like to thank Dr. Ajay Bansal, Reader, Department of Prosthodontics and Dr Ankur Vats, Reader, Department of Conservative Dentistry and Endodontics, Bhojia Dental College and Hospital, Baddi for their kind help and guidance.

## REFERENCES

1. Bora A, Goswami A, Kar A, Kundu GK. Oral rehabilitation of two siblings with Ectodermal Dysplasia: a case report. IOSR-JDMS. 2014; 13(5): 12-18.
2. Wisniewski SA, Kobiela A, Trzeciak WH, Kobiela K. Recent advances in understanding of the molecular basis of anhidrotic ectodermal dysplasia: discovery of a ligand, ectodysplasin A and its two receptors. Journal of Applied Genetics. 2002; 43(1): 97-107.
3. Suprabha BS. Hereditary Ectodermal Dysplasia: a case report. J Indian Soc Pedo Prev Dent. 2002; 20:37-40.
4. Hall KR. Pediatric orofacial medicine and pathology. 4th edition. London: Chapman & Hall; 1994:163.
5. Balshi TJ, Wolfinger GJ. Treatment of Congenital ectodermal dysplasia with Zygomatic Implants: A case report. Int J Oral Maxillofacial Implants. 2002; 17:277-281.
6. Ahmad B, Yazdanie N. hypodontia and Microdontia associated with hereditary ectodermal dysplasia. J Coll Physicians Surg Pak. 2009; 19(3): 192-194.
7. Sharma J, Mamatha GP. Hereditary ectodermal dysplasia: diagnostic dilemmas. Rev Clín Pesq Odontol. 2008; 4(1): 35-40.
8. Babu SG, Castelino RL, Shetty SR, Rao KA. Hereditary ectodermal dysplasia-a case report. Web Med Central Dentistry. 2011; 2(3): WMC001711.
9. Murthy JV, Vaze R. Prosthetic management of an Ectodermal dysplasia patient. People's Journal of Scientific Research. 2010; 3(2): 37-40.
10. Nelson WE. Nelson's textbook of Paediatrics. Philadelphia: Saunders; 1979.
11. Till MJ, Marques AP. Ectodermal Dysplasia: treatment considerations and case reports. Northwest Dent. 1992; 71: 25-28.
12. Franchi L, Branchi R, Tollaro I. Craniofacial changes following early prosthetic treatment in a case of hypohidrotic ectodermal dysplasia with complete anodontia. J Dent Child. 1998; 65: 116-121.
13. Shashibhushan KK, Viswanathan R, Naik SN, Subbureddy VV. Hypohidrotic ectodermal dysplasia with total anodontia: A case report. J Clin Exp Dent. 2011; 3(suppl 1): e-352-355.
14. Guckes AD, McCarthy GR, Brahim J. Use of endosseous implants in a 3-year old child with ectodermal dysplasia: case report and 5 year followup. Pediatr Dent. 1997; 19: 282-285.
15. Shaw RM. Prosthetic management of hypohidrotic ectodermal dysplasia with anodontia. Case report. Aust Dent J. 1990; 35: 113-116.

**How to cite this article:** Singh B, Kaur H, Joshi B, Sahira S. Dental Management of Ectodermal dysplasia: A case report. Indian J Case Reports. 2016; 2(4): 107-111.

*Conflict of interest: None stated, Funding: Nil*