

## Gastric perforation in pediatrics patients: A case report with management

Atul Kumar Khare<sup>1</sup>, Kirti Singh<sup>2</sup>, Harsh Namdev<sup>3</sup>, Pramila Sharma<sup>4</sup>

From <sup>1</sup>Senior Resident, Department of Pediatrics Surgery, SMS Medical College and Hospital, <sup>4</sup>Professor and Unit Head, Department of Pediatrics Surgery, SMS Medical College and Hospital, Jaipur, Rajasthan, <sup>2</sup>Assistant Professor, Department of Obstetrics and Gynecology, Government Medical College, Sheopur, <sup>3</sup>Senior Resident, Department of General Surgery, Netaji Subhash Chandra Bose Medical College and Hospital, Jabalpur, Madhya Pradesh, India

### ABSTRACT

Gastric perforation is uncommon and life-threatening in infants and children. The mortality is up to 30–70%, and the most common cause is congenital gastric muscular wall defects. We reported the case of a 7-year-old boy from a rural locality of north India who presented in the emergency room with a chief complaint of fever for 15 days followed by abdominal pain associated with one episode of non-bilious vomiting and abdominal distention. The child had not passed stool for 3 days. On exploratory laparotomy, we found perforation of 0.5×0.5 cm at the anterior wall of the stomach near the pyloric region, more toward the lesser curvature of the stomach. The stomach, small intestine, and large intestine were loaded with pus flakes. Peritoneal lavage was done, and perforation was primarily repaired with Graham patch omentopexy done. The patient was discharged on the sixth post-operative day without any complications. We concluded that gastric perforation in pediatric patients beyond the neonatal period may lead to fatal clinical outcomes, which causes a mortality rate of as high as 30%. Spontaneous great curvature of gastric wall perforation has the highest morbidity.

**Key words:** Exploratory laparotomy, Gastric perforation, Pediatric patients

**G**astric perforation is uncommon and life-threatening in infants and children [1-4]. Large amounts of studies have explored neonatal gastric perforation, which has been characterized [5,6] as onset within the 1<sup>st</sup> week of age and is complicated by alimentary malformations. The mortality is up to 30–70%, and the most common cause is congenital gastric muscular wall defects [7]. The reported incidence is 1/5000 live births and spontaneous gastric perforation accounts for 7% of all gastrointestinal perforations in newborns. The probable causes of neonatal gastric perforation include asphyxia, vigorous respiratory resuscitative measures, ventilator use, increased intragastric pressure, gastric acidity changes, and anatomical abnormalities of the stomach (e.g., congenital agenesis of the gastric musculature) secondary to iatrogenic traumas (e.g., endotracheal and feeding tube insertion) and steroid use (possibly in combination with cyclooxygenase inhibitors for ductal closure) [1-5].

However, gastric perforation in pediatric patients beyond the neonatal period has rarely been reported, and they have different characteristics from neonatal patients. In general, the clinical characteristics, treatments, and prognosis of such patients are not well understood. Patients with gastric perforation may present


with critical symptoms and their prognosis varies according to the severity of the condition [8]. Pediatric critical illness score (PCIS) has been found to be an objective and quantification method to evaluate the severity of diseases [9]. However, no such study applying PCIS in evaluating the severity of pediatric gastric perforation has ever been reported.

### CASE REPORT

A 7-year-old boy from a rural locality of north India presented in the emergency room with a chief complaint of fever for 15 days followed by abdominal pain associated with one episode of non-bilious vomiting and abdominal distention. The child had not passed stool for 3 days.

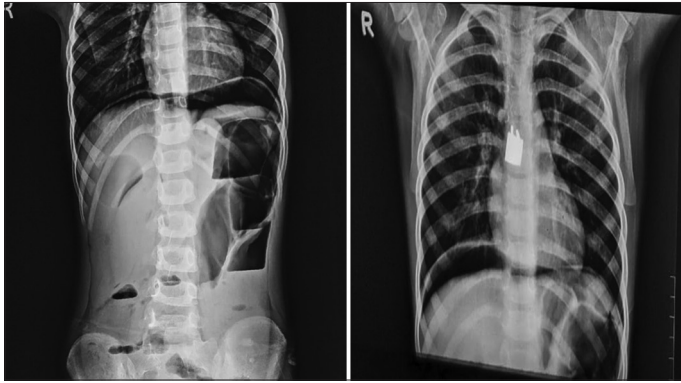
On general examination, the look of the child was sick and febrile with moderate dehydration. On per abdomen examination, abdominal distention with diffuse tenderness with guarding and rigidity, and no bowel sounds were heard. Per rectal examination was normal. The patient was resuscitated first in the emergency room. A nasogastric tube and Foley's catheter were inserted. The patient was started with antibiotics, antipyretics, antiemetic drugs, and fluids.

X-ray chest and abdomen was done which was suggestive of pneumoperitoneum (Fig. 1). Ultrasound abdomen was done which

Access this article online	
Received - 09 September 2024 Initial Review - 08 October 2024 Accepted - 15 October 2024	Quick Response code 
DOI: ***	

**Correspondence to:** Atul Kumar Khare, JK Lone Hospital, SMS Medical College, Jaipur, Rajasthan, India. E-mail: mgmatulkhare92@gmail.com

© 2024 Creative Commons Attribution-NonCommercial 4.0 International License (CC BY-NC-ND 4.0).



**Figure 1:** X-ray chest and abdomen of a 7-year-old child (gas under right subdiaphragmatic area)

was suggestive of mild collection in the right subdiaphragmatic space and right paracolic gutter with low-level echoes and air foci, the possibility of intestinal perforation. All routine investigations were done and found normal.

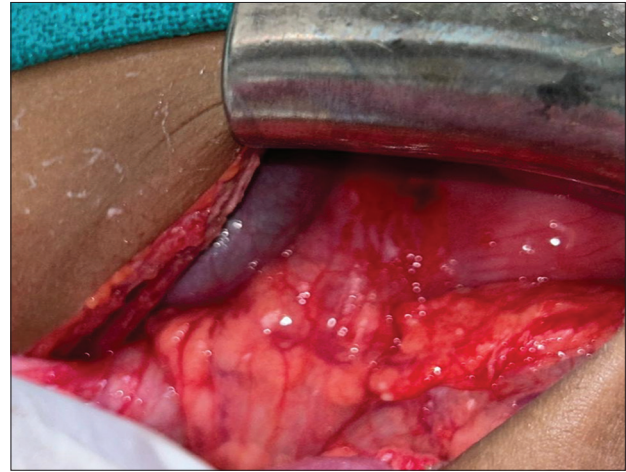
The patient was urgently shifted to the emergency operation theatre. On performing exploratory laparotomy, we found a perforation of 0.5×0.5 cm present at the anterior wall of the stomach near the pyloric region, more toward the lesser curvature of the stomach. The stomach, small intestine, and large intestine were loaded with pus flakes (Fig. 2). Peritoneal lavage was done, and perforation was primarily repaired with Graham's patch omentopexy was done. The abdominal drain was inserted; the abdomen was closed and shifted to the intensive care unit.

Postoperatively, the patient improved day by day. On 3<sup>rd</sup> post-operative day (POD), the patient passed flatus, and 4<sup>th</sup> day, the patient passed motion. On the 4<sup>th</sup> day, the nasogastric tube was removed and the oral liquid was started. Active physiotherapy was given. The patient was discharged on the sixth POD without any complications. Postoperatively, the patient comes in the outpatient department 10<sup>th</sup> POD. The patient recovered well, the wound was healthy, and taking an oral diet normally. No other complaints were present.

## DISCUSSION

Clinical characteristics of gastric perforation beyond the neonatal period in pediatric patients are not well documented. Most patients had a spontaneous gastric perforation, which was in *Helicobacter pylori* infection as it is highly associated with peptic ulcers, which might induce gastric perforation. However, gastric ulcer-induced perforation is uncommon in pediatric patients.

In a study done by Leone and Krasna, they reported a 20-year experience on 52 pediatric patients with perforation induced by peptic ulcers, and they found that only 11 cases (21.2%) were induced by gastric ulcers [10]. This study also revealed that perforation induced by gastric ulcers was mostly found in the pylorus area, which accounted for up to 63.6% (7/11). In a similar study done by Wang *et al.* in 2019, in 20 pediatric patients, they found that Gastric perforation was diagnosed in 20 pediatric patients beyond the neonatal period, including 6 males (30%) and 14 females (70%), with the age of 37.18 (15.90, 107.12) months,



**Figure 2:** Single 0.5×0.5 cm gastric perforation near lesser curvature of pylorus of the stomach

and the range was from 4.30 months to 14.17 years old. Among the 20 cases, 14 (70%) survived and 6 (30%) died. One patient had a 2<sup>nd</sup>-time perforation, another three patients had brain injury symptoms, and the rest 10 patients had a good quality of life. However, this study concludes that pediatric gastric perforation is mostly found in the great curvature of the gastric wall [11].

Other reported causes, such as trichobezoars, gastric volvulus, corrosive ingestion, iatrogenic injuries, childhood dermatomyositis, or child abuse, were included in the study. The decrease in the venous outflow, which is caused by increased intragastric pressure above 30 cm H<sub>2</sub>O, could lead to ischemia and infarction of the gastric wall, which most likely contributed to the “spontaneous” gastric perforation [12,13].

Gastric perforation in the pediatric age group is mostly found in a greater curvature, the same as neonatal cases, and may be explained by gastric receptive relaxation theory. Because the great curvature is the most distensible area of the gastric wall, it tends to be the most prone place for ischemic necrosis, which results in perforation. If perforation is small with no gastrointestinal ischemia or complication, then simple gastric repair was done. However, if the perforation involves a large area of gastrointestinal ischemia or necrosis, then gastric wall repair accompanied by gastrostomy was also done. Other surgery procedures, such as repair of the diaphragm or neoplasm resection, were performed where appropriate [14].

All these efforts contributed to a survival rate of 70%, but 30% of patients who manifested with critical conditions died. High mortality of the disease may be a result of, the intense chemical stimulation of gastric fluid in the peritoneum causing severe peritonitis, bacteria erupting from the alimentary tract, entering into the sterile peritoneal cavity, causing abdominal infection, gastric acid and pepsin not only produce strong stimulation to the abdominal viscera but also have a corrosive effect [15,16]. To quantify the severity, PCIS was applied. It is a comprehensive value generated by the emergency group of the Chinese Medical Association Pediatric Society and a Pediatric group of the Chinese Medical Association Emergency Society and has been proven to be an effective tool that can best assess the severity

of diseases [17,18]. PCIS value of lower than 70 indicates extreme severity, 70–90 demonstrates severity and higher than 90 stands for non-severity. However, ischemia and transmural necrosis of the gastric wall aggravated the infection and led to lower PCIS. Thus, a low PCIS value may serve as a prediction for an unfavorable prognosis. It inspires us to maintain a positive attitude toward such patients [19,20].

## CONCLUSION

Gastric perforation in pediatric patients beyond the neonatal period may lead to fatal clinical outcomes, which causes a mortality rate of as high as 30%. Spontaneous great curvature of gastric wall perforation has the highest morbidity. Low PCIS, caused by ischemia and transmural necrosis of the gastric wall predicts an unfavorable prognosis. Most of the patients will be in good health if treated and diagnosed early and appropriately. Hence, this disease requires prompt diagnosis and treatment for better surgical outcomes.

## REFERENCES

- Vassy LE, Klecker RL, Koch E, Morse TS. Traumatic gastric perforation in children from blunt trauma. *J Trauma* 1975;15:184-6.
- Hashmi KS, Ellul T, Leopard DC, Woodward A. Spontaneous gastric perforation in an 11-year-old boy with anorexia nervosa: Rare presentation with right iliac fossa pain. *BMJ Case Rep* 2012;2012:bcr-2012-006512,1-2.
- Schinasi DA, Ellison AM. Spontaneous gastric perforation in a child with heterotaxy syndrome. *Pediatr Emerg Care* 2010;26:925-7.
- Terui K, Iwai J, Yamada S, Takenouchi A, Nakata M, Komatsu S, *et al.* Etiology of neonatal gastric perforation: A review of 20 years' experience. *Pediatr Surg Int* 2012;28:9-14.
- Duran R, Inan M, Vatansever U, Aladag N, Acunas B. Etiology of neonatal gastric perforations: Review of 10 years' experience. *Pediatr Int* 2007;49:626-30.
- Lin CM, Lee HC, Kao HA, Hung HY, Hsu CH, Yeung CY, *et al.* Neonatal gastric perforation: Report of 15 cases and review of the literature. *Pediatr Neonatol* 2008;49:65-70.
- Yang CY, Lien R, Fu RH, Chu SM, Hsu JF, Lai JY, *et al.* Prognostic factors and concomitant anomalies in neonatal gastric perforation. *J Pediatr Surg* 2015;50:1278-82.
- Chung MT, Kuo CY, Wang JW, Hsieh WS, Huang CB, Lin JN. Gastric perforation in the neonate: Clinical analysis of 12 cases. *Zhonghua Min Guo Xiao Er Ke Yi Xue Hui Za Zhi* 1994;35:460-5.
- Durham MM, Ricketts RR. Neonatal gastric perforation and necrosis with Hunt-Lawrence pouch reconstruction. *J Pediatr Surg* 1999;34:649-51.
- Leone RJ Jr, Krasna IH. "Spontaneous" neonatal gastric perforation: Is it really spontaneous? *J Pediatr Surg* 2000;35:1066-9.
- Wang K, Cai S, He L, Peng C, Pang W, Wang Z, *et al.* Pediatric gastric perforation beyond neonatal period: 8-year experience with 20 patients. *Pediatr Neonatol* 2019;60:634-40.
- Dong CJ, Zhang WX, Xiao CG. Making the scoring card based on pediatric critical illness score. *Zhonghua Er Ke Za Zhi* 2003;41:63.
- Grosfeld JL, Molinari F, Chaet M, Engum SA, West KW, Rescorla FJ, *et al.* Gastrointestinal perforation and peritonitis in infants and children: Experience with 179 cases over ten years. *Surgery* 1996;120:650-5.
- Koç O, Yildiz FD, Narci A, Sen TA. An unusual cause of gastric perforation in childhood: Trichobezoar (Rapunzel syndrome). A case report. *Eur J Pediatr* 2009;168:495-7.
- Singh S, Wakhlu A, Pandey A, Kureel SN, Rawat JD. Delayed presentation of strangulated congenital diaphragmatic hernia: Learning from our experience. *Hernia* 2013;17:403-7.
- El-Asmar KM, Allam AM. Surgical management of corrosive-induced gastric injury in children: 10 years' experience. *J Pediatr Surg* 2017;53:744-7.
- Sulaiman TA, Abdulmajeed AA, Shahramian K, Hupa L, Donovan TE, Vallittu P, *et al.* Impact of gastric acidic challenge on surface topography and optical properties of monolithic zirconia. *Dent Mater* 2015;31:1445-52.
- Lu XL, Qiu J, Zhu YM, Chen P, Zuo C, Tang L, *et al.* Role of pediatric critical illness score in evaluating severity and prognosis of severe hand-foot-mouth disease. *Zhongguo Dang Dai Er Ke Za Zhi* 2015;17:961-4.
- Yan X, Kuang H, Zhu Z, Wang H, Yang J, Duan X, *et al.* Gastroduodenal perforation in the pediatric population: A retrospective analysis of 20 cases. *Pediatr Surg Int* 2019;35:473-7.
- Aydin M, Deveci U, Taskin E, Bakal U, Kilic M. Percutaneous peritoneal drainage in isolated neonatal gastric perforation. *World J Gastroenterol* 2015;21:12987-8.

*Funding: Nil; Conflicts of interest: Nil.*

**How to cite this article:** Khare AK, Singh K, Namdev H, Sharma P. Gastric perforation in pediatrics patients: A case report with management. *Indian J Case Reports*. 2024;October 24 [Epub ahead of print].