

A case report of arthrocentesis in temporomandibular joint internal derangement

Muhammed Thanseeh¹, R Rohith¹, V P Sreejith², Ushas Puthalath³, Jibin Jose Tom⁴

From ¹Post Graduate Student, ²Professor and Head, ³Professor, ⁴Reader, Department of Oral and Maxillofacial Surgery, Kannur Dental College, Anjarakandy, Kerala, India

ABSTRACT

In this case report, a 56-year-old male presented to our department of oral and maxillofacial surgery with a chief complaint of pain during mouth opening on the left joint region. The patient also complained of limited mouth opening and temporomandibular joint (TMJ) pain. Arthrocentesis was performed under aseptic conditions. Clinical evaluation of the patients was done before the procedure, 1 week, 1 month, and 4 months postoperatively. Intensity of TMJ pain and maximal mouth opening were recorded at each follow-up visit. There was a significant improvement in mouth opening and a reduction in pain scores in the postoperative period. Arthrocentesis is a simple and safe procedure for patients with internal derangement with a closed lock for improving mouth opening and decreasing pain.

Key words: Arthrocentesis, Chronic pain, Internal derangement, Temporomandibular joint

The temporomandibular joint (TMJ) is a synovial joint that contains an articular disc, for hinge and sliding movements. This complex combination of movements allows for painless and efficient chewing, swallowing, and speaking. The articulating surfaces of the TMJ are covered by fibrous connective tissue; this avascular and non-innervated structure has a greater capacity to resist degenerative change and regenerate itself than the hyaline cartilage of other synovial joints. The synovial joint capsule and surrounding musculature are innervated, however, and are thought to be the primary source of pain in TMJ disorders (TMD) [1]. TMD are a class of degenerative musculoskeletal conditions associated with morphological and functional deformities. TMDs include abnormalities of the intra-articular discal position and/or structure as well as dysfunction of the associated musculature. Symptoms and signs include painful joint sounds, restricted or deviating range of motion, and cranial and/or muscular pain known as orofacial pain. Up to 70% of TMD patients suffer from pathology or malpositioning of the TMJ disc, termed “Internal derangement” [2]. Internal derangement is a general orthopedic term implying a mechanical fault that interferes with the smooth action of a joint. Internal derangement is thus a functional diagnosis, and for TMJ, the most common internal derangement is displacement of the disc. Splint therapy, arthrocentesis, arthroscopic lysis and lavage, and arthrotomy are effective in TMJ conditions. Lysis and lavage of the TMJ aid in mechanical lysis of adhesions with lavage was first done using

arthroscopy by Ohnishi, which was later modified and performed without internal visualization, arthrocentesis, by Nitzan *et al.* [3].


CASE REPORT

A 56-year-old male patient presented to our department with a chief complaint of pain in the left joint region and restricted mouth opening. The patient gave a history of clicking sound in the left TMJ for the past 5 years, limited mouth opening, and constant dull ache in the left preauricular region in the past 3 months. Opening wide and chewing motions acted as aggravating factors.

On examination, mouth opening was restricted to 2.6 cm, jaw deviation to the left and extreme tenderness during palpation over the left TMJ.

The medication tablet Zerodol TH 4 (aceclofenac 100 mg + thiocolchicoside 4 mg) was given thrice a day for 3 days, and mouth exercises were started by the patient after the first visit. Initial medications reduced the pain with mild discomfort remaining after 1 week during function. The patient was planned for TMJ arthrocentesis and splint therapy.

The preauricular skin over the TMJ was prepared with topical antiseptic solution and draped. A line was drawn from the lateral canthus to the most posterior and central point on the tragus (Holmlund–Helsing Line) [3] (Fig. 1a). The posterior point of entry is located along the canthotragal line 10 mm from the middle of the tragus and 2 mm below the canthotragal line, approximating the area of maximum concavity of the glenoid

Access this article online	
Received-23 May 2024 Initial Review-13 June 2024 Accepted-13 August 2024	Quick Response code 
DOI: ***	

Correspondence to: Muhammed Thanseeh, Kunhiparambath House, Kurikkilad (PO), Vadakara (via), Kozhikode (DT) - 673104, Kerala, India. E-mail: thanseeh00@gmail.com

© 2024 Creative Commons Attribution-NonCommercial 4.0 International License (CC BY-NC-ND 4.0).

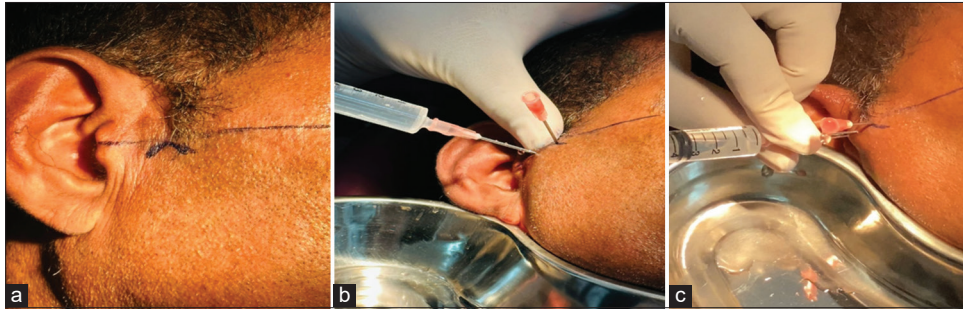


Figure 1: (a) A line was drawn from the lateral canthus to the most posterior and central point on the tragus (Holmlund–Hellsing Line); (b) The anterior point of entry is placed 10 mm further along the canthotragal line and 10 mm below it indicating the articular eminence; (c) Approximately 2 mL of Hartmann's (Ringer's lactate) solution was then injected to distend the superior joint space, followed by insertion of another 18-gauge needle for outflow from the superior joint space

fossa. The distance is about 25 mm from the skin to the center of the joint space [3]. The anterior point of entry is placed 10 mm further along the canthotragal line and 10 mm below it indicating the articular eminence (Fig. 1b). The auriculotemporal nerve block was given followed by the introduction of an 18-gauge needle into the superior joint space. Approximately 2 mL of Hartmann's (Ringer's lactate) solution was then injected to distend the superior joint space, followed by the insertion of another 18-gauge needle for outflow from the superior joint space (Fig. 1c). A total of 100 mL of solution was used to lavage the superior joint space. After the lavage was completed, the needles were removed, and the patient's jaw was gently manipulated by the clinician in the vertical, protrusive, and lateral excursions to help further free the disc and break the adhesions. The patient was then followed with the same protocol.

Post-operative and pre-operative pain and mouth opening were compared at 1 week, 1 month, and 4 months which demonstrated a significant decrease in pain scores and increased mouth opening at 1 week. The pre-operative mouth opening was 26 mm and it increased to 34 mm within 1 week, 40 mm within 1 month, and 45 mm within 4 months.

DISCUSSION

The idea of TMJ arthrocentesis and lavage was first borne out of the successful use of TMJ arthroscopy not only as a diagnostic tool but also as a therapeutic technique resulting in remarkable improvement in pain, jaw opening, and function in selected patients through the simple process of lavaging the superior joint space. TMJ arthrocentesis is understood to include lavage of the upper joint space, hydraulic pressure, and manipulation to release adhesions, or the “anchored disc phenomenon” or the suction-cup effect and improved motion, and the therapeutic injection of a steroid [4-6].

The observation of this case report is in conformity with the findings of the initial clinical trial that TMJ arthrocentesis and lavage with manipulation is an effective technique for the treatment of acute persistent closed lock of the TMJ in terms of significantly improving maximum mouth opening and jaw function and reducing pain. In addition to the effective treatment of acute closed lock, it has also been suggested that

TMJ arthrocentesis and lavage may further be useful for the management of osteoarthritis, early rheumatoid arthritis, and acute intracapsular trauma with hemarthrosis of the TMJ [7-9].

Complications of TMJ arthrocentesis and lavage include extravasation of fluid into surrounding tissue, facial nerve injury (0.7–0.6%), fifth nerve deficit (0.1–2.4%), otic injury (0.5–8.6%), preauricular hematoma, superficial temporal artery aneurysm, arteriovenous fistula, trans-articular perforation, intracranial perforation, extradural hematoma, parapharyngeal swelling, and intra-articular problems [10-13].

Şentürk and Cambazoğlu classified the TMJ arthrocentesis techniques, organizing the options by the number of punctures: A single-puncture arthrocentesis (SPA) and double-puncture arthrocentesis, which is the traditional arthrocentesis technique which is used in this case report. Within SPA, there is further classification organizing the options by the number of needles: Type 1, which is the single-needle cannula method, and Type 2, which is a single-puncture method using a double or dual-needle cannula [3]. There is a new innovation of injecting platelet-rich plasma (PRP) intra-articularly, there was a higher efficacy of intra-articular PRP injections than arthrocentesis for the treatment of reducible disc displacement of TMJ. Recalcitrant TMD cases are better managed by intra-articular PRP injection and arthrocentesis, resulting in symptoms diminution and functional amelioration [4].

CONCLUSION

The most important aims of lysis and lavage of the TMJ are to eliminate inflamed synovial fluid, to release the disc, to reduce pain, and to enable mobilization of the joint by flushing the upper joint space. TMJ arthrocentesis seems to be a safe alternative in patients with internal derangement of a closed lock with fewer complications.

REFERENCES

1. Buescher JJ. Temporomandibular joint disorders. *Am Fam Physician* 2007;76:1477-82.
2. Murphy MK, MacBarb RF, Wong ME, Athanasiou KA. Temporomandibular disorders: A review of etiology, clinical management, and tissue engineering strategies. *Int J Oral Maxillofac Implants* 2013;28:e393-414.
3. Nitzan DW. Arthrocentesis-incentives for using this minimally invasive approach for temporomandibular disorders. *Oral Maxillofac Surg Clin*

- North Am 2006;18:311-28.
4. Ansar AS, Munna K, Iqbal A, Mohammad F, Naved A, Shamimul H. Prognostic criteria for the management of temporomandibular disorders using arthrocentesis with normal saline and arthrocentesis with normal saline and platelet-rich plasma. *J Med Life* 2022;15:698-704.
 5. Zotti F, Albanese M, Rodella LF, Nocini PF. Platelet-rich plasma in treatment of temporomandibular joint dysfunctions: Narrative review. *Int J Mol Sci* 2019;20:277.
 6. Guarda-Nardini L, De Almeida AM, Manfredini D. Arthrocentesis of the temporomandibular joint: Systematic review and clinical implications of research findings. *J Oral Facial Pain Headache* 2021;35:17-29.
 7. Hu Y, Liu S, Fang F. Arthrocentesis vs conservative therapy for the management of TMJ disorders: A systematic review and meta-analysis. *J Stomatol Oral Maxillofac Surg* 2023;124:101283.
 8. Monteiro JL, de Arruda JA, de Oliveira e Silva ED, do Egito Vasconcelos BC. Is single-puncture TMJ arthrocentesis superior to the double-puncture technique for the improvement of outcomes in patients with TMDs? *J Oral Maxillofac Surg* 2020;78:1319.e1-15.
 9. Ibi M. Inflammation and temporomandibular joint derangement. *Biol Pharm Bull* 2019;42:538-42.
 10. Tvrđy P, Heinz P, Pink R. Arthrocentesis of the temporomandibular joint: A review. *Biomed Pap Med Fac Univ Palacky Olomouc Czech Repub* 2015;159:31-4.
 11. Al-Belasy FA, Dolwick MF. Arthrocentesis for the treatment of temporomandibular joint closed lock: A review article. *Int J Oral Maxillofac Surg* 2007;36:773-82.
 12. Koçer G, Şentürk MF. Does the cannula diameter affect outcomes of temporomandibular joint (TMJ) arthrocentesis? *J Oral Maxillofac Surg* 2022;80:431-6.
 13. Gurung T, Singh RK, Mohammad S, Pal US, Mahdi AA, Kumar M. Efficacy of arthrocentesis versus arthrocentesis with sodium hyaluronic acid in temporomandibular joint osteoarthritis: A comparison. *Natl J Maxillofac Surg* 2017;8:41-9.

Funding: Nil; Conflicts of interest: Nil.

How to cite this article: Thanseeh M, Rohith R, Sreejith VP, Puthalath U, Tom JJ. A case report of arthrocentesis in temporomandibular joint internal derangement. *Indian J Case Reports*. 2024; August 27 [Epub ahead of print].