

Yolk sac tumor in sigmoid colon with liver metastasis: A rare case report

Rohith Muddasetty¹, Basant Mahadevappa², Vishwajeeth Pai³, H R Jeevan⁴

¹Junior Consultant, ²Consultant, Department of HPB Surgery and Liver Transplantation, ³Medical Oncologist, ⁴Medical Gastroenterologist, HCG Hospital, Bengaluru, Karnataka, India

ABSTRACT

Extragenital germ cell tumor (EGGCT) is a rare tumor of primordial germ cells. They commonly involve the central nervous system and anterior mediastinum. The gastrointestinal system is a rare site for EGGCTs. Here, we present the case of a 34-year-old lady who presented with bleeding per rectum. She was evaluated with colonoscopy which showed a growth in the sigmoid colon and biopsy suggestive of poorly differentiated adenocarcinoma. Further evaluation showed multiple liver metastases. Considering colorectal liver metastasis, she was treated with liver-directed neoadjuvant chemotherapy. Following four cycles of chemotherapy, she underwent anterior resection of the sigmoid colon and microwave ablation of the liver metastasis. The final histopathological examination changed the diagnosis as yolk sac tumor. She is currently receiving chemotherapy. Proper small biopsy evaluation with immunohistochemical staining especially when it was a poorly differentiated adenocarcinoma would have prompted us for an appropriate neoadjuvant therapy to improve patient outcome.

Key words: Anterior resection, Germ cell tumor, Microwave ablation of liver, Neoadjuvant therapy

Germ cell tumors (GCTs) originate from primordial germ cells and commonly arise from gonads (testis or ovary) and uncommonly from extragonadal tissue. They are broadly classified as seminomas and non-seminomas [1]. The extragonadal GCTs (EGGCTs) constitute only 1–3% of all the GCTs. The most common locations for EGGCT are the central nervous system (46%) and anterior mediastinum (28%) [2]. In the central nervous system, the pineal gland and suprasellar area are commonly involved. The etiopathogenesis of EGGCT is not very well understood. Two theories have been proposed: (a) aberrant migration of the primordial germ cells; and (b) reverse migration of germ cells from gonad to other areas [3]. Aneuploidy and Chromosome 12 abnormalities are frequently identified [2]. In the gastrointestinal system, the stomach, colon, and liver are the common sites to be involved in GCT [4,5].

Here, we present a rare case of sigmoid colon EGGCT with liver metastasis. There are only a few cases of colonic EGGCT reported in the literature, exact incidence is not known.

CASE REPORT

A 34-year-old young lady presented with complaints of 5–10 mL of blood in stools for 15–20 days. She had a history of constipation on and off for a long time which was not addressed. She was

a known diabetic for 5 years and hypothyroid for 10 years on regular medications.


On examination, she was a moderately built and nourished lady in a stable hemodynamic condition. She was neither pale nor icteric and had no pedal edema or generalized lymphadenopathy. Per abdomen was soft and non-tender on examination. She had no organomegaly or free fluid. Per rectal examination showed no palpable growth or ulcers and normal stool staining was noted.

She was evaluated with a colonoscopy and found to have an ulceroproliferative friable growth in the sigmoid colon. Biopsy from the lesion showed features of poorly differentiated adenocarcinoma with acellular mucin pools. Further, she underwent positron emission tomography-computed tomography (PET-CT) whole body, which showed 1.4 cm thickening of the sigmoid colon for a length of 7 cm, pericolic fat stranding. She had enlarged lymph nodes involving sigmoid mesentery and retroperitoneum. The liver showed multiple enhancing hypodense lesions involving both lobes of the liver, the largest being 4×3.7 cm in segment 8. Carcinoembryogenic antigen (CEA) was 283.5 ng/mL. A diagnosis of sigmoid colon carcinoma with liver metastasis was made and planned for neoadjuvant chemotherapy.

She received four cycles of the FOLFOX (5-FU, leucovorin, and oxaliplatin) regimen. Following chemotherapy, CEA was 247.6 ng/mL. Repeat PET-CT performed showed regression in the size of the sigmoid colon thickening and liver lesions. Marginal regression of the size of lymph nodes was noted (Fig. 1).

Correspondence to: Dr. Rohith Muddasetty, S 811, 7th Main Road, 2nd Stage, Bharath Nagar, Bengaluru - 560 091, Karnataka, India. E-mail: rohith.m.setty@gmail.com

© 2024 Creative Commons Attribution-NonCommercial 4.0 International License (CC BY-NC-ND 4.0).

Access this article online	
Received - 03 April 2024 Initial Review - 20 April 2024 Accepted - 24 May 2024	Quick Response code 
DOI: ***	

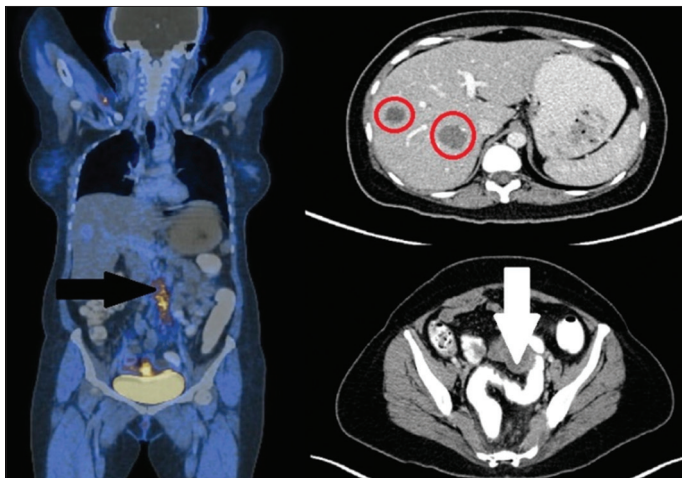


Figure 1: Positron emission tomography-computed tomography whole body scan after neoadjuvant chemotherapy showing thickening of sigmoid colon with left ovarian cyst (white arrow), retroperitoneal nodes (black arrow) and liver lesions (red circle)

She was planned for anterior resection of the sigmoid colon with right hepatectomy for liver lesions. On performing a diagnostic laparoscopy, peritoneal disease was ruled out. However, the liver was severely steatotic and a decision to perform microwave ablation of liver metastasis was made. Densely adherent lymph nodes were noted along the inferior mesenteric artery. Laparotomy was performed and all the lymph nodes along the inferior mesenteric artery and aorta were resected along with anterior resection of sigmoid colon and colo-rectal anastomosis. The patient recovered well following surgery, she was discharged on day 5 after initiating a soft diet and she had passed stools.

Final histopathological evaluation of the tumor showed features suggestive of EGGCT- yolk sac tumor with metastasis to 16 out of 25 lymph nodes. Bowel resection margins were free of the tumor (Fig. 2). Previous colonoscopic biopsy slides were reviewed and showed poorly differentiated neoplasm with reticular pattern and myxoid stroma favoring yolk sac tumor.

After surgery, CEA was reduced to 28.9 ng/mL. Her Alfa-fetoprotein level was 8930 IU/mL. At present, the patient is started on chemotherapy directed to the yolk sac tumor, which includes bleomycin, etoposide, and cisplatin. She has been on regular follow-up for 3 months and doing well.

DISCUSSION

Yolk sac tumor also known as endodermal sinus tumor belongs to the group of GCT. This tumor commonly occurs in the testis of young males where the prognosis is good. Adult yolk sac tumor is often mixed type [6]. In females, the yolk sac tumor is an uncommon malignancy of the ovary. They generally present at an early age with a median of 18 years and rarely after 40 years [7].

EGGCT is a rare tumor involving the gastrointestinal system. There are few reports in the literature. Kucukoner *et al.* described a case of growth in the hepatic flexure of the colon, which was proven to be seminoma only in the final histopathological examination after resection. The patient was treated with adjuvant

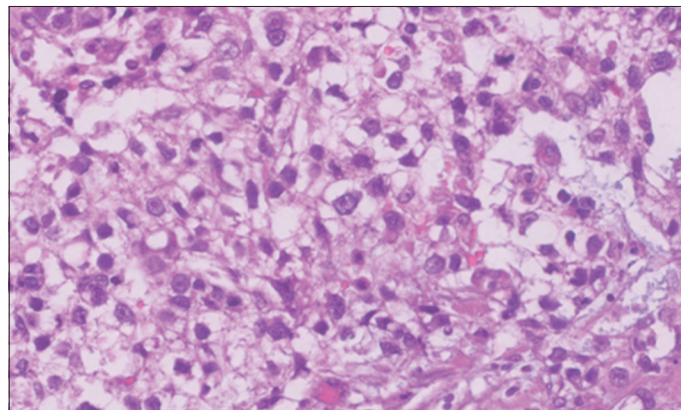


Figure 2: Microscopic picture of the tumor showing areas of solid sheets of cells with moderate to abundant pale eosinophilic to vacuolated clear cytoplasm, a vesicular nucleus with prominent macronucleoli

bleomycin, etoposide, and cisplatin. They also described the case of a duodenal yolk sac tumor that was treated with surgery and chemotherapy. The patient was in remission for 6 months at the time of publication of the article [8]. Noguchi *et al.* have described a gastric choriocarcinoma who was treated with surgery and chemotherapy with a survival of more than 4 years [4]. Hosseini *et al.* have described a teratoma in the liver of a 22-year-old woman who underwent a right hepatectomy [5]. Maehira *et al.* have described a case of sigmoid colon choriocarcinoma with foci of moderately differentiated adenocarcinoma treated with chemotherapy directed for adenocarcinoma, had progressive disease and the patient succumbed after 9 months [9]. ElRifai *et al.* have described the case of a 2-year-old girl child with an abdominal mass, found to have an ileal yolk sac tumor, underwent resection and chemotherapy, and is on regular follow-up at present [10].

Preoperative diagnosis is often missed due to inconclusive findings in small biopsy specimens. Patients often land up in surgery considering typical colonic adenocarcinoma. Neoadjuvant chemotherapy followed by surgery would improve the outcomes in such lesions. In our patient, liver-directed chemotherapy was initiated as she was presumed to have colorectal liver metastasis. The final histopathological examination of the specimen and co-relation of the prior biopsy specimen gave the picture of the yolk sac tumor. Pre-operative diagnosis is missed in such scenarios is also evident from the literature cited above. The patient would have benefited from neoadjuvant chemotherapy directed to GCT followed by surgery. We feel that proper evaluation of small biopsy samples is essential especially when a poorly differentiated tumor has been diagnosed. The addition of immunohistochemistry staining in identifying such rare tumors should be considered so that appropriate neoadjuvant therapy can be administered to improve patient outcomes.

CONCLUSION

The gastrointestinal system is a rare site for the development of EGGCTs. Here, we presented a case of the sigmoid colon

yolk sac tumor with liver metastasis. Pre-operative biopsy of the lesion was suggestive of adenocarcinoma and she was treated with neoadjuvant chemotherapy for the same. However postoperatively, the diagnosis changed to EGGCT and now she is receiving chemotherapy directed for EGGCT. Proper evaluation of small biopsy specimens is of utmost importance in identifying rare tumors so that appropriate neoadjuvant therapy can be administered.

ACKNOWLEDGMENTS

We thank the Consultants in the department of pathology, HCG Hospital for their support in treating the patient and preparing this article. We have not received any funds to prepare this article.

REFERENCES

1. Boujelbene N, Cosinschi A, Boujelbene N, Khanfir K, Bhagwati S, Herrmann E, *et al.* Pure seminoma: A review and update. *Radiat Oncol* 2011;6:90.
2. Ronchi A, Cozzolino I, Montella M, Panarese I, Zito Marino F, Rossetti S, *et al.* Extragonadal germ cell tumors: Not just a matter of location. A review about clinical, molecular and pathological features. *Cancer Med* 2019;8:6832-40.
3. Germ Cell Seminoma. StatPearls. Available from: <https://www.ncbi.nlm.nih.gov/books/NBK559241> [Last accessed on 2024 Jan 27].
4. Noguchi T, Takeno S, Sato T, Takahashi Y, Uchida Y, Yokoyama S. A patient with primary gastric choriocarcinoma who received a correct preoperative diagnosis and achieved prolonged survival. *Gastric Cancer* 2002;5:112-7.
5. Malek-Hosseini SA, Baezzat SR, Shamsaie A, Geramizadeh B, Salahi R, Salahi H, *et al.* Huge immature teratoma of the liver in an adult: A case report and review of the literature. *Clin J Gastroenterol* 2010;3:332-6.
6. Talerman A. Endodermal sinus (yolk sac) tumor elements in testicular germ-cell tumors in adults: Comparison of prospective and retrospective studies. *Cancer* 1980;46:1213-7.
7. Hannan A, Malik MA, Fasih S, Badar F, Siddiqui N. Malignant ovarian germ cell tumors at a tertiary care setting in Pakistan. *J Ayub Med Coll Abbottabad* 2015;27:624-7.
8. Kucukoner M, Inal A, Ali Kalpan M, Urakci Z, Ucmak F, Isikdogan A, *et al.* Germ cell tumor located in gastrointestinal system: A report of two cases. *World J Oncol* 2012;3:134-7.
9. Maehira H, Shimizu T, Sonoda H, Mekata E, Yamaguchi T, Miyake T, *et al.* A rare case of primary choriocarcinoma in the sigmoid colon. *World J Gastroenterol* 2013;19:6683-8.
10. ElRifai A, Akel S. Extra-gonadal germ cell tumor. *J Pediatr Surg Case Rep* 2020;59:101505.

Funding: Nil; Conflicts of interest: Nil.

How to cite this article: Muddasetty R, Mahadevappa B, Pai V, Jeevan HR. Yolk sac tumor in sigmoid colon with liver metastasis: A rare case report. *Indian J Case Reports* 2024; June 06 [Epub ahead of print].