

Jehovah playing his part: A tale of giant hemangioma – Can we do major liver resections without blood or blood products?

Adithya V Naragund¹, Sharath S Kumar², Rohith Muddasetty³

1Consultant, Department of GI/HPB Surgery and Liver Transplantation, 2Registrar, Department of GI/HPB Surgery, Cytecure Hospital, 3Junior Consultant, Department of GI/HPB Surgery and Liver Transplantation, HCG Hospital, Bengaluru, Karnataka, India

ABSTRACT

Hemangiomas are common benign lesions of the liver. They are generally asymptomatic. Kasabach–Merritt syndrome is an uncommon presentation of hepatic hemangioma requiring treatment. Here, we present a case of a 26-year-old female of Jehovah’s Witness with large hepatic hemangioma and Kasabach–Merritt syndrome. She was refused surgery elsewhere due to the risk of intraoperative hemorrhage. With proper preoperative planning and a team approach, we have performed the successful resection of hemangioma without the need for blood transfusion. We present this case to convey that the use of low central venous pressure, hemodilution, meticulous surgical technique, and intraoperative blood cell salvage and autotransfusion can avoid allogeneic blood transfusion not only in Jehovah’s Witness but also in the general population.

Key words: Autotransfusion, Cavernous hemangioma, Intraoperative blood cell salvage, Kasabach–Merritt syndrome

Cavernous hemangioma of the liver is the most common benign lesion with incidence up to 0.4–20%. They are clusters of blood-filled cavities lined by endothelial cells with a feeding hepatic artery branch [1]. When the size is more than 5 cm, it is termed giant hemangioma, and when more than 10 cm, it is termed mega hemangioma [2]. The mean age at diagnosis is in the fifth decade with a female preponderance at a ratio of 5:1 [3]. These lesions are asymptomatic most of the time and found on imaging for some other reasons. The most common symptom is dull aching pain abdomen. Uncommonly, they may present with features of hemolytic anemia and thrombocytopenia, described as Kasabach–Merritt syndrome. Approximately, 1 in 300 hemangiomas have coagulopathy [4]. This syndrome has a mortality of 12–50% [5] symptomatic hemangiomas are to be treated; however, asymptomatic lesions can be observed or treated to avoid complications such as rupture or bleeding.

Here, we present a case of giant hemangioma of the liver presenting with features of Kasabach–Merritt syndrome, how we have planned liver resection and maneuvers to avoid blood transfusion.

CASE REPORT


A 26-year-old female hailing from Ghana presented with abdomen pain. The pain was dull aching in nature, localized to the right

hypochondrium with no aggravating or relieving factors, and not associated with food intake. She was a Jehovah’s witness patient. She had undergone evaluation in her home country for refractory anemia requiring repeated erythropoietin and iron infusions. It was found that she had a giant hemangioma of the liver. She was referred to us in view of the risk of blood loss involved during the surgery.

On presentation, she was conscious and alert with stable vitals. Mild pallor was noted. Per abdomen examination revealed a soft nontender abdomen with hepatomegaly.

She was evaluated with all the blood investigations and contrast-enhanced computed tomography (CT) of the abdomen and pelvis. Imaging showed a giant hemangioma of 17 cm in size in the right lobe of the liver and another one of 8 cm in size in the left lobe of the liver (Fig. 1). Blood investigations showed that she still had anemia. This anemia can be attributed to Kasabach–Merritt syndrome. She was evaluated for right hepatectomy and enucleation of the left lobe hemangioma. The challenge in this patient was to tackle hemorrhage and hypovolemia without blood or blood product transfusion.

Preoperative planning included an anesthetist, surgeon, and intensivist. The following plan was made to prevent excessive blood loss: Maintaining low central venous pressure (CVP); Hemodilution technique; Intraoperative blood cell salvage and autotransfusion (IBSA); Minimize blood loss by liberal use of all necessary gadgets, such as cavitronic ultrasonic surgical

Access this article online	
Received - 02 April 2024 Initial Review - 16 April 2024 Accepted - 10 May 2024	Quick Response code 
DOI: ***	

Correspondence to: Dr. Rohith Muddasetty, S-811, 7th Main Road, 2nd Stage, Bharath Nagar, Bengaluru - 560 091, Karnataka, India. E-mail: rohith.m.setty@gmail.com

© 2024 Creative Commons Attribution-NonCommercial 4.0 International License (CC BY-NC-ND 4.0).

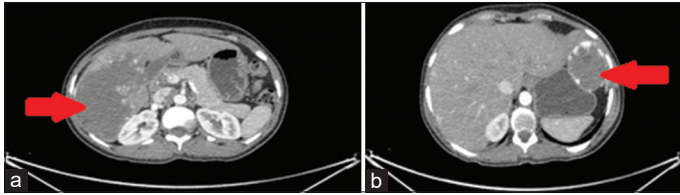


Figure 1: Computed tomography scan of the abdomen showing hemangioma of the liver marked with arrows. (a): Right lobe lesion, (b): left lobe lesion

aspirator (CUSA), harmonic scalpel, bipolar energy device, clips, and ligatures. With all the precautions, the patient underwent right hepatectomy and enucleation of left lobe hemangioma (Fig. 2). Intraoperative blood loss was around 300 mL which was transfused to the patient using a cell-saver machine. The duration of surgery was 8 h. Her hemodynamics in the intraoperative period was kept stable with the use of inotropes and maintaining low CVP.

The postoperative period was uneventful. She was started on oral liquids on day 2 and a soft diet on day 3. Drain removed on day 4. The patient was discharged on day 5. Day 5 liver functions were within normal limits. On day 15, she got a plain CT scan of the abdomen, which showed good liver hypertrophy (Fig. 3); hemoglobin and platelets were maintained with no further fall.

DISCUSSION

Hemangioma is a commonly encountered benign lesion of the liver. They often present with dull aching pain abdomen. Rarely, they can present with Kasabach–Merritt syndrome, which is the consumption coagulopathy due to hemangioma. Hemangiomas are often diagnosed by CT scan of the abdomen. Classical nodular peripheral enhancement with a late progressive centripetal filling of contrast is seen [6]. Atypical findings are not uncommon and are difficult to differentiate from malignant lesions. A biopsy is not advised due to the risk of hemorrhage [7].

Conservative management with routine follow-up and imaging has been suggested in asymptomatic patients even with giant hemangiomas [8]. Percutaneous or laparoscopic radiofrequency ablation has been performed in giant hemangiomas [9]. Transarterial embolization can also be utilized in symptomatic individuals [10]. However, the ablative methods only reduce the size of the lesion and recurrence is common.

Surgical resection of the hemangioma has the lowest chance of recurrence, ruling out other pathology. Enucleation is often preferred as the hemangioma is a benign lesion and to preserve a normal liver. Enucleation has the advantage of lower blood loss, bile leak, and overall complications. Formal hepatectomy can be considered in the case of atypical hemangioma and large lesions deep in the liver [11].

Various methods to reduce blood loss have been described in the literature. The use of preoperative CT/magnetic resonance imaging scans, 3D imaging, intraoperative ultrasound, and indocyanine green fluorescence has helped in better delineation of liver lesions and avoiding larger blood vessels [12]. Continuous

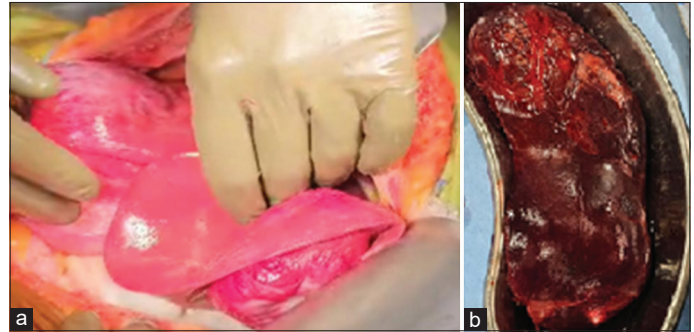


Figure 2: (a) Intraoperative picture of hemangioma involving both the right and left lobe liver. (b) Resected right lobe specimen

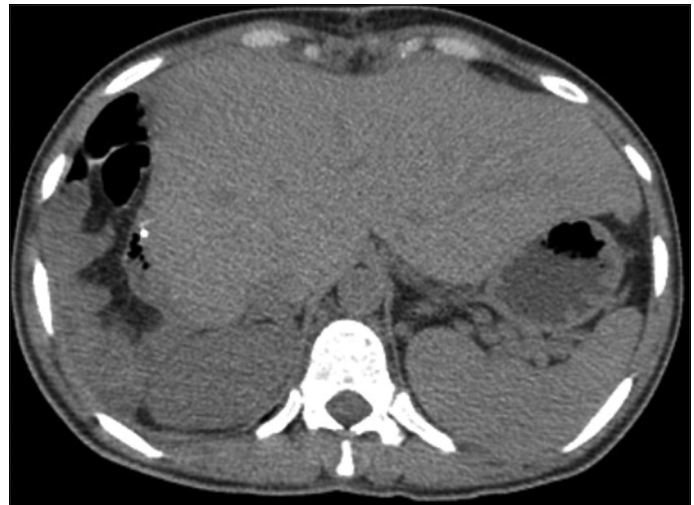

Figure 3: Plain computed tomography of the abdomen showing hypertrophy of the liver

or intermittent Pringle maneuver has been used for a long time in liver resections to minimize blood loss [13]. Ultrasonic shears, use of staplers, water-jet, and CUSA have been used for transection to reduce blood loss. Bleeding from raw surfaces can be reduced using various methods, such as suturing, argon beam coagulation, fibrin sealant, and cyanoacrylate [14]. IBSA has been studied in liver resections and transplantation and found to have reduced allogeneic blood transfusion requirements without compromising the overall outcome. Cost analysis also favors the use of IBSA [15]. Intraoperative whole blood removal with acute normovolemic hemodilution and low CVP has been described in the Jehovah's witness population as a transfusion-free strategy that can be extended to all patients to improve outcomes [16]. In our patient, we have taken utmost care to avoid blood transfusion. With the use of meticulous surgical technique, use of IBSA, and coordinated anesthesia care, we were able to avoid blood transfusion. Due to the risk of blood loss, the patient was not subjected to surgery and was treated with recurrent iron and erythropoietin injections. Following surgery, the patient was healthy with no fall in hemoglobin.

CONCLUSION

Hepatic hemangioma is the most common benign lesion of the liver. Most of the patients are asymptomatic and managed

conservatively. Kasabach–Merritt syndrome is a rare presentation of hemangioma that necessitates treatment. Aborting surgery, thinking of it as a morbid procedure, is no longer appropriate. Now, with meticulous surgical technique using CUSA, low CVP, IBSA, and good teamwork, excellent outcomes can be achieved even in a high-risk patient.

ACKNOWLEDGMENT

We thank all the faculty of Cytecure Hospital for their support in treating the patient and preparing this article. We have not received any funds to prepare this article.

REFERENCES

1. Bajenaru N, Balaban V, Săvulescu F, Campeanu I, Patrascu T. Hepatic hemangioma -Review. *J Med Life* 2015;8:4-11.
2. Ketchum WA, Lin-Hurtubise KM, Ochmanek E, Ishihara K, Rice RD. Management of symptomatic hepatic “Mega” hemangioma. *Hawaii J Med Public Health* 2019;78:128-31.
3. Reddy KR, Kligerman S, Levi J, Livingstone A, Molina E, Franceschi D, *et al.* Benign and solid tumors of the liver: Relationship to sex, age, size of tumors, and outcome. *Am Surg* 2001;67:173-8.
4. Szlachetka DM. Kasabach-merritt syndrome: A case review. *Neonatal Netw* 1998;17:7-15.
5. Maguiness S, Guenther L. Kasabach-merritt syndrome. *J Cutan Med Surg* 2002;6:335-9.
6. Klotz T, Montoriol PF, Da Ines D, Petitcolin V, Joubert-Zakeyh J, Garcier JM. Hepatic haemangioma: Common and uncommon imaging features. *Diagn Interv Imaging* 2013;94:849-59.
7. Colakoğlu O, Taşkıran B, Yazıcı N, Buyraç Z, Unsal B. Safety of biopsy in liver hemangiomas. *Turk J Gastroenterol* 2005;16:220-3.
8. Pietrabissa A, Giulianotti P, Campatelli A, Di Candio G, Farina F, Signori S, *et al.* Management and follow-up of 78 giant haemangiomas of the liver. *Br J Surg* 1996;83:915-8.
9. Tak WY, Park SY, Jeon SW, Cho CM, Kweon YO, Kim SK, *et al.* Ultrasonography-guided percutaneous radiofrequency ablation for treatment of a huge symptomatic hepatic cavernous hemangioma. *J Clin Gastroenterol* 2006;40:167-70.
10. Seo HI, Jo HJ, Sim MS, Kim S. Right trisegmentectomy with thoracoabdominal approach after transarterial embolization for giant hepatic hemangioma. *World J Gastroenterol* 2009;15:3437-9.
11. Singh RK, Kapoor S, Sahni P, Chattopadhyay TK. Giant haemangioma of the liver: Is enucleation better than resection? *Ann R Coll Surg Engl* 2007;89:490-3.
12. Berardi G, Colasanti M, Meniconi RL, Ferretti S, Guglielmo N, Mariano G, *et al.* The applications of 3D imaging and indocyanine green dye fluorescence in laparoscopic liver surgery. *Diagnostics (Basel)* 2021;11:2169.
13. Van den Broek MA, Bloemen JG, Dello SA, van de Poll MC, Olde Damink SW, Dejong CH. Randomized controlled trial analyzing the effect of 15 or 30 min intermittent Pringle maneuver on hepatocellular damage during liver surgery. *J Hepatol* 2011;55:337-45.
14. Moggia E, Rouse B, Simillis C, Li T, Vaughan J, Davidson BR, *et al.* Methods to decrease blood loss during liver resection: A network meta-analysis. *Cochrane Database Syst Rev* 2016;10:CD010683.
15. Lemke M, Eeson G, Lin Y, Tarshis J, Hallet J, Coburn N, *et al.* A decision model and cost analysis of intra-operative cell salvage during hepatic resection. *HPB (Oxford)* 2016;18:428-35.
16. Kulkarni S, Parina R, Henderson R, Derek E, Selby T, Kwon Y, *et al.* Transfusion-free strategies in liver and pancreatic surgery: A predictive model of blood conservation for transfusion avoidance in mainstream populations. *Ann Surg* 2023;277:469-74.

Funding: Nil; Conflicts of interest: Nil.

How to cite this article: Naragund AV, Kumar SS, Muddasetty R. Jehovah playing his part: A tale of giant hemangioma – Can we do major liver resections without blood or blood products? *Indian J Case Reports*. 2024; June 10 [Epub ahead of print].