

## Navigating the uncommon: Goblet cell adenocarcinoma of appendix with brief review of literature

Uttapalla Laxmi Trivedi<sup>1</sup>, Mayurakshi Das<sup>1</sup>, Anuradha Sekaran<sup>2</sup>, Siddanth Mathur<sup>3</sup>, G V Rao<sup>3</sup>

From <sup>1</sup>Consultant, <sup>2</sup>Director and Head, Department of Pathology, <sup>3</sup>Consultant, Department of Surgical Gastroenterology, AIG Hospitals, Hyderabad, Telangana, India

### ABSTRACT

Goblet cell adenocarcinoma (GCA) is a rare gastrointestinal malignancy with biological behavior intermediate between well-differentiated neuroendocrine tumor and adenocarcinoma. A succinct description of GCA has been made in the 5<sup>th</sup> edition of the World Health Organization classification of Digestive system tumors, after being decamped from the carcinoid group. Here, we present the case of a 44-year-old male, who presented with pain and abdominal distension and was found to have ileal stricture and subsequently underwent ileocecal resection. Histopathological examination revealed wall of the appendix infiltrated by a tumor, arranged predominantly in tubules (70%) and composed of goblet-like mucinous cells. Focal high-grade component (30%) of signet ring cells noted. Immunohistochemistry highlighted an amphicrine immunoprofile of diffuse CK20 and CDX2 immunopositivity and focal positivity for synaptophysin and chromogranin in the same tumor population. We also discuss the review of recent literature on cases of GCA and discuss its salient histological features, immunoprofile, and differential diagnoses.

**Key words:** Amphicrine carcinoma, Carcinoid, Goblet cell adenocarcinoma

Goblet cell adenocarcinoma (GCA) is a rare malignant neoplasm that shows amphicrine differentiation with predominantly goblet-like mucinous cells with a fewer number of endocrine cells and Paneth cells [1]. The most common clinical presentations are those mimicking acute appendicitis or bowel obstruction [2]. The cells of origin of GCA are both mucin-producing goblet cells and enterochromaffin cells which secrete neurosecretory granules attributing to the neuroendocrine differentiation of tumor. Ultrastructural studies have shown the presence of mucin production and pleomorphic neuroendocrine granules in the same cells [3]. GCA is common in the digestive system and the most common site is appendix, as in our case, the current system of three tiered gradings proposed by the World Health Organization (WHO) is based on the percentage of low-grade components [4] (Table 1) and is a reworking of the one proposed by Tang *et al.* [5].

According to recent literature, the worldwide incidence of GCA is 0.03–0.3 cases for 100,000 population, and the incidence of GCA in India is still not established. The mean age of presentation is 5<sup>th</sup>–6<sup>th</sup> decade with slightly female preponderance [1]. The treatment modality followed currently is ileocecal resection or


right hemicolectomy followed by chemotherapy. Case reports of GCA have been published under different names because of the multiple nosological jumps including goblet cell carcinoid to the recent GCA. The overall survival rate and prognosis depend on the grade and stage of the tumor, with higher stages heralding a poor prognosis.

Here, we present a case of incidentally diagnosed intermediate-grade GCA in an ileocecal resection specimen discussing the prime histological, and immunohistochemical findings and a brief review of recent literature in the English language on GCA. Even in a tertiary referral center for gastrointestinal pathology in India, this is the single case of GCA seen over a period of 1 year, and here lies the importance of documenting the case that will aid in determining a region-specific incidence rate.

### CASE REPORT

A 44-year-old male presented with abdominal distension and bilious vomiting for 4 days which was evaluated elsewhere and contrast-enhanced computed tomography abdomen showed ileocecal stricture.

On general physical examination, vitals were stable and the patient was afebrile. A provisional clinical diagnosis of infective versus inflammatory bowel disease was considered in view

Access this article online	
Received - 25 March 2024 Initial Review - 09 April 2024 Accepted - 10 May 2024	Quick Response code 
DOI: ***	

**Correspondence to:** Dr. Anuradha Sekaran, Department of Pathology, Tower B, 3<sup>rd</sup> Floor, AIG Hospitals, Gachibowli, Hyderabad - 500 082, Telangana, India. E-mail: sanuradha\_dr@yahoo.co.in

© 2024 Creative Commons Attribution-NonCommercial 4.0 International License (CC BY-NC-ND 4.0).

of the acute abdomen and the presence of imaging findings of stricture. Tumor markers or colonoscopic examinations were not performed.

Subsequent ileocecal resection was done and no intraoperative peritoneal deposits, adhesions, or mass lesions were noted. On gross examination of the specimen, there was a circumferential stricture in the ileocecal junction and appendix with luminal narrowing.

Microscopic examination revealed circumferential involvement of the wall of the appendix (Fig. 1a), cecum, and ileum with a transmural infiltration by tumor predominantly arranged in tubules (70%) and composed of goblet-like mucinous cells along (Fig. 1b) with focal areas of Paneth-like cells. Focal area (approximately 30% of the total tumor area) showed a high-grade component of signet ring cells (Fig. 1c). Extensive perineural invasion was noted, along with the absence of lymphovascular invasion and desmoplastic stroma. No evidence of organoid nests of monomorphic round cells and extra-cellular mucin pools was noted. Immunohistochemistry highlighted an amphicrine profile of diffuse CK20 and CDX2 immunopositivity and focal (10%) (Figure 2) immunopositivity for synaptophysin and chromogranin in the same tumor population. After extensive dissection, only three lymph nodes were retrieved and were negative for metastasis.

Based on this, a final diagnosis of intermediate-grade GCA of the appendix was made. The post-operative period was uneventful and the patient was advised eight cycles of adjuvant chemotherapy. At the 3-month follow-up, the patient was disease-free with no residual or metastatic disease.

## DISCUSSION

GCA of the appendix is a unique appendiceal tumor that shows features intermediate between adenocarcinoma of the appendix and neuroendocrine tumor. We did a meticulous online search in Google Scholar for case series, review articles, and case reports of GCA in indexed English language journals for the past 10 years (2014–2024), and reviewed them to evaluate the morphological

findings, differential diagnoses age, gender predilection, pathological stage, and prognosis of GCA (Table 2).

In 2022 Palmer *et al.*, in their review of the literature of 1225 cases of GCA mentioned an incidence of 0.03–0.3 cases for a 100,000 population [1]. In all of the above studies, the median age of presentation noted is the 5<sup>th</sup> decade [6–8]. No definite gender predilection was observed in most studies; however, slight female predilection was noted in cases with disseminated disease [8,9].

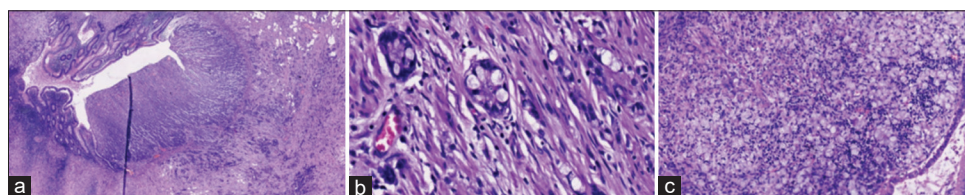
The majority of the cases presented with acute abdomen and/or abdominal mass/enlarged appendix on imaging. Acute appendicitis and perforation were common presentations in the case of low-grade disease and abdominal mass in the case of high-grade disease [2]. Right hemicolectomy was the treatment modality in the majority of the cases, despite a few cases with lymph node positivity and distant metastasis requiring adjuvant chemotherapy.

We have also evaluated salient histological findings to accurately diagnose GCA and to rule out other differential diagnoses of mucinous adenocarcinoma and mixed neuroendocrine-non-neuroendocrine neoplasm (MiNeN). The histological findings that aided us in diagnosis include variable low-grade component, that is, round tubule formation composed of goblet cells that resemble crypt of the intestine (Fig. 1a and 1b) admixed with a variable high-grade component comprising of solid growth pattern with signet ring cells in sheets, cords, or singly dispersed (Fig. 1c) along with the extensive perineural invasion. Absent/minimal desmoplastic stroma, and absence of dysplasia in adjacent mucosa and the presence of variable amount of Paneth cell metaplasia were also noted. Grading of GCA was first proposed by Tang *et al.* [5] and implemented and standardized by the recent 5<sup>th</sup> edition of WHO tumors of the digestive system (Table 1) along with the change of nomenclature from goblet cell carcinoid to GCA.

The main entities from which GCA should be differentiated are mucinous adenocarcinoma of appendix and also MiNeN. In MiNeN, both adenocarcinoma component is seen intimately admixed with the neuroendocrine tumor population, with each component comprising at least 30% of the total tumor area [5,10]. In the case of a predominantly high-grade component mimicking a mucinous adenocarcinoma or signet ring cell carcinoma, adequate sampling and careful inspection for the presence of a low-grade GCA tumor component will aid in the correct diagnosis of a high-grade GCA. However, there is no prognostic difference between a high-grade adenocarcinoma of mucinous

**Table 1: Histological Grading of GCA [3]**

GCA grade (WHO 5 <sup>th</sup> Edition of Digestive Tumours)	Proportion of tumour with low-grade tubular /clustered growth pattern (%)
Grade 1, Low grade	>75
Grade 2, Intermediate grade	50-75
Grade 3, High grade	<50

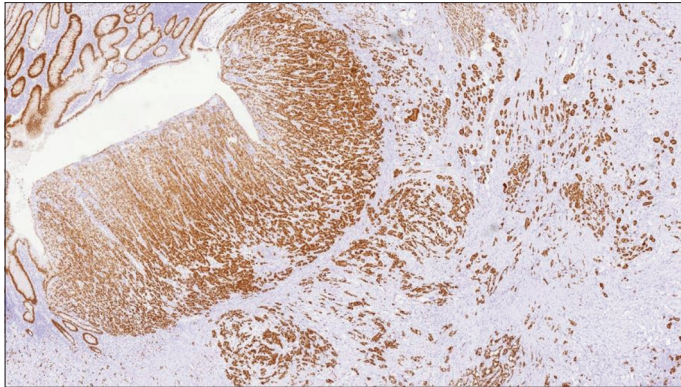


**Figure 1: Hematoxylin and eosin stain (a) shows circumferential and transmural involvement of the wall of the appendix with a tumor composed of tubules and absent surface mucosal dysplasia (10×); (b) shows goblet cells in tubules resembling normal intestinal crypts with absence of desmoplastic stroma (40×); (c) High-grade component comprising sheets of signet ring cells (40×)**

**Table 2: Demographic profile, radiology, and treatment modality of GCA case series**

S. No.	Case series	Sample size	Median age	Gender	Radiology	Clinical finding	Treatment modality
1	Palmer <i>et al.</i> [1]	1225	6 <sup>th</sup> decade	F=M	-	Abdominal pain	Right hemicolectomy
2	Wang <i>et al.</i> [6]	6	57	F=M	Acute appendicitis	Abdominal pain	Appendectomy followed by right hemicolectomy
3	Kiyosawa <i>et al.</i> [7]	3	58	F=M	Swollen appendix	Abdominal pain	Right hemicolectomy
4	Fields <i>et al.</i> [8]	2552	5 <sup>th</sup> decade	F>M		Abdominal pain	Right hemicolectomy
5	Olsen <i>et al.</i> [9]	83	59/58	F=M	Enlarged appendix	Abdominal pain	Right hemicolectomy

F: Female, M: Male

**Figure 2: CDX2 immunohistochemistry shows diffuse positivity in tumor cells**

type/signet ring cell type and a high-grade GCA. The prognosis depends on the pathologic stage and histologic grade of the disease. In all the above studies (Table 2), GCA shows amphicrine immunoprofile with diffuse expression for CDX2, CK20, and variable immunopositivity for neuroendocrine markers such as synaptophysin and chromogranin in the same population of tumor cells. As opposed to MiNeN, where two tumor populations with distinct neuroendocrine and non-neuroendocrine morphology and immune profile are admixed together, GCA shows an amphicrine immunoprofile with the same tumor cells exhibiting CK20, CDX2, and variable neuroendocrine markers. Our case showed a similar immunoprofile and no separate neuroendocrine tumor component was highlighted on immunohistochemistry.

## CONCLUSION

GCA is a relatively rare entity with multiple nosologic jumps. A careful histopathological examination will allow accurate identification and grading of the tumor and awareness of its amphicrine immunoprofile will prevent misdiagnosis as a MiNeN. Adequate sampling and careful examination for the low-grade component will aid in the accurate diagnosis of this relatively rare

entity and help in the determination of region-specific incidence rate.

## REFERENCES

- Palmer K, Weerasuriya S, Chandrakumaran K, Rous B, White BE, Paisey S, *et al.* Goblet cell adenocarcinoma of the appendix: A systematic review and incidence and survival of 1,225 cases from an English cancer registry. *Front Oncol* 2022;12:915028.
- Bell PD, Pai RK. Goblet cell adenocarcinoma of the appendix: An update and practical approach to diagnosis and grading. *Hum Pathol* 2023;132:183-96.
- Odze RD, Goldblum JR. *Surgical Pathology of the Gastrointestinal Tract, Liver, Biliary Tract, and Pancreas*. 3<sup>rd</sup> ed. Netherlands: Elsevier; 2015. p. 795-7.
- World Health Organization. *WHO Classification of Digestive System Tumours*. 5<sup>th</sup> ed., Vol. 1. Switzerland: World Health Organization; 2019. p. 149-51.
- Tang LH, Shia J, Soslow RA, Dhall D, Wong WD, O'Reilly E, *et al.* Pathologic classification and clinical behavior of the spectrum of goblet cell carcinoid tumors of the appendix. *Am J Surg Pathol* 2008;32:1429-43.
- Wang Y, Shahabi A, Loeffler A. Appendiceal goblet cell adenocarcinoma: A historically informed reading of 6 cases. *Arch Pathol Lab Med* 2022;146:1402-11.
- Kiyosawa N, Koyama M, Miyagawa Y, Kitazawa M, Tokumaru S, Soejima Y. Goblet cell adenocarcinoma of the appendix: A case report of three cases. *Int J Surg Case Rep* 2023;106:108229.
- Fields AC, Lu P, Enzinger A, Goldberg J, Irani J, Bleday R, *et al.* Treatment patterns and outcomes in goblet cell carcinoid tumors of the appendix. *J Surg Oncol* 2019;120:1096-101.
- Olsen IH, Holt N, Langer SW, Hasselby JP, Grønbaek H, Hillingsø J, *et al.* Goblet cell carcinoids: Characteristics of a Danish cohort of 83 patients. *PLoS One* 2015;10:e0117627.
- Taggart MW, Abraham SC, Overman MJ, Mansfield PF, Rashid A. Goblet cell carcinoid tumor, mixed goblet cell carcinoid-adenocarcinoma, and adenocarcinoma of the appendix: Comparison of clinicopathologic features and prognosis. *Arch Pathol Lab Med* 2015;139:782-90.

*Funding: Nil; Conflicts of interest: Nil.*

**How to cite this article:** Trivedi UL, Das M, Sekaran A, Mathur S, Rao GV. Navigating the uncommon: Goblet cell adenocarcinoma of appendix with brief review of literature. *Indian J Case Reports* 2024; May 24 [Epub ahead of print].