

Malignant peripheral nerve sheath tumor of the descending colon with peritoneal recurrence: A case report

Deoyani Prabhu Rane¹, Ashwini Mane Patil², Kiran Bagul³, Suraj B Pawar⁴

From ¹Fellow-Oncopathology Resident, ²Head, Department of Pathology, ³Chief Surgical Oncologist and Robotic Surgeon, Department of Surgical Oncology, ⁴Surgical Oncologist and Robotic Surgeon, Department of Surgery, Kolhapur Cancer Center, Kolhapur, Maharashtra, India

ABSTRACT

A malignant peripheral nerve sheath tumor (MPNST) is a malignant tumor arising from the peripheral nerve or displaying nerve sheath differentiation. Probably, only six cases have been reported as MPNST tumors arising in the colon. We report one such unique case of MPNST of the descending colon in a 61-year-old male who presented primarily with colicky abdominal pain for 1 month. Computed tomography (CT) showed a large mass in the descending colon. A left hemi-colectomy was performed, and a histopathological diagnosis of spindle cell sarcoma was made, which was confirmed as MPNST on immunohistochemistry (IHC). The patient again presented after 1 year with the same complaints of abdominal pain since 1 month. A CT scan revealed seven well-defined lesions in the peritoneal cavity, with the largest (8 cm) abutting the left kidney and one of the lesions abutting a small bowel segment. Exploratory laparotomy was performed with retroperitoneal mass excision and resection of the small intestine. The histopathological examination was suggestive of recurrent spindle cell sarcoma. The IHC showed S100 and CD56 positivity, which confirmed the diagnosis of recurrent MPNST.

Key words: Descending colon, Malignant peripheral nerve sheath tumor, Peritoneal Recurrence

A malignant peripheral nerve sheath tumor (MPNST) is a malignant tumor arising from the peripheral nerve or displaying nerve sheath differentiation. The most common sites of presentation of MPNST are the trunk, extremities, head, neck, and paravertebral regions. The gastrointestinal tract is an infrequent site for MPNST with the colon being even more erratic [1]. Approximately 2–6% of gastrointestinal tract stromal tumors comprise Schwannomas [2], with the stomach being the most frequent site of manifestation [3]. Schwannomas arising from the colon with the non-existence of neurofibromatosis (NF) or parasitic infection are exceptionally rare [3-6], with even infrequent malignant cases. Till now, only six cases have been reported of MPNST arising from the colon [1,7-11].

Here, we present one of the erratic cases of MPNST of the descending colon presented with peritoneal recurrence, without predecessor NF, or parasitic infection.

CASE REPORT

A 61-year-old male alcoholic patient, with a past history of treated pulmonary tuberculosis 7 years ago, with no evidence of

any history suggestive of neurofibromatosis Type 2 (NF2) and no other associated comorbidities, presented at our center for the first time with complaints of colicky abdominal pain, anorexia, weight loss, and indigestion for 1 month.

On examination, he was withered and pale. There was no icterus or palpable lymphadenopathy. Per abdominal examination revealed a palpable lump of 8 × 7 cm in the left lumbar and iliac regions.


Computed tomography (CT) evaluation showed a large infiltrative polypoidal mass showing heterogeneous hyperenhancement with internal non-enhancing areas measuring 8.4 × 6.6 × 5.0 cm in the descending colon with transmural involvement instigating partial intestinal obstruction.

The patient was planned for a left hemicolectomy. A midline incision was given, followed by dissection of the descending colon and ligation of major vessels with exploration of regional nodes. The specimen was sent for histopathological examination.

Gross examination revealed a polypoidal gray-white tumor measuring 9 × 6.5 cm involving the descending colon. On serial slicing, it was firm, gray-white, 3.5 cm in thickness, and involved subserosal fat while 0.1 cm away from the serosa. Multiple hematoxylin and eosin-stained sections studied through the colon mass revealed a tumor comprising hypocellular and hypercellular areas (Fig. 1a). Individual tumor cells are plump oval to spindle cells exhibiting vesicular chromatin and nucleoli

Correspondence to: Deoyani Prabhu Rane, Department of Pathology, Kolhapur Cancer Center, Maharashtra, India. E-mail: 1207deo@gmail.com

© 2024 Creative Commons Attribution-NonCommercial 4.0 International License (CC BY-NC-ND 4.0).

Access this article online	
Received - 25 March 2024 Initial Review - 09 April 2024 Accepted - 08 May 2024	Quick Response code 
DOI: 10.32677/ijcr.v10i6.4555	

surrounded by pale cytoplasm arranged in sheets and fascicles. Nuclear pleomorphism was observed along with areas of necrosis (Fig. 1b). Mitotic activity was 12–13/10 high power field. It involved up to subserosal fat, with the serosa being close (1 mm) but free of tumors. Lymphovascular emboli or perineural invasion was not seen, and both surgical margins of resection along with nodes were free of tumors. Features were suggestive of spindle cell sarcoma. On immunohistochemistry (IHC), these neoplastic cells were positive for S 100 (Fig. 2a) and CD 56 (Fig. 2b) while negative for smooth muscle actin (Fig. 2c), desmin, cytokeratin, TLE 1, Bcl 2, CD 99, Calponin, C kit (Fig. 2d), and DOG 1. Based on this, a final diagnosis of MPNST was made.

After 1 year, the patient again presented with the same complaints of colicky abdominal pain for 1 month, and an urgent CT scan was done, revealing seven large, heterogeneously enhancing, lobulated masses in the left paracolic region, extending down to the left iliac fossa, with the largest measuring 8 cm, abutting the left kidney at the lower pole. One of the masses in the lower abdomen in the midline region is abutting and displacing small bowel loops. An exploratory laparotomy was performed with a midline incision. Retroperitoneal deposits at the left paracolic gutter, pelvic, para-aortic, and omental deposits were removed along with/and resection of the distal ileum. Histopathological examination revealed a similar lesion, which was suggestive of recurrent spindle cell sarcoma. IHC showed S100 and CD56 positivity (Figs. 2a and 2b consecutively), which confirmed the diagnosis of recurrent MPNST. Thereafter, the

patient was planned for six cycles of adjuvant chemotherapy comprising of ifosfamide and adriamycin. The patient had completed four chemotherapy cycles, last received in October 2023, and thereafter, the patient defaulted.

DISCUSSION

The World Health Organization has defined MPNST as a tumor arising from the peripheral nerve or displaying nerve sheath differentiation. They are the sixth most common type of soft-tissue sarcoma [12,13]. They are of two types: sporadic, constituting about half of all MPNST cases, while others are allied with NF1 [14,15].

The most common sites of presentation of MPNST are the trunk, extremities, head, neck, and paravertebral regions. Till now, only 20 cases of MPNST of the tubular tract have been cited in the literature, of which only six cases were devised from the colon [1,7-11]. Ordinarily, colonic cases are allied with von Recklinghausen disease [10] or *Schistosoma japonicum* infection [11], which was not the case in our report.

MPNST colon presents at a varied age range from about 2 days to 60 years with no characteristic clinical features. Our case is a 61-year-old man who presented with abdominal pain. Owing to this, a pre-operative diagnosis of MPNST is fairly challenging and hindered.

Malignant gastrointestinal stromal tumors (GIST) and leiomyosarcoma are differentials for gastrointestinal mesenchymal tumors. The majority of GISTs in the colon are positive for c-kit and CD34, but none show S-100 positivity. However, leiomyosarcoma is negative for CD34 and c-kit, but most cases show SMA, desmin, or both positivity [16]. Our case was positive for S 100 and CD 56 while negative for smooth muscle actin, desmin, cytokeratin, TLE 1, Bcl 2, CD 99, calponin, C kit, and DOG 1. These findings were in contrast to GIST, or smooth muscle tumors.

MPNST of soft tissue has a local recurrence rate of about 40–65%, while the metastatic rate is 30–60% that to within 1 year of surgery [17]. Factors responsible for local recurrence are tumor site, size (>10 cm), and adequacy of surgical margins. Factors responsible for metastasis are tumor size (>10 cm) and stage (stage III, according to the American Joint Committee on Cancer) [17]. The lung, liver, brain, bone, and adrenal gland are the most common sites of metastasis [17]. To date, there is scarce knowledge about intestinal MPNST, which is thought to have an even more adverse prognosis than its soft-tissue analog, as in our case, which presented with peritoneal recurrence within 1 year of surgical resection.

Due to its erratic occurrence, the prime treatment of MPNST in the colon is not well recognized [8]. The contemporary standard approach for MPNST is complete surgical resection with wide negative margins [17]. Adjuvant therapy's role is quite controversial. Adjuvant radiotherapy is preferred where clear surgical margins are difficult to attend, but it will not benefit the MPNST colon due to its location, which causes stricture formation and restricted mobility [18,10]. Promising results have been

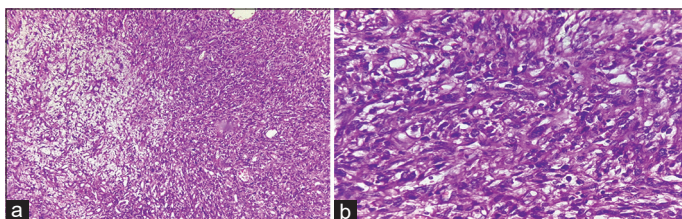


Figure 1: Hematoxyline and eosin stained slide shows (a) hypocellular and hyper cellular areas giving marbled appearance of elongated to spindle shaped tumor cells; (b) tumor cells having elongated hyperchromatic nuclei and mild to moderate amount of cytoplasm, showing pleomorphism and atypia with perivascular accentuation

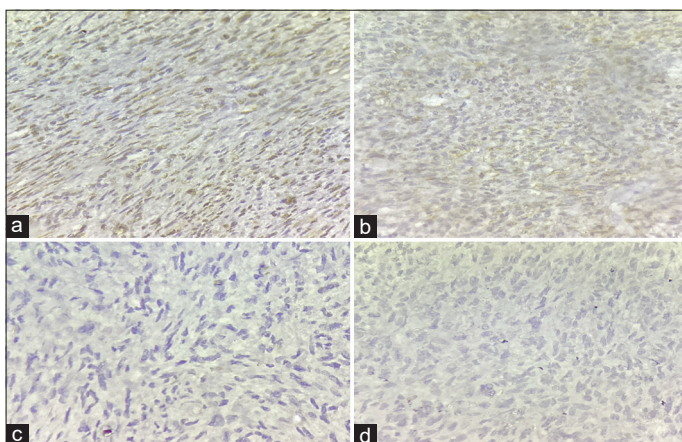


Figure 2: Immunohistochemistry shows (a) focal positivity for S100; (b) focal positivity for CD56; (c) negativity for SMA; (d) negativity for C-kit

reported for first-line chemotherapy in the MPNST colon from a recent meta-analysis of pooled data from 12 trials [19]. Recently, targeted therapy using molecular pathways has been developed for MPNST, but it requires further study [20]. Hence, proper management of such tumors requires a multidisciplinary approach, or else the patient will develop recurrence, as in our case.

CONCLUSION

This is one of the erratic cases of MPNST in the descending colon presented with peritoneal recurrence. Due to its infrequent presentation, a pre-operative diagnosis of MPNST is fairly challenging. However, in a patient with a mesenchymal tumor, even at infrequent sites like the colon, the prospect of MPNST should always be deliberated. This diagnosis has extensive connotations since the projection of patients has been considered momentous compared to other mesenchymal tumors of the colon.

REFERENCES

- Rawal G, Zaheer S, Ahluwalia C, Dhawan I. Malignant peripheral nerve sheath tumor of the transverse colon with peritoneal metastasis: A case report. *J Med Case Rep* 2019;13:15.
- Daimaru Y, Kido H, Hashimoto H, Enjoji M. Benign schwannoma of the gastrointestinal tract: A clinicopathologic and immunohistochemical study. *Hum Pathol* 1988;19:257-64.
- Prevot S, Bienvenu L, Vaillant JC, de Saint-Maur PP. Benign schwannoma of the digestive tract: A clinicopathologic and immunohistochemical study of five cases, including a case of esophageal tumor. *Am J Surg Pathol* 1999;23:431-6.
- Hirose T, Scheithauer BW, Sanot T. Giant plexiform schwannoma: A report of two cases with soft tissue and visceral involvement. *Mod Pathol* 1997;10:1075-81.
- Sasatomi T, Tsuji Y, Tanaka S, Horiuchi H, Hyodo S, Takeuchi K, *et al.* Schwannoma in the sigmoid colon: Report of a case. *Kurume Med J* 2000;47:165-8.
- Skopelitou AS, Mylonakis EP, Charchanti AV, Kappas AM. Cellular neurilemoma (Schwannoma) of the descending colon mimicking carcinoma: Report of a case. *Dis Colon Rectum* 1998;41:1193-6.
- Park YS, Lim SJ, Kim WH, Ham EK. Malignant peripheral nerve sheath tumor in descending colon - A case report. *Korean J Pathol* 2002;36:179-83.
- Lee YJ, Moon H, Park ST, Ha WS, Choi SG, Hong SC, *et al.* Malignant peripheral nerve sheath tumor arising from the colon in a newborn: Report of a case and review of the literatures. *J Pediatr Surg* 2006;41:e19-22.
- Atsumi Y, Rino Y, Tamagawa H, Sato T, Inagaki D, Yukawa N, *et al.* A case of epithelioid malignant peripheral nerve sheath tumor spreading of transverse colon with von Recklinghausen disease. *Nihon Gekakei Rengo Gakkaishi (J Jpn Coll Surg)* 2014;39:94-100.
- Marwah S, Gurawalia JP, Dev Sheoran K, Marwah N, Gupta S, Ranga H. Malignant peripheral nerve sheath tumor of the colon in a patient with von Recklinghausen's disease: Report of a case. *Clin J Gastroenterol* 2013;6:429-33.
- Schwartz DA. Malignant schwannoma occurring with *Schistosoma japonicum*: A case report. *Southeast Asian J Trop Med Public Health* 1982;13:601-5.
- Grobmyer SR, Reith JD, Shahlaee A, Bush CH, Hochwald SN. Malignant peripheral nerve sheath tumor: Molecular pathogenesis and current management considerations. *J Surg Oncol* 2008;97:340-9.
- Fuchs B, Spinner RJ, Rock MG. Malignant peripheral nerve sheath tumors: An update. *J Surg Orthop Adv* 2005;14:168-74.
- Ducatman BS, Scheithauer BW, Piepgras DG, Reiman HM, Ilstrup DM. Malignant peripheral nerve sheath tumors. A clinicopathologic study of 120 cases. *Cancer* 1986;57:2006-21.
- Bradtmoeller M, Hartmann C, Zietsch J, Jäschke S, Mautner VF, Kurtz A, *et al.* Impaired Pten expression in human malignant peripheral nerve sheath tumours. *PLoS One* 2012;7:e47595.
- Miettinen M, Sarlomo-Rikala M, Sobin LH, Lasota J. Gastrointestinal stromal tumors and leiomyosarcomas in the colon: A clinicopathologic, immunohistochemical, and molecular genetic study of 44 cases. *Am J Surg Pathol* 2000;24:1339-52.
- James AW, Shurell E, Singh A, Dry SM, Eilber FC. Malignant peripheral nerve sheath tumor. *Surg Oncol Clin N Am* 2016;25:789-802.
- Kahn J, Gillespie A, Tsokos M, Ondos J, Dombi E, Camphausen K, *et al.* Radiation therapy in management of sporadic and neurofibromatosis type 1-associated malignant peripheral nerve sheath tumors. *Front Oncol* 2014;4:324.
- Kroep JR, Ouali M, Gelderblom H, Le Cesne A, Dekker TJ, Van Glabbeke M, *et al.* First-line chemotherapy for malignant peripheral nerve sheath tumor (MPNST) versus other histological soft tissue sarcoma subtypes and as a prognostic factor for MPNST: An EORTC Soft Tissue and Bone Sarcoma Group study. *Ann Oncol* 2011;22:207-14.
- Farid M, Demicco EG, Garcia R, Ahn L, Merola PR, Cioffi A, *et al.* Malignant peripheral nerve sheath tumors. *Oncologist* 2014;19:193-201.

Funding: Nil; Conflicts of interest: Nil.

How to cite this article: Rane DP, Patil AM, Bagul K, Pawar SB. Malignant peripheral nerve sheath tumor of the descending colon with peritoneal recurrence: A case report. *Indian J Case Reports*. 2024; 10(6):173-175.