

## Cystic myoepithelioma of parapharyngeal space: A rare case report

Jagannath D Sharma<sup>1</sup>, Upasana Kalita<sup>2</sup>, Muktanjalee Deka<sup>3</sup>, Barasha S Bharadwaj<sup>4</sup>, Adahra Patricia Beso<sup>5</sup>, Nandakanta Mahanta<sup>6</sup>, Ekaparna Hazarika<sup>2</sup>, Madhusmita Choudhury<sup>2</sup>, Neeharika Phukan<sup>7</sup>

From <sup>1</sup>Professor, <sup>2</sup>Fellow, <sup>3</sup>Head and Professor, <sup>4</sup>Assistant Professor, <sup>5</sup>Assistant Professor, <sup>6</sup>Demonstrator, <sup>7</sup>Senior Resident, Department of Oncopathology, State Cancer Institute, GMCH, Guwahati, Assam, India

### ABSTRACT

Myoepitheliomas are generally encapsulated, slowly-growing, asymptomatic, solid masses in which more than 50% are seen in the parotid gland. Cystic myoepitheliomas are very rare. We present the case of a 30-year-old man with a cystic mass in the right parapharyngeal space who had undergone wide local excision. In gross examination, a cystic mass was observed. Microscopically, tumors consisted of cells with varied morphology, like round to epithelioid, spindly, plasmacytoid, and clear cells arranged in solid, reticular, and small groups in a hyalinized stroma. Cells show mild to moderate nucleomegaly and atypia. Immunohistochemically, cells were immunoreactive to cytokeratin, S100, smooth muscle actin (focally), P40, and the low ki67 index (1%). We are presenting this case as it is a rare entity, and a very small number of cases have been reported in the literature. It is a rare parapharyngeal tumor presented with a very good and unremarkable post-operative course.

**Key words:** Cystic myoepithelioma, Myoepithelioma, Parapharyngeal space tumor

Myoepitheliomas are rare tumors arising from the myoepithelial cells [1]. The most common site of origin of myoepitheliomas is the salivary glands and rarely other sites in the head and neck [2]. Myoepitheliomas may be locally aggressive, especially in long-standing tumors or in tumors with multiple recurrences [3]. Cystic myoepitheliomas of the parapharyngeal space (PPS) are very rare. Myoepitheliomas arising from the PPS are challenging from both diagnostic and therapeutic points of view [1].

### CASE REPORT

A 30-year-old gentleman came to the department of surgery, GMCH, complaining of swelling in the oral cavity and lower right side of the neck for 2 months. The patient also had pain and dysphagia to solid food. It was associated with the change of voice. The patient also had pain in the right ear and right-sided neck region. The patient was a known smoker, alcoholic, and tobacco user for 10 years. The patient is non-diabetic and non-hypertensive. The patient had no other significant history.


The patient was of normal weight, and vitals were found to be within the normal range. Upon per oral examination, a 5 × 3 cm-sized cystic swelling was noted in the right tonsillar

fossa, pushing the palatine tonsil medially. It was tense and reddish in color. Clinically, the swelling was thought to be a peritonsillar abscess.

The patient was advised to have an ultrasonography (USG) and computed tomography (CT) scan of the neck. USG of the neck revealed a 5 × 4.5 cm-sized complex lesion showing a solid cystic component in the right submandibular region. No internal vascularity was noted. The thyroid and salivary glands were found to be normal. Contrast-enhanced CT revealed fairly well-defined peripherally enhancing collection in the right peritonsillar space with extension, mass effect, and luminal narrowing of the airway suggestive of abscess formation. Magnetic resonance imaging (MRI) of the neck revealed a hyperintense cystic lesion epicenter in the right PPS, abutting the deep parotid lobe and internal carotid artery.

The patient was referred to the Department of Head and Neck, State Cancer Institute. USG-guided fine-needle aspiration cytology was done where brownish fluid was aspirated and revealed a cystic lesion with hemorrhage. A wide local excision of the cystic lesion was done, and the specimen was sent in 10% neutral buffered formalin to the Department of Oncology, State Cancer Institute for histopathological examination (HPE).

Gross examination showed a cystic structure measuring 7.5 × 4.5 × 4 cm in size, encapsulated, and smooth outer surface.

Access this article online	
Received - 25 March 2024 Initial Review - 09 April 2024 Accepted - 24 May 2024	Quick Response code 
DOI: 10.32677/ijcr.v10i7.4553	

**Correspondence to:** Upasana Kalita, Fellow, Department of Oncopathology, State Cancer Institute, GMCH, House No 12, Bishnu Path, Brahmakumari, Near Kali Mandir, Hengrabari, Guwahati, PO - 781036, Assam, India. E-mail: upasanakalita.uk@gmail.com

© 2024 Creative Commons Attribution-NonCommercial 4.0 International License (CC BY-NC-ND 4.0).

Upon cut sectioning, it was multiloculated containing a brownish-clear fluid. The cyst wall was variable in thickness, with a maximum thickness measuring 1 cm. Occasional solid areas were noted, the largest measuring  $1.5 \times 1 \times 0.3$  cm (Fig. 1).

Microscopic examination of the solid area and the cyst wall showed a well-circumscribed neoplasm with a thin capsule. It was composed of cells with varied morphologies, like round to epithelioid, spindly, plasmacytoid, and clear cells arranged in solid, reticular, and small cell groups. The cells showed mild to moderate nucleomegaly and atypia. The stroma was hyalinized, fibrous, and focally myxoid. Areas of cystic degeneration were noted. No tumor necrosis was seen. Mitosis: 3–4/10 hpf. The margin was free of tumors (Fig. 2).

Immunohistochemistry (IHC) was done where the tumor cells were immunoreactive to cytokeratin, S100, smooth muscle actin (focally), P40, and low ki67 index (1%). Synaptophysin and chromogranin were found to be negative (Fig. 3). HPE and IHC suggest cystic myoepithelioma of the PPS.

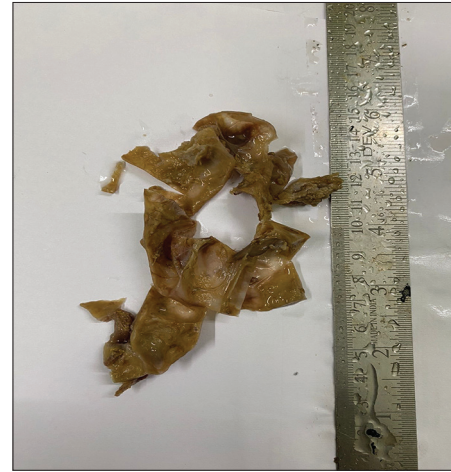
## DISCUSSION

PPS is a complex anatomic region located between the mandibular ramus and lateral pharynx and extending as an inverted pyramid from the skull base superiorly to the hyoid bone inferiorly. Cranial nerves IX, X, XI, and XII, the carotid artery, the sympathetic chain, the jugular vein, and lymph nodes are located here [4]. The prevalence of tumors of the PPS rates for 0.5–0.8% of all head-and-neck tumors [3]. Most of these tumors (70–80%) are benign in origin, of which 40–50% originate in the salivary glands, commonly as pleomorphic adenomas. They may arise from the deep lobe of the parotid and extend through the stylomandibular tunnel into the PPS, or they can develop *de novo*.

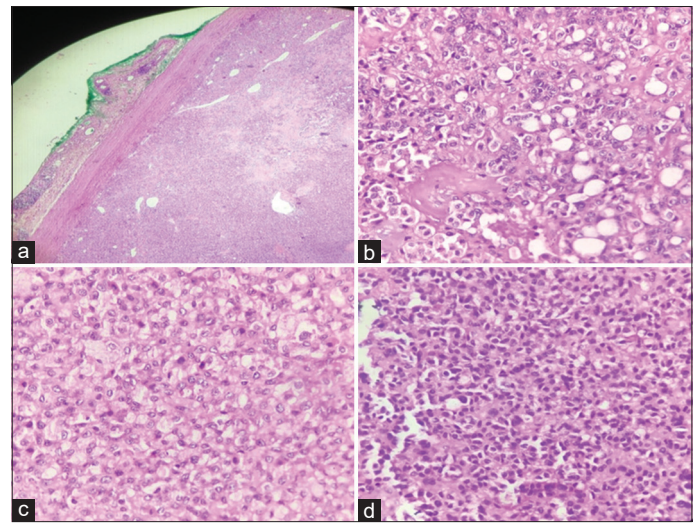
Surgical treatment of PPS tumors may be challenging due to the wide spectrum of both benign and malignant tumors and also due to the complex anatomic relationships and proximity of vital neurovascular structures within the PPS. It may also not be possible or feasible to determine the exact etiology of a PPS tumor, preoperatively. To minimize patient morbidity from surgical resection, a firm knowledge of anatomy, a strategy for pre-operative evaluation of each patient, and mastery of different surgical approaches to the PPS are essential [5]. Due to the development of endoscopic technology and imaging, surgical approaches for PPS lesions have been extended. The increasing demand for cosmetic purposes has promoted minimally invasive and aesthetic surgical procedures for this area [6].

A variant of pleomorphic adenoma called myoepithelioma was first described by Sheldon in 1943. Recognized as a distinct entity by the World Health Organization in 1991. These are rare tumors that account for about 1% of all salivary gland tumors [1]. Myoepithelioma arising from PPS provides both a diagnostic and therapeutic challenge because of its rarity and location.

Myoepithelioma is an uncommon tumor of the minor salivary glands (1% of all salivary gland neoplasms). They arise from



**Figure 1:** (a) Gross picture of an already sectioned swelling, showing a cystic wall after aspiration of its content. Few solid whitish areas were noted



**Figure 2:** (a) Microscopic examination (low power view) showing a cystic wall with thin fibrous capsule. Green colored is the inked margin which is free of tumor; (b) Round to epithelioid cells in solid and small groups. Areas of cystic degeneration noted; (c and d) High power view showing varied cell morphology, such as round, epithelioid, spindle, and plasmacytoid. Cells show mild to moderate nucleomegaly and atypia. Occasional mitotic figures were noted

myoepithelial cells, which are normal constituents of the salivary acini and ducts and are found between the epithelial cells and the basement membrane. The most common site of origin is the salivary glands and rarely other sites in the head and neck. No gender preponderance is seen and the average age is 40 years [2]. Diagnosis is mainly through histopathology examination, which will show either a plasmacytoid or a spindle cell appearance or a mixture of both. A wide local surgical excision with adequate clear margins is the recommended treatment of choice. A recurrence rate of 15–18% is observed [1]. In CT, myoepitheliomas are characterized as well-circumscribed small, unilocular, round tumors with smooth or lobulated contours; they may contain enhancing nodules and non-enhancing areas and exhibit homogeneous signal intensities or densities based on MRI. MRI is superior to CT in the investigation of PPS tumors.

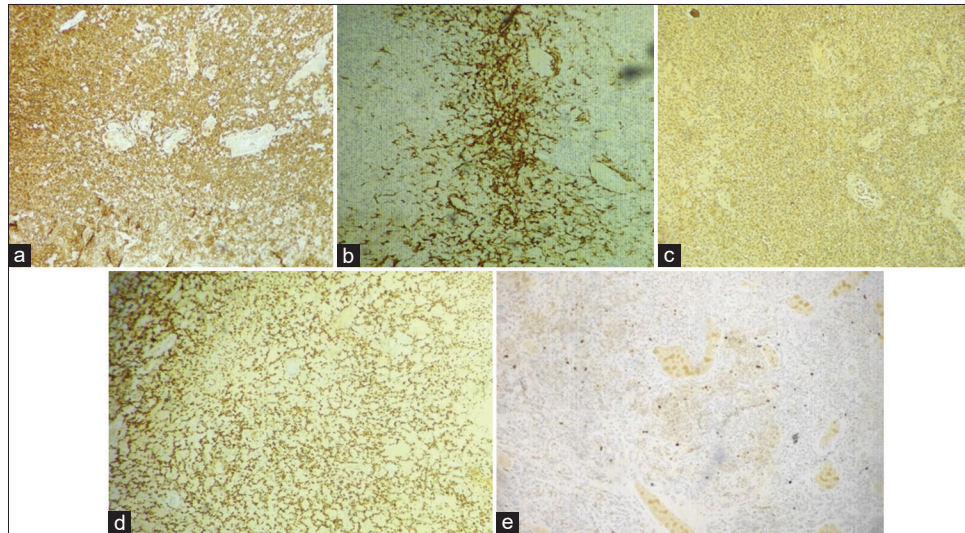


Figure 3: Tumor cells were immunoreactive to (a) cytokeratin (b) smooth muscle actin (focally), (c) S100, (d) P40, and (e) low ki67 index- 1%

## CONCLUSION

Cystic myoepithelioma arising from the PPS is very rare, providing both a diagnostic and therapeutic challenge. Diagnosis is mainly through HPE. Wide local surgical excision with adequate clear margins is the recommended treatment of choice. A recurrence rate of 15–18% is observed. Regular follow-up to evaluate for local recurrence is necessary.

## REFERENCES

1. Veluswamy S, Poondiyar Sirajuddin SH, Padmanabhan PP. Cystic myoepithelioma of parapharyngeal space. *Indian J Otolaryngol Head Neck Surg* 2019;71:689-92.
2. Salivary Gland Myoepithelioma. Available from: <https://www.pathologyoutlines.com/topic/salivaryglandsmyoepithelioma.html> [Last accessed on 2024 Jan 12].
3. Długosz-Karbowska A, Smółka W, Ciupińska-Kajor M, Markowski J. Myoepithelioma in the parapharyngeal space - Report of two cases and review of literature. *Pol Otorhinolaryngol Rev* 2021;10:36-40.
4. Lien KH, Young CK, Chin SC, Liao CT, Huang SF. Parapharyngeal space tumors: A serial case study. *J Int Med Res* 2019;47:4004-13.
5. Brown R, Ducic Y. Available from: <https://www.drducic.com/files/2019/05/parapharyngeal-space-tumor.pdf> [Last accessed on 2023 Dec 17].
6. Jiang C, Wang W, Chen S, Liu Y. Management of parapharyngeal space tumors: Clinical experience with a large sample and review of the literature. *Curr Oncol* 2023;30:1020-31.

*Funding: Nil; Conflicts of interest: Nil.*

**How to cite this article:** Sharma JD, Kalita U, Deka M, Bharadwaj BS, Beso AP, Mahanta N, *et al.* Cystic myoepithelioma of parapharyngeal space: A rare case report. *Indian J Case Reports*. 2024;10(7):197-199.