

## A rare case of giant uterus like mass arising from broad ligament: a case report with review of histogenesis

**Malini Goswami**

*From the Department of Oncology, Yenepoya Medical College, Deralakatte, Mangalore, India*

**Correspondence to:** Dr Malini Goswami, Meridian Apartments, Yenepoya Medical College, Deralakatte, Mangalore, India.  
E-mail: [malinig87@gmail.com](mailto:malinig87@gmail.com)

Received: 26 Nov 2016

Initial Review: 15 Dec 2016

Accepted: 30 Dec 2016

Published Online: 09 Jan 2017

### ABSTRACT

The uterus-like mass (ULM) is an anatomical entity first described in the ovary and thereafter, reported in several locations of the pelvis and abdominal cavity including broad ligament, greater omentum, cervix, small intestine, mesentery and conus medullaris. It is characterized by a miniature uterus comprising a smooth muscle wall lined by endometrium; thus, delineating a uterus-like anatomical structure. A 46-year-old lady presented with swelling in the abdomen. Imaging studies showed a thick walled cystic lesion in the pelvis and histopathology revealed a uterus like mass reminiscent of uterine morphology with its characteristic inner endometrium and outer smooth muscle. This entity is very uncommon with only few cases reported in literature. This case is being highlighted for its rarity and to discuss the possible theories for origin of this uncommon condition.

**Keywords:** Uterus-like mass, abdominal swelling, extrauterine.

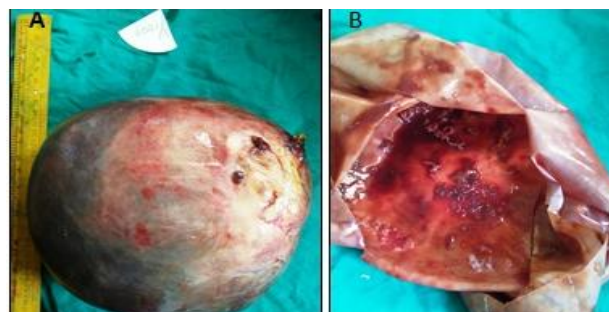**A** uterus-like mass is characterized by a central cavity lined by endometrium surrounded by a thick wall composed of smooth muscle, similar to the morphological structure of uterus [1]. The term 'uterus-like mass' was proposed by Cozzutto in 1981 [2]. The typical organoid arrangement of epithelium and muscle differentiates it from adenomyoma, an entity described to indicate random arrangement of glands and smooth muscle. Few cases of uterus-like mass involving ovary, fallopian tube, cervix, small bowel mesentery, obturator lymph node, colon and scrotum have been reported [3,4]. To the best of my knowledge, only six cases of the uterus-like mass of broad ligament have been published in the literature and this is the seventh case [1,3,5-8]. (Table 1)

### CASE REPORT

A 46 year old lady presented with swelling in abdomen since six months and pain abdomen since ten days. There was no significant family history of similar illness. The patient is a non-smoker, non-alcoholic with no history of diabetes, hypertension or tuberculosis. She is para 2 gravida 2, both her children were delivered normally and she had no previous history of any surgery or long-standing drug intake. The swelling was gradually increasing in size and the pain in abdomen was also gradual in onset, dull aching in character and diffusely present in the lower abdomen. There was no associated bleeding per vaginum, jaundice, urinary complaints or menstrual problems.

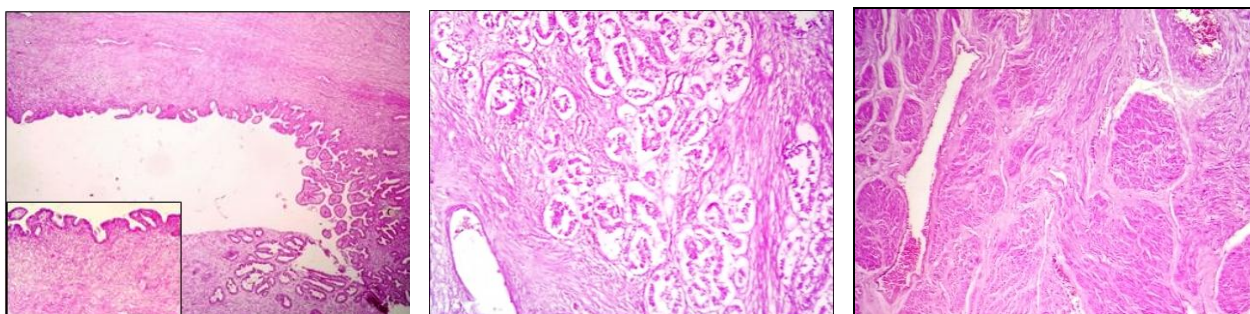
Clinical examination per abdomen revealed a palpable mass. The mass was present in the pelvic region and umbilical region, vaguely measuring 18 X 8 cm, firm in consistency and non tender to touch. Ultrasound abdomen revealed a thick walled cystic lesion in the pelvis extending about 7 cm above the level of pancreas. Fine internal echoes were noted. Small solid components were seen. There was no evidence of any calcification. Features were suggestive of complex ovarian cyst. Multidetector computed tomography (MDCT) abdomen revealed a large cystic lesion arising from the right adnexa with imperceptible thin septa within, suggestive of benign ovarian neoplasm possibly serous cystadenoma. Cancer antigen 125 (CA-125) levels were within normal limits (38 U/ml). Surgical excision of the mass was performed along with total abdominal hysterectomy and bilateral salpingoopherectomy. The mass was found to be separate from the ovary, arising from the broad ligament.

Gross examination revealed a large globular mass (**fig. 1**) measuring 20x8x7 cm and weighing 2.3 kg. External surface was grey yellow, smooth and glistening. On cut section, the mass was entirely cystic, uniloculated and filled with two litres of haemorrhagic reddish brown fluid. Some areas of the cyst wall were thickened and grey white firm in consistency. The internal surface of the cyst showed reddish brown friable blood clots. The uterus and cervix with bilateral adnexa were unremarkable.



**Figure 1 A:** A large globular mass measuring 20 x 8x7 cm and weighing 2.3 kg. External surface was grey-yellow, smooth and glistening. **B:** On cut section, the mass was entirely cystic, uniloculated. Some areas of cyst wall were thickened, grey-white and firm in consistency. Internal surface of cyst showed reddish brown friable blood clots.

Microscopic examination (**fig. 2, 3**) revealed a cystic mass with the cyst wall lined by cuboidal to columnar epithelium with papillary out foldings reminiscent of endometrial lining epithelium. Underlying stroma exhibited numerous glandular elements exhibiting ciliary metaplasia. The intervening stroma was fibromuscular with periphery showing thick bundles of smooth muscle resembling myometrium. Areas of haemorrhage and fibrinous material were seen in the cavity. Foci of pigment laden macrophages were noted in the stroma. No nuclear atypia or mitotic activity was seen.



**Figure 2:** Microscopic examination revealed a cystic mass with the cyst wall lined by cuboidal to columnar epithelium with papillary outfoldings reminiscent of endometrial lining epithelium, H&E,100X, (Inset - H&E, 400X). **Figure 3:** Underlying stroma exhibited numerous glandular elements, H&E, 400X. **Figure 4:** Periphery of the lesion exhibited thick bundles of smooth muscle resembling myometrium, H&E, 100X

## DISCUSSION

Uterus-like masses should be segregated from adenomyomas, which lack a uterus-like organization. The lesions described as extrauterine adenomyomas, unlike uterus-like mass; are composed of smooth muscle with scattered foci of endometriosis without making a distinct

central cavity [3]. Also, they need to be differentiated from endometriosis with smooth muscle metaplasia; where the smooth muscle is only a minor component.

The most common clinical presentation of uterus-like mass is dysmenorrhoea. It is due to hormone responsive endometrial tissue within a cavity with an absence of

channel for outflow. Other cases may present with lower abdominal pain with or without bleeding per vaginum [3]. It is seldom presented as a palpable mass, as in our case. A review of earlier reported cases disclosed that all occurred in women aged 11 to 59 years (average age 35years) [9]. Mass sizes ranged from 2.5 to 16 cm with an average of 8 cm [9]. To the best of our knowledge, this is the second reported case with a uterus-like mass attaining a giant size, the other case being a giant uterus-like mass, arising from the posterior fundus, reported by Tijani et al [10]. In some cases, the mass is related with congenital malformations of

the internal genitalia and the urinary system, and sometimes it is associated with endometriosis, breast cancer, and ovarian endometrioid carcinoma [1]. Since it is a rare entity and not well described in the literature; a clinical diagnosis or a radiological diagnosis is difficult to achieve. The radiologist should contemplate this diagnosis if she or he detects a cystic structure that exhibits uterine zonal anatomy [11]. However, a histopathological examination which may be aided by immunohistochemistry is the definitive mode of diagnosis.

**Table 1: Summary of all the cases of broad ligament uterus-like mass reported in English literature till date**

Cases/author	Year of publication	Age	Clinical symptoms	Laterality	Size (in cm)
1(Ahmed et al)	1997	46	Abdominopelvic swelling	Right	-
2(Matsuzaki et al)	2000	29	Dysmenorrhoea and lower abdominal pain	Left	7.5 X 7.2
3(Liang et al)	2010	17	Dysmenorrhoea	Left	4.3 × 3.7
4(Takeda et al)	2011	39	Sudden onset lower abdominal pain	Left	3.8X3.7X3.5
5(Nechi et al)	2013	54	Pelvic pain	Left	9.3x6.3
6(Rathod et al)	2016	45	Pain in left lower abdomen	Left	7X7X6.5
7(present case)	2016	46	Pain and swelling in abdomen	Right	20x8x7

On gross examination, any well-defined mass in the pelvic cavity with a solid-cystic or a cystic appearance and central areas of hemorrhage in a female patient should arouse suspicion of uterus-like mass. Histopathological detection of endometrial glands and smooth muscles arranged in organoid pattern helps in considering a diagnosis of uterus-like mass. Immunohistochemistry markers for smooth muscle-SMA, desmin, and ER, PR for the endometrial component can be helpful in aiding in diagnosis [7]. In our case; however, the presence of well-defined smooth muscle as well as endometrial glands obviated the need of immunohistochemistry to obtain a diagnosis.

The histogenesis of uterus-like masses remains ambiguous; however, four theories have been suggested: i) Metaplastic/ sub-coelomic mesenchyme transformation theory ii) Mullerian duct fusion defect theory iii) Theory of heterotopia and iv) Theory of mulleriosis [3]. The metaplasia hypothesis attributes the histogenesis of the uterus-like mass to endometriosis with consequent smooth muscle metaplasia or to endometrial metaplasia ensuing directly from the sub-coelomic mesenchyme transformation [12]. Cozzutto, who first described this entity proposed that the lesion may have originated from ovarian stromal cells that underwent transformation to smooth muscle cells via myofibroblasts [2].

The sub-coelomic mesenchyme is a layer of tissue that lies beneath the mesothelial surface of the peritoneum. In embryonic life, it gives rise to mesenchyme of urogenital ridge that envelope the early Mullerian and Wolffian ducts. In adults, it is signified by a layer of flattened cells that merge into the subserosal stroma of the uterus, ovaries, tubes, and uterine ligaments. The cells of sub-coelomic mesenchyme, also known as secondary Mullerian system, are believed to be pluripotent and may multiply in response to hormonal stimulation. These cells may be converted into the uterine tissue by differentiating into endometrial stromal cells, decidual, or smooth muscle cells under hormonal influences. This is known as sub-coelomic mesenchyme transformation theory [11,13]. This theory was supported by Ahmed et al, who suggested that these lesions may develop from mesenchymal cells that retain the ability to produce Mullerian duct structures [5].

The root of Mullerian duct fusion defect theory is developmental abnormality occurring during formation of female genital tract. Rosai proposed that the mass was uterus-like since it was connected to the uterus and thought that it was a result of a Mullerian duct fusion defect, precisely a rudimentary detached horn associated with a unicornuate uterus. Others authors have also favored the theory that these masses may be the consequence of congenital malformations due to either a flaw in the fusion

of the Mullerian ducts or a true partial duplication of the Mullerian system, supporting the finding that congenital abnormalities of the renal system have been associated with some of these cases [11].

Peterson et al, who reported a 12-year-old female patient with an ileal uterus-like mass, as well as multiple lower-intestinal and urogenital tract anomalies and a past history of sacrococcygeal teratoma favoured a theory of heterotopia, meaning the presence of a particular tissue type at a non-physiological site, but usually co-existing with original tissue in its correct anatomical location. They emphasized that neither the metaplastic nor malformation theories were completely satisfactory [11]. Batthas suggested the theory of mullerianosis-developmentally misplaced mullerian tissue for this parauterine uterus like mass. Suspected mullerianchoristomas with only one mullerian tissue like this mass can be diagnosed only when three criteria are met; no evidence of pelvic endometriosis, no direct communication with endocervix, endometrium or endosalpinx and no history of surgery on reproductive organs [15]. Surgical excision is the treatment of choice to avoid complications like torsion or rupture.

## CONCLUSION

The present case is a rare entity which should be considered in the differential diagnosis of pelvic mass in female patients. It supports the metaplastic/subcoelomic mesenchymal theory of origin of uterus like mass. The patient was a 46 year old premenopausal lady without any prior history of surgery or structural uterine abnormality consistent with neither a mullerian fusion defect nor any congenital malformation or renal abnormalities. The mass was connected to the uterus, not ruling out a direct communication to endosalpinx or endometrium.

Therefore, in conclusion, I consider that the metaplastic theory best fits with my observations in the present case as both glandular and stromal smooth muscle cells may proliferate from subcoelomic mesenchyme under the influence of hormonal stimulation.

## REFERENCES

1. Liang YJ, Hao Q, Wu YZ, Wu B. Uterus-like mass in the left broad ligament misdiagnosed as a malformation of the uterus: A case report of a rare condition and review of the literature. *Fertil Steril*. 2010;94:1347.

2. Cozzutto C. Uterus-like mass replacing ovary. Report of a new entity. *Arch Pathol Lab Med*. 1981; 105:508- 11.
3. Rathod AE, Ambawade VD, Pawar AS. Uterus-like mass of broad ligament presenting as palpable mass – A rare case report. *Int J Science Research*. 2016; 5(10): 673-6.
4. Khurana A, Mehta A, Sardana M. Extrauterine adenomyoma with a uterus like features: A rare entity presenting 17 years post hysterectomy. *Indian J Pathol Microbiol*. 2011;54:572-3.
5. Ahmed AA, Swan RW, Owen A, Kraus FT, Patric F. Uterus-like mass arising in the broad ligament: a metaplasia or Mullerian duct anomaly? *Int J Gynecol Pathol*. 1997; 16:279-81.
6. Takeda A, Imoto S, Mori M, Yamada J, Nakamura H. Uterus-like mass of ovarian ligament: Image diagnosis and management by laparoendoscopic single-site surgery. *J Obstet Gynaecol Research*. 2011;37(12):1895-9.
7. Matsuzaki S, Murakami T, Sato S, Moriya, T, Sasano H, Yajima A. Endometriosis arising in the uterosacral ligament: A case report including a literature review and immunohistochemical analysis. *Pathol Int*. 2000;50:493-6.
8. Nechi S, Znaidi N, Rammah S, M' Farej MK, Zermani R. Uterus-like mass of the broad ligament. *Int J Gynecol Obstet*. 2013; 123(3): 249-50.
9. Kim MJ, Seok SH. Uterus-Like Mass with Features of an Extrauterine Adenomyoma: A Case Report and Literature Review. *Korean J Pathol*. 2007; 41: 347-51.
10. Tijani EH, Meryem T, Lamy GA, Abdelouahed J. Giant uterus-like mass of the uterus. *Indian J Pathol Microbiol*. 2010;53:793-5.
11. Menn KA, Qin L, Fedoriw GD, Gillette ME, McCarthy S. Uterus-like mass: M0 RI appearance of a very rare entity. *J Magn Reson Imaging*. 2007;26:162-4.
12. Gurel D, Tuna B, Yörükoğlu K. Uterus-like mass of the ovary. *Turk J Pathol*. 2007; 23(2):103-06.
13. Lauchlan SC. The secondary Mullerian system. *Obstet Gynecol Surv*. 1972; 27: 133-46.
14. Redman R, Wilkinson EJ, Massoll NA. Uterine-like mass with features of an extrauterine adenomyoma presenting 22 years after total abdominal hysterectomy–bilateral salpingo-oophorectomy: a case report and review of the literature. *Arch Pathol Lab Med*. 2005;129:1041-3.
15. Batt RE. Pathogenesis of a parauterine uterus-like mass: developmentally misplaced müllerian tissue müllerianosis [letter]. *Fertil Steril*. 2010;94(2).

**How to cite this article:** Goswami M. A rare case of giant uterus like mass arising from broad ligament: a case report with review of histogenesis. *Indian J Case Reports*. 2017; 3(1): 30-33.

*Conflict of interest: None stated, Funding: Nil*