

## Euglycemic diabetic ketoacidosis induced by dapagliflozin in the perioperative period – A case report

M Shamshuzoha<sup>1</sup>, Priyanka Chavan<sup>1</sup>, Jeshwin Thamburaj<sup>2</sup>

From <sup>1</sup>Consultant, <sup>2</sup>Resident, Department of Critical Care Medicine, Bangalore Baptist Hospital, Bengaluru, Karnataka, India

### ABSTRACT

Dapagliflozin is a sodium-glucose co-transporter 2 (SGLT2) inhibitor used in the treatment of type 2 diabetes mellitus. SGLT2 inhibitors are known to cause diabetic ketoacidosis (DKA) with normal to mild increases in blood glucose levels. Euglycemic DKA develops in patients with pre-existing risk factors such as major surgery, missed insulin dosage, dehydration, and other acute medical illnesses. We describe a 54-year-old female diabetic patient who developed severe DKA in the post-operative period with normal blood glucose levels presenting as acute abdomen. She was successfully managed with DKA protocol and was discharged from the hospital.

**Key words:** Dapagliflozin, Diabetes mellitus, Diabetic ketoacidosis, Sodium-glucose co-transporter 2 inhibitor

Diabetic ketoacidosis (DKA) is a serious complication of diabetes that can be life threatening. DKA is characterized by the triad of hyperglycemia, anion gap metabolic acidosis, and ketonemia. The diagnostic criteria proposed by the American Diabetes Association include blood glucose levels >250 mg/dL, arterial pH <7.3, anion gap >10 mEq/L, HCO<sub>3</sub> <15 mEq/L, and the presence of ketones in blood and urine [1]. In diabetic patients, ketoacidosis can occur with just mild-to-moderate glucose elevation, which is referred to as euglycemic DKA (euDKA). In 1973, Munro *et al.* first described euDKA and reported a cohort of 211 patients with DKA, 37 of whom had a glucose concentration at the presentation of <16.7 mmol/L (300 mg/dL) [2].

Dapagliflozin is a sodium-glucose co-transporter 2 (SGLT2) inhibitor. SGLT2 inhibitors are novel drugs for the treatment of patients with diabetes with cardioprotective and renoprotective profiles [3]. In 2015, the US Food and Drug Administration (FDA) warned of an elevated risk of DKA with unexpectedly mild-to-moderate glucose rise (euDKA) in patients using these agents [4]. The incidence of DKA in patients treated with SGLT2 inhibitors ranged between 0.1% and 0.6% [5,6].

In the literature, there are several case reports of DKA caused by SGLT2 inhibitors but we report a case of severe euDKA in a patient with type 2 diabetes mellitus (DM) on dapagliflozin presenting in the post-operative period as acute abdomen.

### CASE REPORT

A 54-year-old female with type 2 DM for 10 years on oral hypoglycemic agents (dapagliflozin 10 mg once daily, vildagliptin 50 mg bid, and metformin 500 mg bid) presented to the gynecology outpatient department with a history of pain in the abdomen, nausea, and bleeding per vagina for 7 days.


Her systemic examination was normal. Routine blood investigations were within normal limits except for HbA1C - 9.9 which showed poorly controlled type 2 DM.

On evaluation, ultrasound abdomen and pelvis showed (Fig. 1) intramural fibroid (anterior) measuring about 1.7 × 1.6 cm with thickened endometrium. She was posted for elective total abdominal hysterectomy and bilateral salpingo-oophorectomy. Her regular oral hypoglycemic agents (OHAs) were continued the day before surgery, and she was kept nil per oral overnight. She underwent surgery under uneventful spinal anesthesia. On postoperative day 1, the patient had breathing difficulty, tachypnea, tachycardia, and severe abdominal pain. Arterial blood gas analysis (ABG) was done which showed severe metabolic acidosis, hence she was shifted to the intensive care unit (ICU) for further management (Table 1).

On clinical examination, the patient appeared dehydrated. She was afebrile, her blood pressure was 130/80 mmHg, and her heart rate was 120 beats/min. She was also tachypneic with a respiratory rate of 30 breaths/min and oxygenation was normal with SpO<sub>2</sub> of 97% on room air. Her abdominal examination revealed a clean surgical wound and diffuse tenderness. Other systemic

**Correspondence to:** Dr. M Shamshuzoha, Department of Critical Care Medicine, Bangalore Baptist Hospital, Hebbal, Bengaluru - 560 024, Karnataka, India. E-mail: shamshuzoha@gmail.com

© 2024 Creative Commons Attribution-NonCommercial 4.0 International License (CC BY-NC-ND 4.0).

Access this article online	
Received - 16 March 2024 Initial Review - 26 March 2024 Accepted - 15 May 2024	Quick Response code 
DOI: 10.32677/ijcr.v10i7.4536	

examinations were normal. Her initial laboratory investigations revealed leukocytosis 29,000/cumm with neutrophilia (94%) and serum sodium was 134 mmol/L with mild hyperkalemia 5.1 mmol/L. Her urine routine was positive for ketones and glycosuria. Her chest X-ray was normal. ABG showed severe metabolic acidosis and elevated blood ketones. Serum lactate and renal function tests were within normal limits. A diagnosis of SGLT-2 inhibitor-associated euDKA was made after ruling out other causes of high anion gap metabolic acidosis.

She was started on insulin infusion and intravenous fluids according to hospital DKA protocol. Blood and urine culture was sent and she was started on empirical antibiotic. In view of severe metabolic acidosis with a pH of 6.9, she was given 100 meq of sodium bicarbonate over 1 h. Serial ABG monitoring and blood ketones were done and insulin infusion was continued till the normalization of anion gap and serum bicarbonate. She had hypokalemia and was given potassium correction. She was started orally on post-operative day 2 after clearance from the surgical team. On day 4 of ICU admission, her insulin infusion was stopped and was bridged with sliding-scale insulin. Toward the end of her ICU stay, she had mild normal anion gap metabolic acidosis due to hyperchloremia (115 mmol/L) as a consequence of fluid resuscitation. She was shifted to the ward on day 5 of ICU admission, and before discharge, she was started on OHAs (metformin 500 mg BiD and vildagliptin 50 mg BiD) except dapagliflozin.

## DISCUSSION

SGLT-2 proteins are expressed in the kidney's proximal convoluted tubules and perform a physiological role by reabsorbing filtered glucose from the tubular lumen. SGLT-2 inhibitors limit filtered glucose reabsorption, lower the renal threshold for glucose, and increase urinary glucose excretion [7]. These inhibitors are oral hypoglycemic medicines that improve insulin sensitivity by reducing visceral and subcutaneous fat, cardiovascular mortality, and hypoglycemic episodes [8]. Dapagliflozin is one of the SGLT-2 inhibitors that were FDA approved in January 2014. It is recommended for adult patients with type 2 diabetes to improve blood glucose control [7]. Other indications include type 2 DM patients with underlying cardiovascular risk factors and CKD patients to minimize the risk of decline in estimated glomerular filtration rate [7].

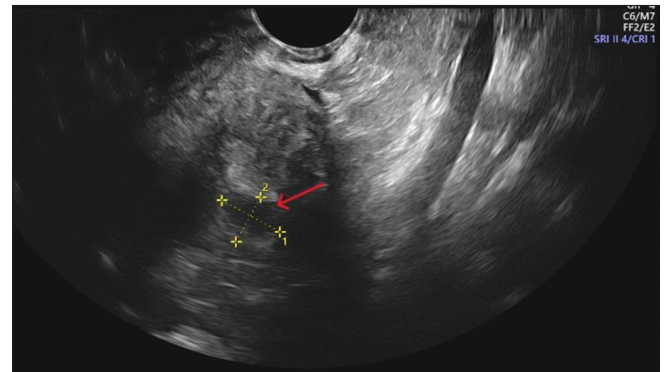
euDKA is defined as ketoacidosis (pH 7.3 or serum bicarbonate 18 mmol/L) with normal plasma glucose levels or mild hyperglycemia (11–14 mmol/L) [9]. SGLT2 inhibitors cause euDKA through glucosuria, resulting in lower plasma glucose levels and reduced insulin secretion. Carbohydrate deficit and hypovolemia stimulate the production of glucagon, which increases the ratio of glucagon to insulin and initiates ketogenesis with euglycemia. SGLT-2 inhibitors also directly act on pancreatic alpha cells, releasing glucagon and preventing the excretion of ketone bodies by the kidneys [9].

The incidence of DKA related to dapagliflozin has been reported to be <0.1% [10]. The precipitating factors for SGLT2

**Table 1: Serial arterial blood gas analysis and laboratory parameters**

ABG	POD1	POD2	POD3	POD4	POD5
PH	6.9	7.29	7.43	7.47	7.45
PCO <sub>2</sub>	8.3	15	21	23	30
PO <sub>2</sub>	119	104	81	83	80
HCO <sub>3</sub>	1.8	7.2	13.9	16.7	20.1
Anion gap	36	29	23	19	10
K	5.1	3.5	3.4	3.3	4
Na	134	140	139	139	136
Serum ketone	6	4.5	1.5	1	0.9
Serum lactates	1	1	0.7	0.6	0.7
General random blood sugar	203	220	171	186	156

ABG: Arterial blood gas



**Figure 1: Transvaginal ultrasound showing intramural fibroid**

inhibitors associated with DKA include latent autoimmune diabetes in adults, major surgeries, missed or discontinued insulin administration, inappropriate reduction of insulin dosage, acute medical illness, low-carbohydrate diet, acute pancreatitis, and dehydration [11]. Common clinical presentations include abdominal pain, nausea, and vomiting; non-specific symptoms such as tachycardia, general weakness, and impaired consciousness are also noted in some patients [11]. The stress of surgery, fasting, and continuation of OHAs before the day of surgery may have precipitated DKA in our patient. Our patient presented with typical symptoms of vomiting, abdominal pain, and tachypnea.

There have been cases of euDKA in post-operative patients taking SGLT-2 inhibitors. Lau *et al.* reported three cases of euDKA in type 2 DM patients taking empagliflozin and having elective coronary artery bypass grafting surgery [12]. Luo *et al.* reported a case of euDKA in a 57-year-old diabetic patient who had undergone surgery for pancreatic carcinoma [13]. Wang and Isom reported euDKA in a post-operative patient who had undergone cerebral revascularization for moyamoya disease. This patient had developed DKA despite stopping empagliflozin during the perioperative period [14]. In almost all the case reports, there were delays in the initial diagnosis of DKA due to near-normal blood glucose levels.

When eu-DKA is suspected, it is necessary to rule out other causes of high anion gap metabolic acidosis. Starvation ketosis

was one of the differentials that could have been possible but our patient has only a brief period of fasting (8 h) and severe acidosis with bicarbonate of 1.8 mmol is very unlikely. Our patient had normal renal parameters and other causes of high anion gap metabolic acidosis were ruled out. Treatment for eu-DKA caused by SGLT-2 inhibitors is similar to standard DKA management along with prompt discontinuation of SGLT-2 inhibitors. Resuscitation with crystalloids, insulin administration, and correction of electrolyte disturbances until normalization of the anion gap is the standard treatment recommended [1].

## CONCLUSION

SGLT-2 inhibitors are known to cause euDKA. The presence of risk factors should raise the suspicion of ketoacidosis in patients with unexplained acidosis in the setting of normal blood glucose levels. Stopping SGLT-2 inhibitors before major surgery, early recognition of ketoacidosis, and management with fluids and insulin will improve the patient's outcome.

## REFERENCES

1. Kitabchi AE, Umpierrez GE, Miles JM, Fisher JN. Hyperglycemic crises in adult patients with diabetes. *Diabetes Care* 2009;32:1335-43.
2. Munro JF, Campbell IW, McCuish AC, Duncan LJ. Euglycaemic diabetic ketoacidosis. *Br Med J* 1973;2:578-80.
3. Sarafidis P, Ferro CJ, Morales E, Ortiz A, Malyszko J, Hojs R, *et al.* SGLT-2 inhibitors and GLP-1 receptor agonists for nephroprotection and cardioprotection in patients with diabetes mellitus and chronic kidney disease. A consensus statement by the EURECA-m and the DIABESITY working groups of the ERA-EDTA. *Nephrol Dial Transplant* 2019;34:208-30.
4. FDA Drug Safety Communication. FDA Warns that SGLT2 Inhibitors for Diabetes May Result in a Serious Condition of Too Much Acid in the Blood; 2015. Available from: <https://www.fda.gov/drugs/drugsafety/ucm446845.htm> [Last accessed on 2019 Jul 20].
5. Zinman B, Wanner C, Lachin JM, Fitchett D, Bluhmki E, Hantel S, *et al.* Empagliflozin, cardiovascular outcomes, and mortality in type 2 diabetes. *N Engl J Med* 2015;373:2117-28.
6. Neal B, Perkovic V, Mahaffey KW. Canagliflozin and cardiovascular and renal events in type 2 diabetes. *N Engl J Med* 2017;377:644-57.
7. Padda IS, Mahtani AU, Parmar M. Sodium-glucose Transport Protein 2 (SGLT2) Inhibitors. In: StatPearls. Treasure Island, FL: StatPearls Publishing; 2024. Available from: <https://www.ncbi.nlm.nih.gov/books/NBK576405> [Last accessed on 2023 Jun 03].
8. Andrianesis V, Glykofridi S, Doupis J. The renal effects of SGLT2 inhibitors and a mini-review of the literature. *Ther Adv Endocrinol Metab* 2016;7:212-28.
9. Nasa P, Chaudhary S, Shrivastava PK, Singh A. Euglycemic diabetic ketoacidosis: A missed diagnosis. *World J Diabetes* 2021;12:514-23.
10. Jabbour S, Seufert J, Scheen A, Bailey CJ, Karup C, Langkilde AM. Dapagliflozin in patients with type 2 diabetes mellitus: A pooled analysis of safety data from phase IIb/III clinical trials. *Diabetes Obes Metab* 2018;20:620-8.
11. Burke KR, Schumacher CA, Harpe SE. SGLT2 inhibitors: A systemic review of diabetic ketoacidosis and related risk factors in the primary literature. *Pharmacotherapy* 2017;37:187-94.
12. Lau A, Bruce S, Wang E, Ree R, Rondi K, Chau A. Perioperative implications of sodium-glucose cotransporter-2 inhibitors: A case series of euglycemic diabetic ketoacidosis in three patients after cardiac surgery. *Can J Anaesth* 2018;65:188-93.
13. Luo X, Ji R, Lu W, Zhu H, Li L, Hu J. Dapagliflozin-associated euglycemic diabetic ketoacidosis in a patient who underwent surgery for pancreatic carcinoma: A case report. *Front Surg* 2022;9:769041.
14. Wang KM, Isom RT. SGLT2 inhibitor-induced euglycemic diabetic ketoacidosis: A case report. *Kidney Med* 2020;2:218-21.

*Funding: Nil; Conflicts of interest: Nil.*

**How to cite this article:** Shamshuzoha M, Chavan P, Thamburaj J. Euglycemic diabetic ketoacidosis induced by dapagliflozin in the perioperative period – A case report. *Indian J Case Reports*. 2024;10(7):194-196.